**PATIENT**

Zayda Carrasco

SPECIES

Canine

BREED

Lab Mix

SEX

FS

AGE

5 year

WEIGHT

59.3 lbs.

INTERPRETED BYR. McKenzie Daniel,
DVM, DABVP (Canine
and Feline)**IMAGING
PERFORMED BY**

Rachel Runnells, RVT

HOSPITAL NAME

SVS Imaging KC

REFERRING VET

Dr. Jennifer Kissinger

INVOICE

13800

DATE

5/4/22

PRESENTING CLINICAL SIGNS

Chronic UTI, hematuria. Also has a hooded vulva.

Abnormal PE/Chem/CBC/UA Results: No evidence of radiopaque stones.

ULTRASONOGRAPHIC EXAMINATION OF THE ABDOMEN**Urinary System**

The urinary bladder, trigone, cystourethral junction, and visible pelvic urethra to a depth of 5.0 cm exhibited normal thickness and tone. Anechoic urine was present in the lumen with no uroliths, sediment, or calculi. The ureteral papillae were normal. The ureters were not visible which is normal. No evidence of inflammatory or neoplastic urinary bladder criteria was noted.

The area of the aortic trifurcation was free of pathology.

Normal size and margination were present in the kidneys. A normal 1:3 cortex / medulla ratio and normal corticomedullary definition were maintained. The echogenicity of the cortex was similar to or slightly less than normal liver parenchyma while the medulla echogenicity was hypoechoic to the cortex with no evidence of pelvic dilation. The left kidney measured 6.4 cm in length. The right kidney measured 6.6 cm in length.

Adrenal Glands

The left adrenal gland was uniform in size and contour with a uniformly hypoechoic parenchyma. The left adrenal gland measured 0.57 cm width at the caudal pole and 0.54 cm width at the cranial pole. The right adrenal gland was uniform in size and contour with a uniformly hypoechoic parenchyma. The right adrenal gland measured 0.74 cm width at the caudal pole and 0.89 cm width at the cranial pole.

Spleen

The spleen exhibited a finely textured and homogenous parenchyma which was hyperechoic to the liver and renal cortical parenchyma. The capsule was smooth and regular without apparent expansion. The splenic vasculature at the hilus was normal in volume with no evidence of congestion or thrombosis. Acute to chronic inflammatory, neoplastic, or benign parenchyma changes were not noted.

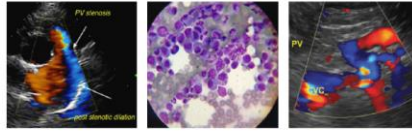
Liver/ Gallbladder

The liver was subjectively normal in size, structure, and contour. The liver parenchyma was uniform and hypoechoic to the spleen with a mild coarse echotexture. The hepatic and portal vasculature were normal in appearance without signs of congestion. The gallbladder was non-distended in size with thin walls and primarily anechoic luminal content. The cystic and common bile ducts were normal.

Gastrointestinal

The stomach presented intact wall layering with a normal wall layer ratio. The lumen of the stomach was empty with no signs of ileus, obstruction, or foreign material.

The small intestine presented intact wall layering with 1:3 muscularis/mucosa ratio. The lumen of the small intestine was empty with no signs of ileus, obstruction, or foreign material.



PATIENT

Normal visible colon wall layers were present with apparent formed feces in lumen.

Zayda Carrasco

Pancreas

SPECIES

The parenchyma of the left limb, body, and right limb of the pancreas presented isoechoic to the adjacent omental fat. A normal curvilinear capsule contour of the pancreas was present. The visible pancreatic duct was normal. No signs of active inflammation or neoplastic disease were evident.

Canine

Free Abdomen

BREED

No overt lymphadenopathy or peritoneal effusion was present.

Lab Mix

ULTRASONOGRAPHIC FINDINGS

SEX

- Sonographically unremarkable urinary bladder and visible proximal urethra
- Sonographically unremarkable bilateral kidneys - no evidence of pyelonephritis

FS

INTERPRETATION OF THE FINDINGS & FURTHER RECOMMENDATIONS

AGE

Sonographically unremarkable abdomen without evidence of upper or lower urinary tract pathology i.e., cystitis, congenital abnormalities such as ectopic ureter, calculi, renal dysplasia, pyelonephritis, etc., as an obvious cause of recurrent urinary tract infection.

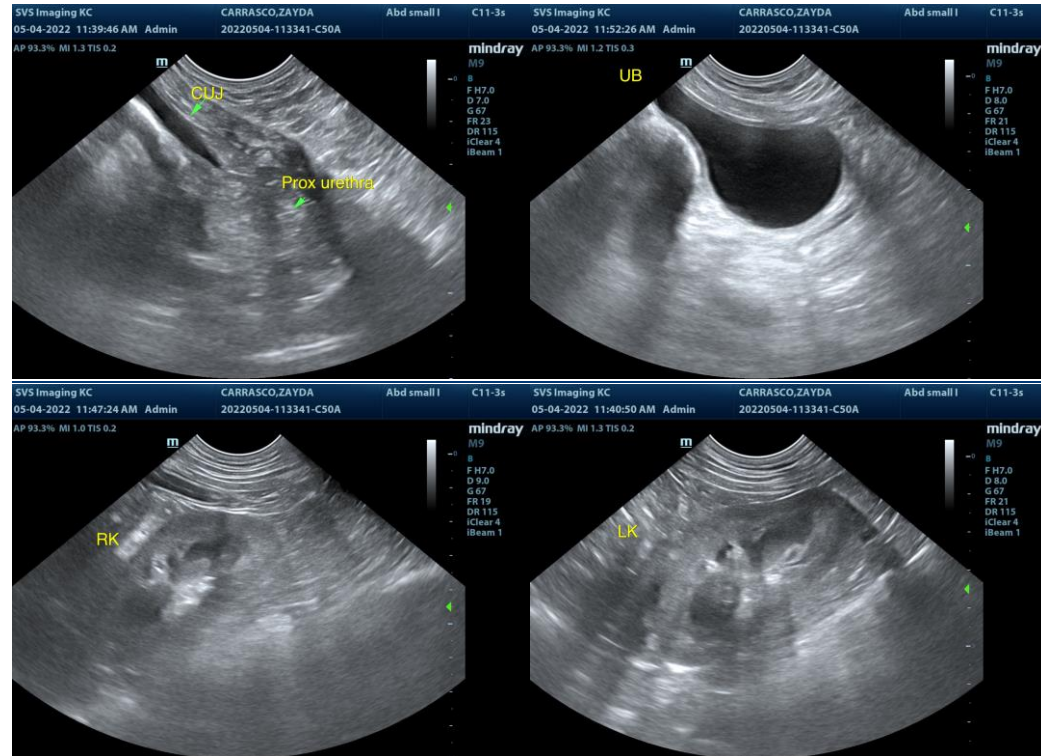
5 year

WEIGHT

59.3 lbs.

INTERPRETED BY

R. McKenzie Daniel, DVM, DABVP (Canine and Feline)



IMAGING PERFORMED BY

Rachel Runnells, RVT

HOSPITAL NAME

SVS Imaging KC

REFERRING VET

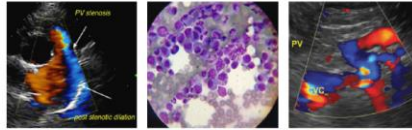
Dr. Jennifer Kissinger

INVOICE

13800

DATE

5/4/22



PATIENT

Zayda Carrasco

SPECIES

Canine

BREED

Lab Mix

SEX

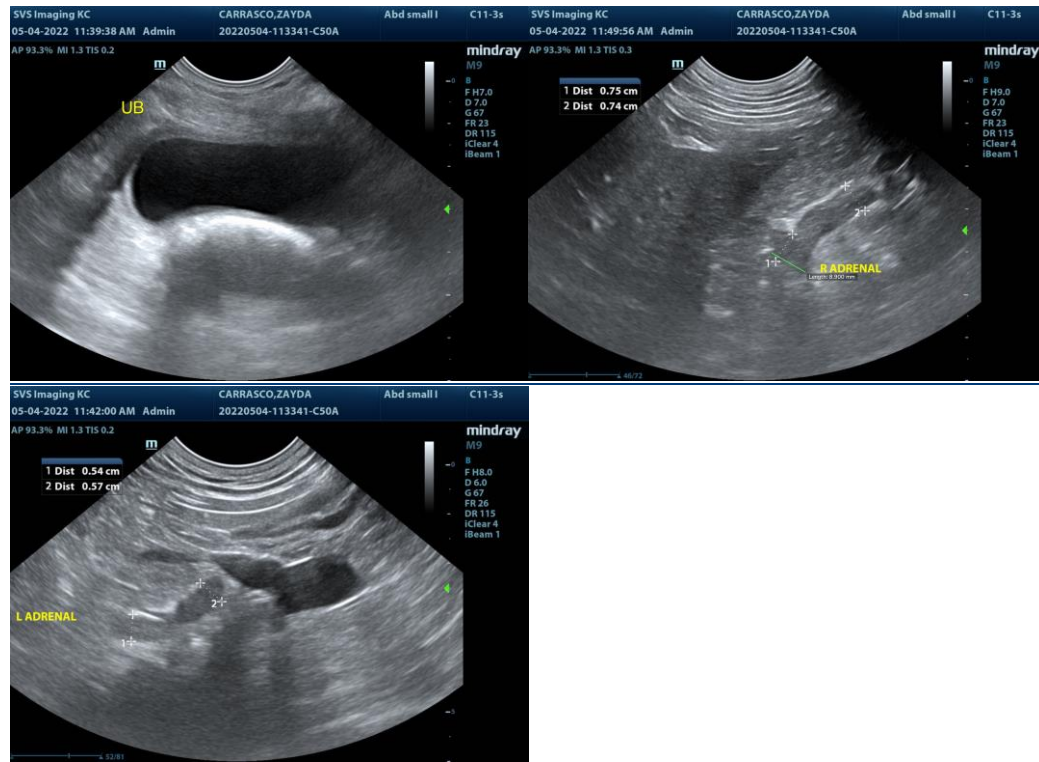
FS

AGE

5 year

WEIGHT

59.3 lbs.



INTERPRETED BY

R. McKenzie Daniel,
DVM, DABVP (Canine
and Feline)

**IMAGING
PERFORMED BY**

Rachel Runnells, RVT

HOSPITAL NAME

SVS Imaging KC

REFERRING VET

Dr. Jennifer Kissinger

INVOICE

13800

DATE

5/4/22

The information and recommendations provided are based on the images presented by the referring veterinarian/sonographer. No evaluation can be communicated regarding pathology that was not visible in the image/video clips provided.

Thank you for this referral. If the clinical or image interpretation does not parallel your findings or if I can be of any further assistance please contact me.

R. McKenzie Daniel, DVM, DABVP (Canine / Feline Practice)
info@SonoPath.com