

**PATIENT**

Tank Schmiedlin

SPECIES

Canine

BREEDAustralian Shepherd
Mix**SEX**

Neutered Male

AGE

12 Years

WEIGHT

17.2 kg

INTERPRETED BYR. McKenzie Daniel,
DVM, DABVP (Canine
and Feline)**IMAGING
PERFORMED BY**

Tom McNeill

HOSPITAL NAME

SVS Imaging QC

REFERRING VETDr. Marroquin-
Madison VS**INVOICE**

15028

DATE

5/3/22

PRESENTING CLINICAL SIGNS

History: Initially presented yesterday for abdominal pain and intermittent hyporexia for 2 weeks. Tank was discharged after receiving subcutaneous fluids, cerenia SQ, and gabapentin. He returned today for progressive abdominal pain.

Abnormal PE/Chem/CBC/UA Results: Mild fever, neutrophilia, and hyperglobulinemia suspect from anxiety/stress r/o infectious, inflammatory, neoplasia, other

ULTRASONOGRAPHIC EXAMINATION OF THE ABDOMEN**Urinary System**

The urinary bladder, trigone, cystourethral junction, and visible pelvic urethra to a depth of 4.0 cm exhibited normal thickness and tone. Primarily anechoic urine was present in the lumen with no uroliths or sediment. The ureteral papillae were normal. The ureters were not visible which is normal. No evidence of inflammatory or neoplastic changes were noted.

The residual prostate was symmetrically normal in size with uniform parenchyma and slight coarse echotexture measuring 0.79 cm in diameter.

Normal size and margination were present in the kidneys. A normal 1:3 cortex / medulla ratio and normal corticomedullary definition were maintained. The echogenicity of the cortex was similar to or slightly less than normal liver parenchyma while the medulla echogenicity was hypoechoic to the cortex with no evidence of pelvic dilation. The left kidney measured 5.5 cm in length. The right kidney measured 6.0 cm in length.

Adrenal Glands

The left adrenal gland was uniform in size and contour with a uniformly hypoechoic parenchyma. The left adrenal gland measured 0.68 cm width at the caudal pole and 0.64 cm width at the cranial pole.

The right adrenal gland was uniform in size and contour with a uniformly hypoechoic parenchyma. The right adrenal gland measured 0.45 cm width at the caudal pole and 0.34 cm width at the cranial pole.

Spleen

A primarily spherical solid mass involving the spleen was present. The parenchyma of the mass was nonhomogeneous, subjectively in the caudal spleen with associated splenic folding without areas of cavitation. The non-affected splenic parenchyma exhibited maintained finely textured and homogenous echotexture. The splenic vasculature at the hilus was normal in volume with no evidence of congestion or thrombosis.

Liver

The liver was subjectively normal in size, structure, and contour. The liver parenchyma was mildly nonuniform and hypoechoic to the spleen with a moderate coarse echotexture and subjective mild to benign parenchymal remodeling. The hepatic and portal vasculature were normal in appearance without signs of congestion.

The gallbladder was nondistended. The gallbladder walls were non-thickened yet mildly echogenic. Primarily anechoic content with mild luminal debris was present. No overt evidence of peripheral gallbladder inflammation noted. The cystic and common bile ducts were normal.

**PATIENT**

Tank Schmiedlin

SPECIES

Canine

BREEDAustralian Shepherd
Mix**SEX**

Neutered Male

AGE

12 Years

WEIGHT

17.2 kg

INTERPRETED BYR. McKenzie Daniel,
DVM, DABVP (Canine
and Feline)**IMAGING
PERFORMED BY**

Tom McNeill

HOSPITAL NAME

SVS Imaging QC

REFERRING VETDr. Marroquin-
Madison VS**INVOICE**

15028

DATE

5/3/22

Gastrointestinal

The stomach presented intact wall layering with a normal wall layer ratio. The lumen of the stomach was empty with no signs of ileus, obstruction or foreign material.

The small intestine presented intact wall layering with 1:3 muscularis/mucosa ratio. The lumen of the small intestine was empty with no signs of ileus, obstruction or foreign material. The jejunum wall measured 0.40 cm. The duodenum wall measured 0.40 cm.

Normal visible colon wall layers were present with apparent formed feces in lumen.

Pancreas

The parenchyma of the left limb, body and right limb of the pancreas presented isoechoic to the adjacent omental fat. A normal curvilinear capsule contour of the pancreas was present. The visible pancreatic duct was normal. No signs of active inflammation or neoplastic disease was evident.

Free Abdomen

Several enlarged medial iliac lymph nodes were present. These lymph nodes were homogenous, mildly hypoechoic and smoothly marginated. A normal width: length ratio was maintained (<0.5). Evidence of perilymphatic inflammation was evident. An example of lymph node size was 1.9 cm x 0.62 cm.

The omentum was of uniform echogenicity, including no evidence of perisplenic omental reactivity. No evidence of peritoneal effusion secondary to splenic mass rupture.

Other

A rapid view of the heart exhibited unclear window to the heart without overt evidence of pericardial effusion.

ULTRASONOGRAPHIC FINDINGS

- Nonhomogeneous, non-cavitated splenic mass
- Nonspecific yet subjectively benign/reactive mild medial iliac lymphadenopathy
- Minor hepatic parenchymal remodeling
- Mild gallbladder debris, potential minor cholecystitis
- Sonographically unremarkable gastrointestinal tract/pancreas
- Minor age-related kidneys

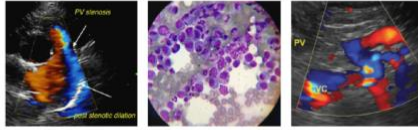
INTERPRETATION OF THE FINDINGS & FURTHER RECOMMENDATIONS

The primary finding of the splenic mass was nonspecific with potential for multiple etiologies, including hyperplasia, hematopoiesis, hematoma, infection, granuloma or neoplasia (sarcoma, round cell neoplasia or other). Potential for non-splenic origin of the mass with impingement upon the folded spleen is considered a less likely differential diagnosis. No overt evidence of regional omental or major organ metastasis.

Aside from the splenic mass, no overt evidence of significant abdominal visceral pathology as an obvious cause of the patient abdominal pain. Assuming no evidence of thoracic pathology on three-view chest radiographs, laparotomy with expectation towards splenectomy and gross inspection of the liver and gallbladder with the possibility of manual gallbladder expression, if grossly indicated, could be considered. Assessment for potential referred abdominal or musculoskeletal pain, if not already done, could be considered.

IMAGING PERFORMED BY

SVS Mobile Imaging CT 262-366-5970
fredgromalak@gmail.com



Clinical Sonography & Telecytology

EDUCATIONAL TELECONSULTATION SERVICES™

1-800-838-4268 info@sonopath.com SonoPath.com

PATIENT

Tank Schmiedlin

SPECIES

Canine

BREED

Australian Shepherd
Mix

SEX

Neutered Male

AGE

12 Years

WEIGHT

17.2 kg

INTERPRETED BY

R. McKenzie Daniel,
DVM, DABVP (Canine
and Feline)

**IMAGING
PERFORMED BY**

Tom McNeill

HOSPITAL NAME

SVS Imaging QC

REFERRING VET

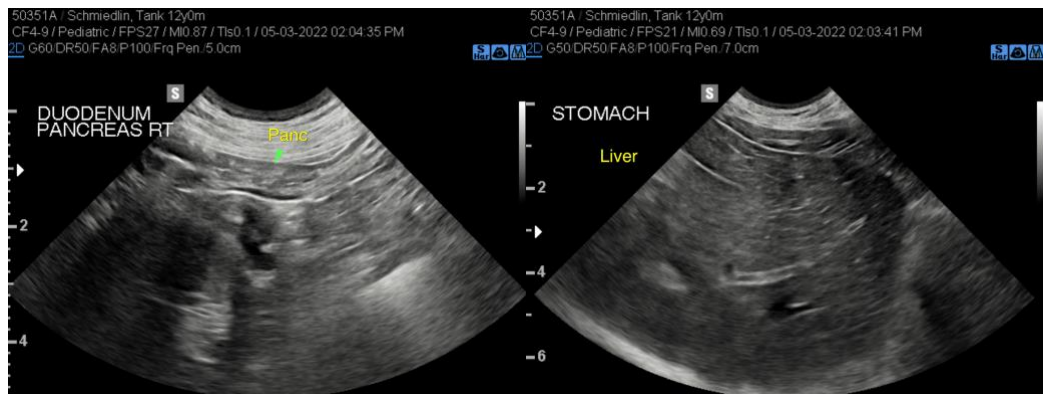
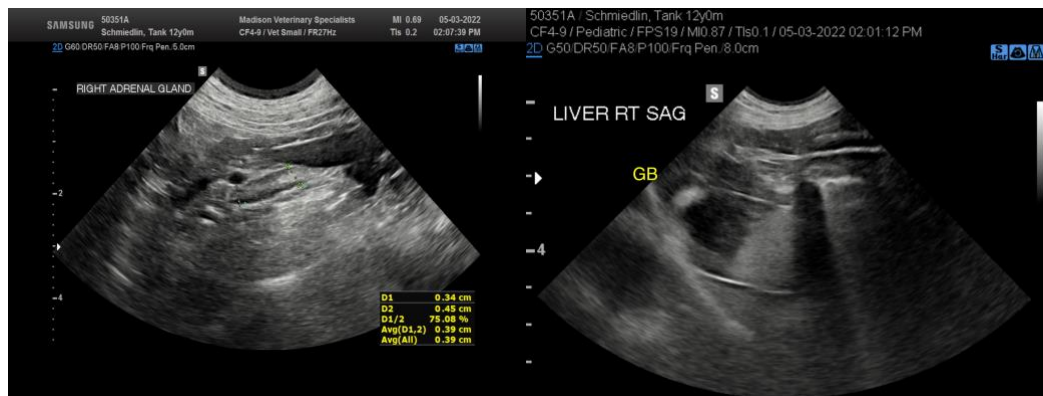
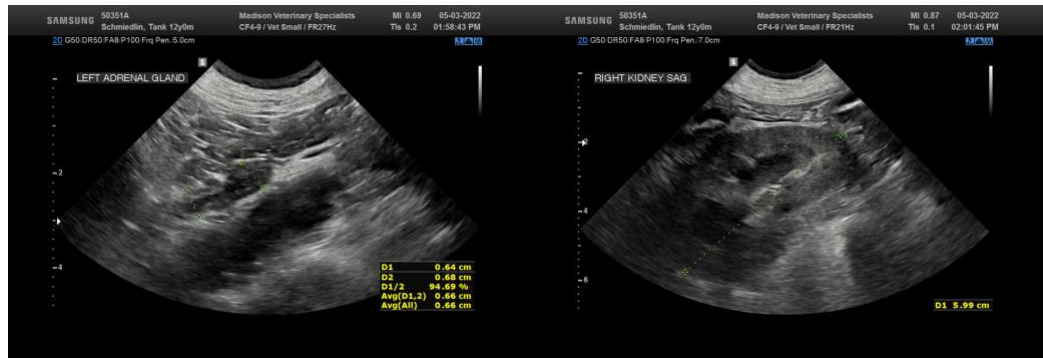
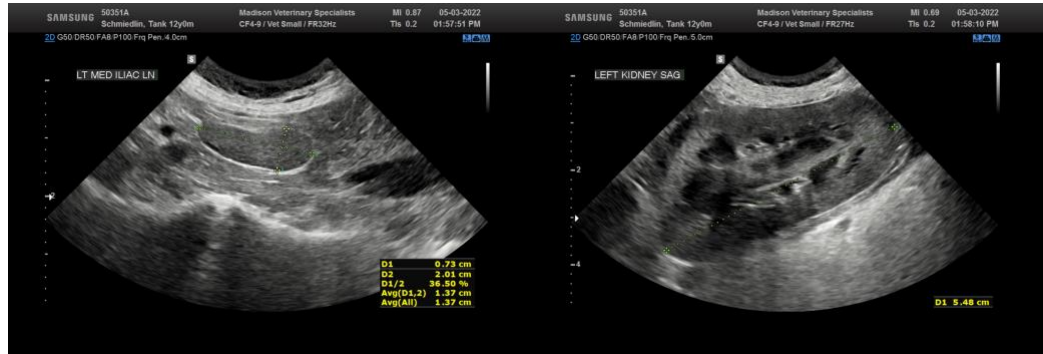
Dr. Marroquin-
Madison VS

INVOICE

15028

DATE

5/3/22



IMAGING PERFORMED BY

SVS Mobile Imaging CT 262-366-5970
fredgromalak@gmail.com



Clinical Sonography & Telectology

EDUCATIONAL TELECONSULTATION SERVICES™

1-800-838-4268 info@sonopath.com SonoPath.com

PATIENT

Tank Schmiedlin

SPECIES

Canine

BREED

Australian Shepherd
Mix

SEX

Neutered Male

AGE

12 Years

WEIGHT

17.2 kg

INTERPRETED BY

R. McKenzie Daniel,
DVM, DABVP (Canine
and Feline)

**IMAGING
PERFORMED BY**

Tom McNeill

HOSPITAL NAME

SVS Imaging QC

REFERRING VET

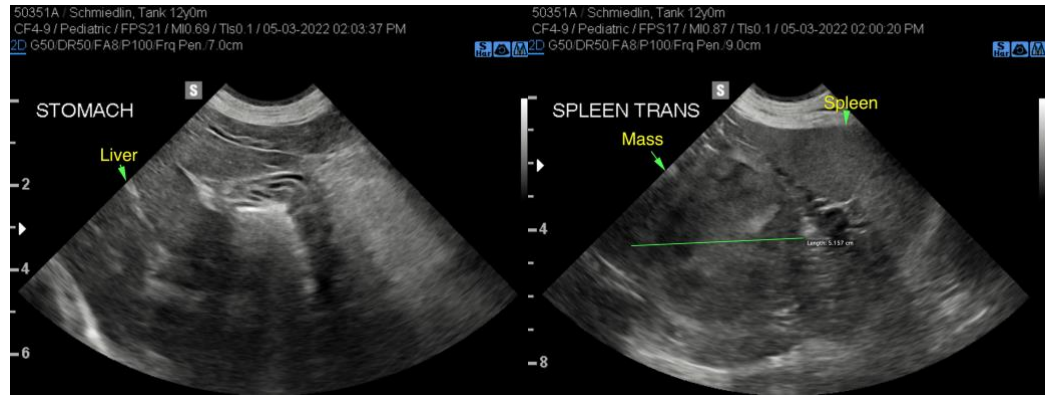
Dr. Marroquin-
Madison VS

INVOICE

15028

DATE

5/3/22



The information and recommendations provided are based on the images presented by the referring veterinarian. No evaluation can be communicated regarding pathology that was not visible in the image/video clips provided.

Thank you for this referral. If the clinical or image interpretation does not parallel your findings or if I can be of any further assistance please contact me.

R. McKenzie Daniel, DVM, DABVP (Canine / Feline Practice)
info@SonoPath.com