



PATIENT

Gracie Gibson

SPECIES

Canine

BREED

Shih Tzu

SEX

FS

AGE

9

WEIGHT

9.6 kg

INTERPRETED BY

R. McKenzie Daniel,
DVM, DABVP
(Canine and Feline)

IMAGING PERFORMED BY

Dr. Belan

HOSPITAL NAME

Ranchlands VC

REFERRING VET

Dr. Sam

INVOICE

13782

DATE

5/3/22

PRESENTING CLINICAL SIGNS

History of hematuria scan done at another clinic diagnosed cystoliths.
Abnormal PE/Chem/CBC/UA Results: UA

ULTRASONOGRAPHIC EXAMINATION OF THE ABDOMEN

Urinary System

The urinary bladder was normal in overall size and tone. Polyploid-like, nonhomogeneous mass appearing to arise from the apical to ventroapical urinary bladder wall extending into the cranial to mid urinary bladder lumen measuring approximately 2.3 cm x 2.2 cm was present. Within the mass were multifocal areas of minor to variably sized mineralization along with potential focal cyst-like intra-mass lesion measuring 0.56 cm in diameter. The urethra exhibited normal structure and tone to a depth of 2.0 cm. Regional apical variable wall thickening adjacent to the polyploid-like mass was present. Anechoic urine primarily was present with mild dependent to potentially adhered mineral / sand.

The area of the aortic trifurcation was free of overt pathology without evidence of obvious medial iliac or sublumbar lymphadenopathy.

Normal size and margination were present in the kidneys. A normal 1:3 cortex / medulla ratio was maintained. The medulla and cortices were uniform in texture with some increased echogenicity and mild to moderate loss of corticomedullary border demarcation primarily owing to increased corticomedullary border parenchyma echogenicity, including multifocal pinpoint areas of corticomedullary border and medullary mineral. No evidence of pyelectasia was present. The left kidney measured 4.6 cm in length. The right kidney measured 4.2 cm in length.

Adrenal Glands

The left adrenal gland was uniform in size and contour with a uniformly hypoechoic parenchyma. The left adrenal gland measured 0.54 cm width at the caudal pole and 0.36 cm width at the cranial pole. The right adrenal gland was uniform in size and contour with a uniformly hypoechoic parenchyma. The right adrenal gland measured 0.53 cm width at the caudal pole and 0.40 cm width at the cranial pole.

Spleen

The spleen exhibited primarily finely textured parenchyma which was hyperechoic to the liver and renal cortical parenchyma. Mild generalized parenchyma heterogeneity was present without evidence of nodular changes. The capsule was smooth and regular without apparent expansion. The splenic vasculature at the hilus was normal in volume with no evidence of congestion or thrombosis. The parenchymal heterogeneity is likely consistent with benign changes such as extramedullary hematopoiesis or age-related remodeling with minor potential for inflammatory or neoplastic disease.

Liver/ Gallbladder

The liver was subjectively normal in size, structure, and contour. The liver parenchyma was mildly nonuniform and hypoechoic to the spleen with a moderate coarse echotexture and subjective mild to benign parenchymal remodeling. The hepatic and portal vasculature were normal in appearance without signs of congestion. The gallbladder was non-distended in size with minor gallbladder debris primarily in the caudal lumen and gallbladder neck. The cystic and common bile ducts were normal.



PATIENT

Gastrointestinal

Gracie Gibson

The stomach presented intact wall layering with a normal wall layer ratio. The lumen of the stomach was empty with no signs of ileus, obstruction, or foreign material.

SPECIES

Canine

The small intestine presented intact wall layering with 1:3 muscularis/mucosa ratio. The lumen of the small intestine was empty with no signs of ileus, obstruction, or foreign material.

BREED

Shih Tzu

Normal visible colon wall layers were present with apparent formed feces in lumen.

SEX

FS

Pancreas

The parenchyma of the left limb, body, and right limb of the pancreas presented isoechoic to the adjacent omental fat. A normal curvilinear capsule contour of the pancreas was present. The visible pancreatic duct was normal. No signs of active inflammation or neoplastic disease were evident.

AGE

9

Free Abdomen

No overt lymphadenopathy or peritoneal effusion was present.

WEIGHT

9.6 kg

ULTRASONOGRAPHIC FINDINGS

Primary Findings

- Apical polyploid-like urinary bladder mass lesion exhibiting multifocal area of mineralization, regional variable apical urinary bladder thickening
- Mild dependent to potentially adhered urinary bladder mineral / sand
- Chronic renal changes exhibiting increased corticomedullary echogenicity and multifocal pinpoint corticomedullary border and medullary mineralization

INTERPRETED BY

R. McKenzie Daniel,
DVM, DABVP
(Canine and Feline)

Secondary Findings

- Mild gallbladder debris - incidental

IMAGING PERFORMED BY

Dr. Belan

INTERPRETATION OF THE FINDINGS & FURTHER RECOMMENDATIONS

HOSPITAL NAME

Ranchlands VC

Considerations for the apical polyploid-like urinary bladder mass, as well as regional apical wall thickening, may include chronic apical cystitis to polyploid cystitis or neoplasia such as transitional cell carcinoma. Given the multifocal areas of mineralization within the polyploid-like mass lesion, concern for neoplastic criteria is warranted, although not definitive.

REFERRING VET

Dr. Sam

Screening BRAF Assay may be considered. However, if negative, biopsy of the urinary bladder mass and regional apical urinary bladder wall would be required for a definitive diagnosis. Given the location of the polyploid-like apical mass, as well as apical urinary bladder wall thickening, potential surgical resection could be possible. Correlation with full urinary workup is suggested. Potentially, this patient may also be passing small amounts of mineral from the kidneys into the urinary bladder.

INVOICE

13782

DATE

5/3/22

Conservatively, pending additional diagnostics, urine culture and sensitivity to rule out underlying infection, as well as Piroxicam or other NSAID trial, assuming normal renal function, and sonographic monitoring of the polyploid-like mass would be reasonable.



PATIENT

Gracie Gibson

SPECIES

Canine

BREED

Shih Tzu

SEX

FS

AGE

9

WEIGHT

9.6 kg

INTERPRETED BY

R. McKenzie Daniel,
DVM, DABVP
(Canine and Feline)

IMAGING PERFORMED BY

Dr. Belan

HOSPITAL NAME

Ranchlands VC

REFERRING VET

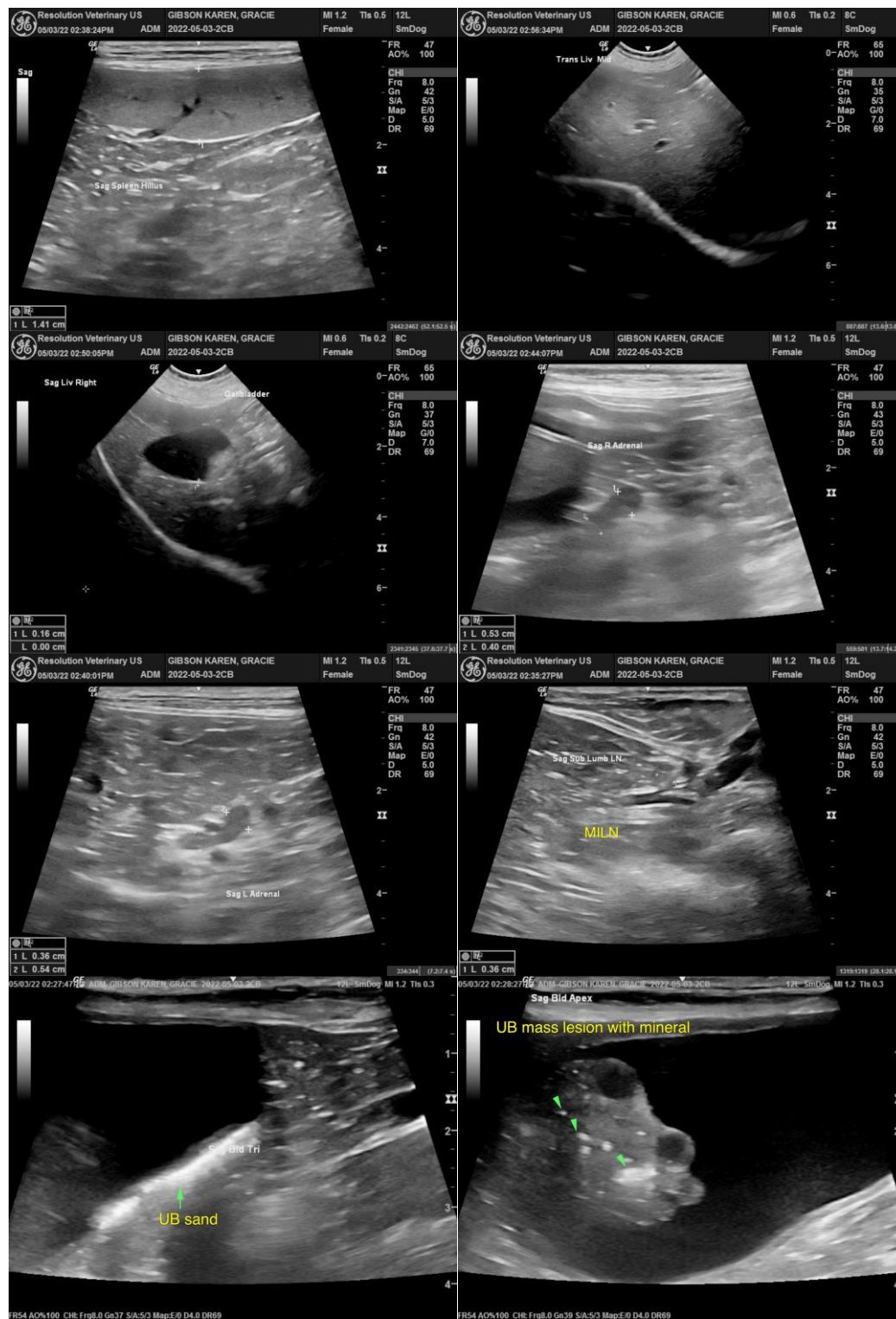
Dr. Sam

INVOICE

13782

DATE

5/3/22





PATIENT

Gracie Gibson

SPECIES

Canine

BREED

Shih Tzu

SEX

FS

AGE

9

WEIGHT

9.6 kg

INTERPRETED BY

R. McKenzie Daniel,
DVM, DABVP
(Canine and Feline)

**IMAGING
PERFORMED BY**

Dr. Belan

HOSPITAL NAME

Ranchlands VC

REFERRING VET

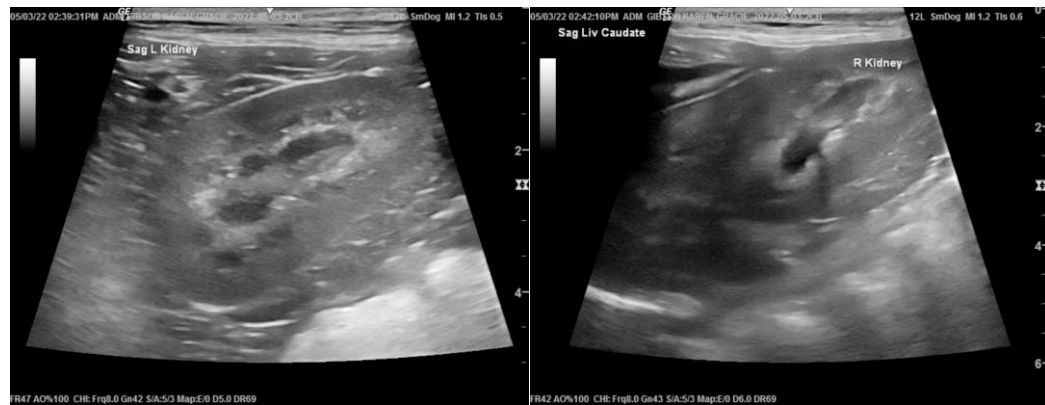
Dr. Sam

INVOICE

13782

DATE

5/3/22



The information and recommendations provided are based on the images presented by the referring veterinarian/sonographer. No evaluation can be communicated regarding pathology that was not visible in the image/video clips provided.

Thank you for this referral. If the clinical or image interpretation does not parallel your findings or if I can be of any further assistance please contact me.

R. McKenzie Daniel, DVM, DABVP (Canine / Feline Practice)
info@SonoPath.com