**PATIENT**

Darcy Winston

SPECIES

Canine

BREED

Minature Schnauzer

SEX

FS

AGE

8 years 11 months

WEIGHT

18.1 lb

INTERPRETED BYR. McKenzie Daniel,
DVM, DABVP (Canine
and Feline)**IMAGING
PERFORMED BY**

Rachel Runnells, RVT

HOSPITAL NAME

SVS Imaging KC

REFERRING VET

Dr. Elizabeth Wilcox

INVOICE

13779

DATE

5/3/22

PRESENTING CLINICAL SIGNS

Elevated liver values - currently asymptomatic at home.
 Abnormal PE/Chem/CBC/UA Results: Elevated ALT, Alk Phos, Triglycerides.

ULTRASONOGRAPHIC EXAMINATION OF THE ABDOMEN**Urinary System**

The urinary bladder, trigone, cystourethral junction, and visible pelvic urethra to a depth of 3.0 cm exhibited normal thickness and tone. Anechoic urine was present in the lumen with no uroliths or sediment. The ureteral papillae were normal. The ureters were not visible which is normal. No evidence of inflammatory or neoplastic changes was noted.

The area of the aortic trifurcation was free of pathology.

Normal size and margination were present in the kidneys. A normal 1:3 cortex / medulla ratio and normal corticomedullary definition were maintained. The echogenicity of the cortex was similar to or slightly less than normal liver parenchyma while the medulla echogenicity was hypoechoic to the cortex with no evidence of pelvic dilation. The left kidney measured 5.0 cm in length. The right kidney measured 4.9 cm in length.

Adrenal Glands

The left adrenal gland exhibited mild mid to caudal enlargement with maintained symmetrical capsule contour and mild nonhomogeneous left adrenal parenchyma with potential for indistinct mid to caudal left adrenal nodule. The area of mid to caudal left adrenal enlargement measured 1.8 cm x 1.1 cm. The overall left adrenal gland measured 1.16 cm width at the caudal pole and 0.47 cm width at the cranial pole. No evidence was noted of vascular invasion, parenchymal escape, or parenchymal mineralization associated with the left adrenal gland.

The right adrenal gland was uniform in size and contour with a uniformly hypoechoic parenchyma. The right adrenal gland measured 0.5 cm width at the caudal pole and 0.63 cm width at the cranial pole.

Spleen

The spleen exhibited a finely textured and homogenous parenchyma which was hyperechoic to the liver and renal cortical parenchyma. The capsule was smooth and regular without apparent expansion. The splenic vasculature at the hilus was normal in volume with no evidence of congestion or thrombosis. Acute to chronic inflammatory, neoplastic, or benign parenchyma changes were not noted.

Liver/ Gallbladder

The liver exhibited generalized enlargement yet maintained symmetrical capsule contour. Mild nonuniform increased hepatic parenchyma echogenicity was present exhibiting multiple non-expansive, subtle, hypoechoic intraparenchymal nodules. The gallbladder was non distended in size with primarily anechoic content with mild, nondependent luminal debris. The cystic duct and common bile ducts were normal without evidence of dilation.

**PATIENT**

Darcy Winston

SPECIES

Canine

BREED

Minature Schnauzer

SEX

FS

AGE

8 years 11 months

WEIGHT

18.1 lb

INTERPRETED BYR. McKenzie Daniel,
DVM, DABVP (Canine
and Feline)**IMAGING
PERFORMED BY**

Rachel Runnells, RVT

HOSPITAL NAME

SVS Imaging KC

REFERRING VET

Dr. Elizabeth Wilcox

INVOICE

13779

DATE

5/3/22

Gastrointestinal

The stomach presented intact wall layering with a normal wall layer ratio. The lumen of the stomach was empty with no signs of ileus, obstruction, or foreign material.

The small intestine presented intact wall layering with 1:3 muscularis/mucosa ratio. The lumen of the small intestine was empty with no signs of ileus, obstruction, or foreign material.

Normal visible colon wall layers were present with apparent formed feces in lumen.

Pancreas

The area of the pancreas base and proximal right pancreatic limb exhibited subtle prominent size with areas of minor capsule asymmetry and mildly hypoechoic parenchyma compared to the adjacent omentum.

Free Abdomen

No overt lymphadenopathy or peritoneal effusion was present.

ULTRASONOGRAPHIC FINDINGS

- Mild mid to caudal left adrenomegaly with possible indistinct to emerging nodule
- Hepatopathy exhibiting mild nonuniform parenchyma hyperechogenicity with intermittent small to subtle hypoechoic nodules
- Mild gallbladder debris (non-mucocele)
- Possible low-grade to chronic active pancreatitis

INTERPRETATION OF THE FINDINGS & FURTHER RECOMMENDATIONS

The overall appearance of the liver was nonspecific yet consistent with benign, likely chronic hepatopathy. Considerations may include vacuolar hepatopathy, inflammatory hepatic parenchymal or hepatobiliary process i.e., cholangiohepatitis with minor parenchymal remodeling, subtle areas of nodular to regenerative hyperplasia, or hematopoiesis. No overt evidence of hepatic neoplastic criteria was noted, which is considered unlikely.

The mild mid to caudal left adrenomegaly may indicate emerging adenomatous change, benign hyperplasia, while the possibility of emerging left adrenal neoplasia, although considered unlikely, cannot be definitively excluded. Given the reported asymptomatic patient, adrenal hyper-functionality is considered unlikely. Full adrenal workup could be considered if clinical signs suggestive of adrenal hyperfunction arise. Screening blood pressure is recommended to assess for evidence of hypertension, which may allude to a potential emerging left adrenal neoplasia, i.e., pheochromocytoma.

Depending on elevated triglyceride levels, fasting triglycerides, given the breed disposition to hyperlipidemia, may be considered. Sonographic monitoring of the left adrenal gland for evidence of progressive mid to caudal enlargement with initial recheck in 6 weeks would be ideal. Assessment of cranial abdominal / subxiphoid discomfort associated with low grade pancreatitis +/- spec cPL is



PATIENT

Darcy Winston

SPECIES

Canine

BREED

Minature Schnauzer

SEX

FS

AGE

8 years 11 months

WEIGHT

18.1 lb

INTERPRETED BY

R. McKenzie Daniel,
DVM, DABVP (Canine
and Feline)

**IMAGING
PERFORMED BY**

Rachel Runnells, RVT

HOSPITAL NAME

SVS Imaging KC

REFERRING VET

Dr. Elizabeth Wilcox

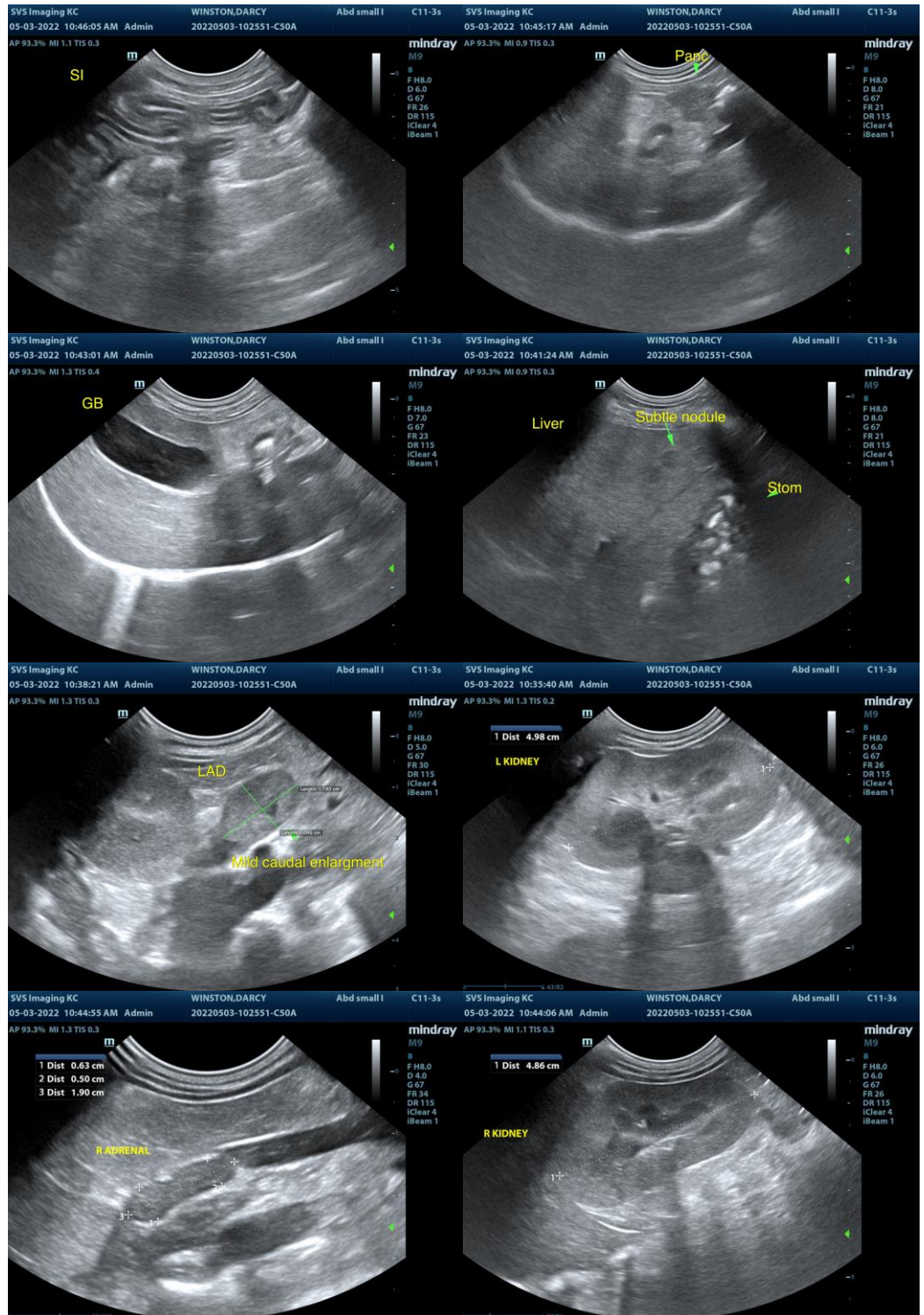
INVOICE

13779

DATE

5/3/22

suggested. Empirical hepatosupportive medications including Denamarin and Ursodiol may prove beneficial.



IMAGING PERFORMED BY

SVS Mobile Imaging KC 816-401-5010
svsimagingkc@gmail.com



Clinical Sonography & Telectology

EDUCATIONAL TELECONSULTATION SERVICES™

1-800-838-4268 info@sonopath.com SonoPath.com

PATIENT

Darcy Winston

SPECIES

Canine

BREED

Minature Schnauzer

SEX

FS

AGE

8 years 11 months

WEIGHT

18.1 lb

INTERPRETED BY

R. McKenzie Daniel,
DVM, DABVP (Canine
and Feline)

**IMAGING
PERFORMED BY**

Rachel Runnells, RVT

HOSPITAL NAME

SVS Imaging KC

REFERRING VET

Dr. Elizabeth Wilcox

INVOICE

13779

DATE

5/3/22

The information and recommendations provided are based on the images presented by the referring veterinarian/sonographer. No evaluation can be communicated regarding pathology that was not visible in the image/video clips provided.

Thank you for this referral. If the clinical or image interpretation does not parallel your findings or if I can be of any further assistance please contact me.

**R. McKenzie Daniel, DVM, DABVP (Canine / Feline Practice)
info@SonoPath.com**