



**PATIENT**

Watson Silverman

**SPECIES**

Canine

**BREED**

Maltese/Poodle

**SEX**

MN

**AGE**

16Y, 4M

**WEIGHT**

17.3lbs

**PRESENTING CLINICAL SIGNS**

Grade 5/6 heart murmur. Current meds: Carprofen 25mg bid x 30 days; Gabapentin 50mg 2cc po bid x 30 days; Vetmedin 50mg (1/2 tab bid)

**ULTRASONOGRAPHIC EXAMINATION OF THE HEART**

CANINE CARDIAC PARAMETERS	MR VMAX (m/s)	TR VMAX (m/s)	LA/AO (M-mode)	LA/AO (Heart Base; Swe)	FS (%)	EF (%)	EPSS (cm)
NORMAL PARAMETER	4.5-5.5	<2.7	1.3	Up to 1.6	28-40	40-100	<0.6
PATIENT			NM	1.2	39	71	0.2
CANINE CARDIAC PARAMETERS	HR (BPM)	AV VMAX (m/s)	PV MAX (m/s)	BODY WEIGHT (lbs)	LAD LA MAX 4 Chamber	LVIDd Avg; 2D and m-mode short axis (cm)	LVIDs Avg; 2D and m-mode short axis (cm)
NORMAL PARAMETER	50-100	0.7-1.7	0.7-1.6				
PATIENT	NM	1.2	1.0	17.3	2.7	2.7	

**INTERPRETED BY**

R. McKenzie Daniel,  
DVM, DABVP  
(Canine and Feline)

**IMAGING PERFORMED BY**

Shari Reffi, CVT

**HOSPITAL NAME**

William Penn  
Veterinary Hospital

**REFERRING VET**

Dr. Bouzaout

**INVOICE**

75193

**DATE**

5-28-26

**Cardiac Presentation**

The echocardiogram in this patient demonstrated normal **left atrial** size based on 2 different LA measurement methods. The cranial and caudal **mitral** valve leaflets presented thickening (anterior greater than posterior) consistent with endocardiosis. No evidence of valvular prolapse. MR velocity 5.8 m/s. Doppler indicated significant eccentric MR. The **left ventricle** presented thicknesses with linear contour and was not dilated nor restricted. The **myocardium** presented normal echogenicity without subjective evidence of significant fibrotic or ischemic disease. **Contractility** of the ventricular walls was adequate and in normal range for this patient evidenced by the fractional shortening measurement and subjective evaluation of the different regions of the myocardium. The **left ventricular outflow** tract demonstrated normal laminar flow and subjective structural integrity. The **right atrium** and auricle revealed normal size, structure and content. No evidence of masses was noted or chamber overload. **Tricuspid** valvular assessment demonstrated mildly thickened with mild TR on Doppler. Measured TR velocity 2.8 m/s max. The **right ventricle** was of normal size (1/3 diameter of LV), chordae structure, myocardial echogenicity and thickness. **Pulmonic** tract assessment revealed normal valve structure, laminar flow, and diameter (approx.1:1 pa/ao ratio). No visible **pericardial** or free pleura fluid was noted. No echographically detectable evidence of cardiac / pericardial tumors was visible.

**ULTRASONOGRAPHIC FINDINGS**

- Compensated mitral valve disease (ACVIM B1).
- Mild tricuspid insufficiency - no evidence of clinical pulmonary hypertension.



**PATIENT**

Watson Silverman

**SPECIES**

Canine

**BREED**

Maltese/Poodle

**SEX**

MN

**AGE**

16Y, 4M

**WEIGHT**

17.3lbs

**INTERPRETED BY**

R. McKenzie Daniel,  
DVM, DABVP  
(Canine and Feline)

**IMAGING PERFORMED BY**

Shari Reffi, CVT

**HOSPITAL NAME**

William Penn  
Veterinary Hospital

**REFERRING VET**

Dr. Bouzaout

**INVOICE**

75193

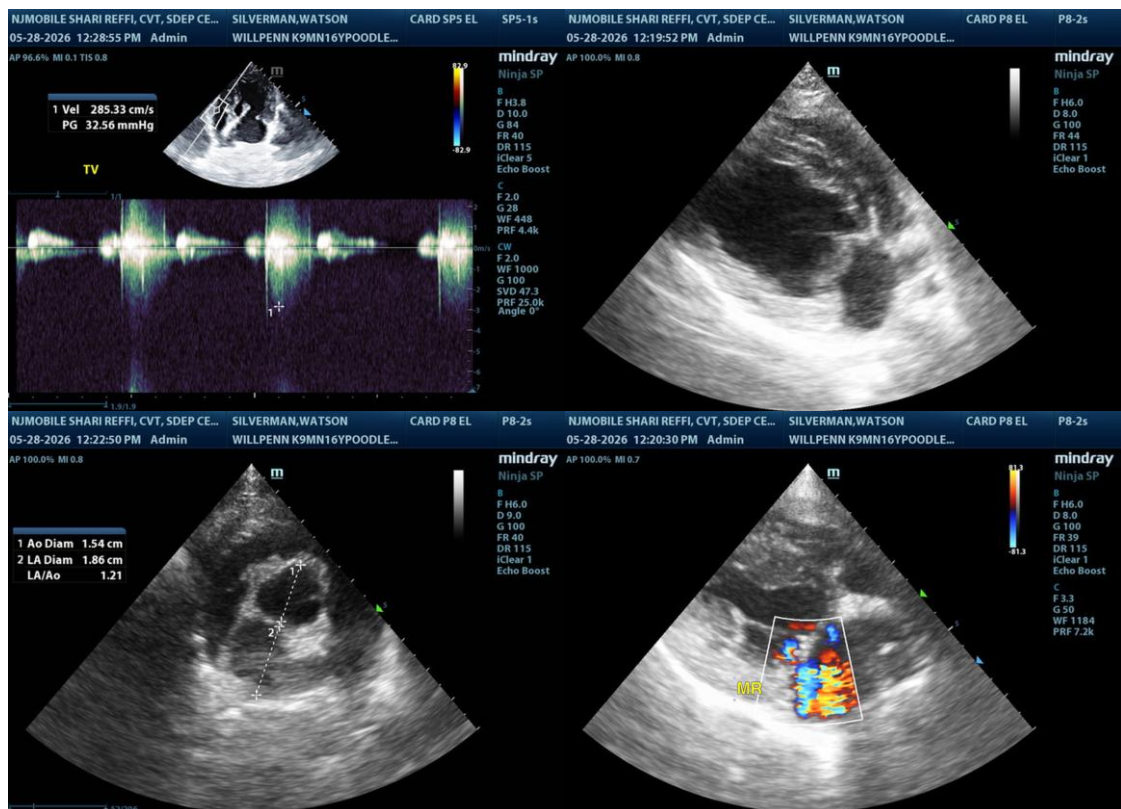
**DATE**

5-28-26

**INTERPRETATION OF THE FINDINGS & FURTHER RECOMMENDATIONS**

The cause of the murmur is chronic degenerative valvular changes with secondary eccentric mitral valve insufficiency. The lack of left atrial enlargement implies that the risk of complication secondary to mitral valve insufficiency is low at this time and, without current clinical signs, indicates that medical therapy is not required. Prognosis is considered variable and sonographic monitoring is recommended. Recheck echo cardiogram is suggested in 6-12 months, sooner if clinical signs arise. Anesthetic risk is considered mild.

Suggested anesthetic protocol may include opioid or Benzodiazepine pre-med, induction with Propofol or Alfaxalone, and appropriate gas anesthesia with avoidance of alpha 2 agonists.



The information and recommendations provided are based on the images presented by the referring veterinarian/sonographer. No evaluation can be communicated regarding pathology that was not visible in the image/video clips provided.

Thank you for this referral. If the clinical or image interpretation does not parallel your findings or if I can be of any further assistance, please contact me.

R. McKenzie Daniel, DVM, DABVP (Canine / Feline Practice)  
[info@sonopath.com](mailto:info@sonopath.com)