

PATIENT

Abbey Cline

SPECIES

Canine

BREED

Mixed

SEX

Spayed Female

AGE

10 Years

WEIGHT

81 lbs

INTERPRETED BY

R. McKenzie Daniel,
DVM, DABVP (Canine
/ Feline Practice)

IMAGING PERFORMED BY

Keisha Smitley CVT

HOSPITAL NAME

Geary Veterinary
Services

REFERRING VET

Dr. Curtis Geary, VMD

INVOICE

16550

DATE

05/28/26

PRESENTING CLINICAL SIGNS

Patient presenting today for hematuria with clots/mucus present. Patient has a history of CKD.

ULTRASONOGRAPHIC EXAMINATION OF THE ABDOMEN

Submitted study contained four videos of the urinary bladder only.

Urinary System

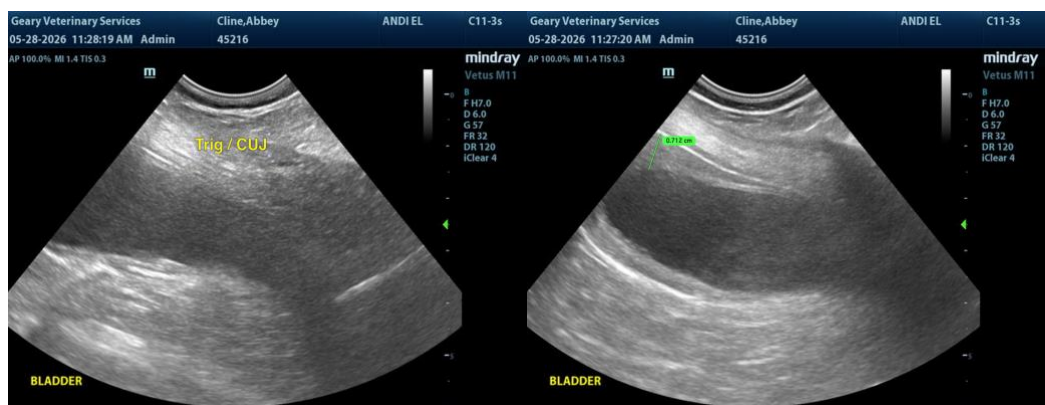
The urinary bladder presented mildly thickened wall isoechoic to the adjacent normal urinary bladder wall primarily visualized the ventral apical to dorsoapical urinary bladder exhibiting maintained homogenous mural echogenicity with no evidence of tumors or mural mineralization. Ventral apical urinary bladder wall thickness measured 0.71 cm. Mineralization or echogenic foci within the thickened areas of urinary bladder wall was not present. The trigone and cystourethral junction were free of pathology. Anechoic urine was present in the lumen with mild nondependent particulate urine sediment. The ureteral papillae were normal. The ureters were not visible which is normal. The visible proximal urethra was normal in structure and tone to a depth of 3.0 cm.

ULTRASONOGRAPHIC FINDINGS

- Mild cystitis pattern with mild urine sediment.

INTERPRETATION OF THE FINDINGS & FURTHER RECOMMENDATIONS

No evidence of significant urinary bladder or visible proximal urethral pathology with mild cystitis pattern. No evidence of tumors, mineral, or calculi. Correlation with pending urinalysis culture and cytology is recommended. If atypical transitional cell, screening BRAF assay is suggested. Concurrent renal imaging is suggested to assess for evidence of pathology which may contribute to hematuria, if negative urine culture and sensitivity and given reported historical chronic kidney disease.



The information and recommendations provided are based on the images presented by the referring veterinarian/sonographer. No evaluation can be communicated regarding pathology that was not visible in the image/video clips provided.

Thank you for this referral. If the clinical or image interpretation does not parallel your findings or if I can be of any further assistance, please contact me.

R. McKenzie Daniel, DVM, DABVP (Canine / Feline Practice)



PATIENT

info@SonoPath.com

Abbey Cline

SPECIES

Canine

BREED

Mixed

SEX

Spayed Female

AGE

10 Years

WEIGHT

81 lbs

INTERPRETED BY

R. McKenzie Daniel,
DVM, DABVP (Canine
/ Feline Practice)

**IMAGING
PERFORMED BY**

Keisha Smitley CVT

HOSPITAL NAME

Geary Veterinary
Services

REFERRING VET

Dr. Curtis Geary, VMD

INVOICE

16550

DATE

05/28/26