



PATIENT

Tux Bartel

SPECIES

Canine

BREED

Poodle Mix

SEX

MN

AGE

7

WEIGHT

16.1kg

INTERPRETED BY

R. McKenzie Daniel,
DVM, DABVP
(Canine and Feline)

IMAGING PERFORMED BY

Dr Gira

HOSPITAL NAME

Healthy Paws Forward

REFERRING VET

Dr Hamed

INVOICE

24971

DATE

05/27/2026

PRESENTING CLINICAL SIGNS

Progressive liver enzyme elevation . Patient is currently on OM diet

Abnormal PE/Chem/CBC/UA Results: attached

ULTRASONOGRAPHIC EXAMINATION OF THE ABDOMEN

Urinary System

The urinary bladder, trigone, cystourethral junction, and visible pelvic urethra to a depth of 3 cm exhibited normal thickness and tone. Anechoic urine was present in the lumen with no evidence of urine/lumen sediment, mineral, or calculi. The ureteral papillae were normal. The ureters were not visible which is normal. No evidence of inflammatory or neoplastic changes was noted.

Normal size and margination were present in the kidneys. A normal 1:3 cortex / medulla ratio was maintained. The medulla and cortices were uniform in texture with some increased echogenicity and mild loss of corticomedullary symmetry and definition expected for the age of the patient. No evidence of pelvic dilation was present. The left kidney measured 5.4 cm in length. The right kidney measured 5.0 cm in length.

The area of the aortic trifurcation was free of pathology.

The residual prostate appeared normal and free of pathology

Adrenal Glands

The left adrenal gland was uniform in size and contour with a uniformly hypoechoic parenchyma. The left adrenal gland measured 0.70 cm width at the caudal pole. The right adrenal gland was uniform in size and contour with a uniformly hypoechoic parenchyma. The right adrenal gland measured 0.55 cm width at the caudal pole.

Spleen

The spleen exhibited a finely textured and homogenous parenchyma which was hyperechoic to the liver and renal cortical parenchyma. The capsule was smooth and regular without apparent expansion. The splenic vasculature at the hilus was normal in volume with no evidence of congestion or thrombosis. Acute to chronic inflammatory, neoplastic, or benign parenchyma changes were not noted.

Liver/Gallbladder

The liver presented borderline to mildly enlarged in size. The parenchyma of the liver was subjectively normal in echogenicity compared to the spleen and renal cortices. The liver parenchyma was uniform with a mildly coarse echotexture. The capsule of the liver was symmetrically rounded to mildly swollen in margination. The hepatic and portal vasculature were normal in appearance without signs of congestion. The gallbladder was non-distended in size with mild congealed caudal lumen non-organized debris The cystic and common bile ducts were normal.

Gastrointestinal

The stomach presented intact wall layering with a normal wall layer ratio. The lumen of the stomach was empty with no signs of ileus, obstruction or foreign material.



PATIENT

Tux Bartel

SPECIES

Canine

BREED

Poodle Mix

SEX

MN

AGE

7

WEIGHT

16.1kg

INTERPRETED BY

R. McKenzie Daniel,
DVM, DABVP
(Canine and Feline)

IMAGING PERFORMED BY

Dr Gira

HOSPITAL NAME

Healthy Paws Forward

REFERRING VET

Dr Hamed

INVOICE

24971

DATE

05/27/2026

The small intestine presented intact wall layering with 1:3 muscularis/mucosa ratio. The lumen of the small intestine was empty with no signs of mechanical/metabolic ileus, obstruction or foreign material.

Normal visible colon wall layers were present. The colon was distended with formed fecal matter.

Pancreas

The parenchyma of the left limb, body and right limb of the pancreas presented isoechoic to the adjacent omental fat. A normal curvilinear capsule contour of the pancreas was present. The visible pancreatic duct was normal. No signs of active inflammation or neoplastic disease was evident.

Free Abdomen

Scant pocket of fluid noted between the apical bladder and adjacent colon. This is likely incidental or physiologic free fluid, given no evidence of abdominal inflammation and assuming normal ALB levels.

Intermittent mildly prominent to enlarged jejunal lymph nodes were present. The lymph nodes were essentially isoechoic to adjacent omentum without evidence of peripheral inflammation and maintaining a normal width: length ratio (<0.5). An example measured 2.0 cm x 0.53 cm.

ULTRASONOGRAPHIC FINDINGS

Primary

- Non-specific hepatopathy -subjective benign
- Mild non-organized gallbladder debris (non-mucocele)
- Age-related renal changes
- Normal bilateral adrenal glands

INTERPRETATION OF THE FINDINGS & FURTHER RECOMMENDATIONS

The appearance of the liver was nonspecific but most consistent with benign hepatopathy. Considerations for the liver may include benign vacuolar hepatopathy, inflammatory/infectious/immune mediated disease, hyperplasia, hematopoiesis, toxic hepatopathy (i.e., copper) or other with neoplasia thought less likely. Ultrasound guided FNA of the liver using a 25-gauge needle and assuming normal coagulation parameters would be warranted for screening cytology. Hepatosupportive medications such as Denamarin or Vitamin E as well as Ursodiol due to its antioxidant and immunomodulatory effects within the liver would be warranted, although these medications may not result in decreased hepatic enzyme levels. Leptospirosis titers / PCR may be considered if clinically indicated. Core or surgical biopsy is likely required for definitive diagnosis.

No evidence of adrenal pathology as a contributing factor to the hepatopathy in conjunction with no reported clinical signs. If clinical signs which may suggest adrenal disease are not reported or arise, adrenal screening or workup may be considered despite lack of adrenal pathology.



PATIENT

Tux Bartel

SPECIES

Canine

BREED

Poodle Mix

SEX

MN

AGE

7

WEIGHT

16.1kg

INTERPRETED BY

R. McKenzie Daniel,
DVM, DABVP
(Canine and Feline)

IMAGING PERFORMED BY

Dr Gira

HOSPITAL NAME

Healthy Paws Forward

REFERRING VET

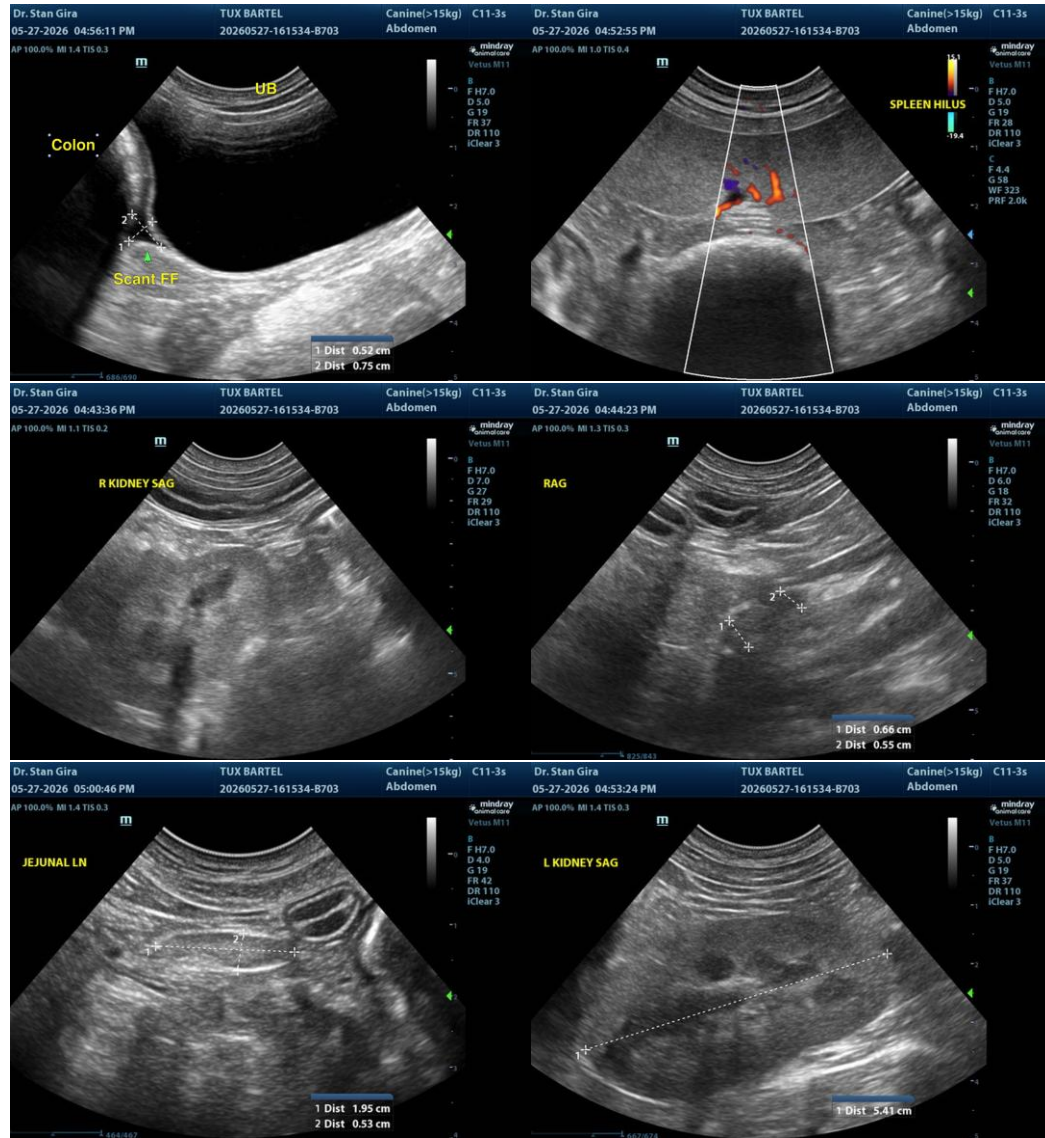
Dr Hamed

INVOICE

24971

DATE

05/27/2026





PATIENT

Tux Bartel

SPECIES

Canine

BREED

Poodle Mix

SEX

MN

AGE

7

WEIGHT

16.1kg

INTERPRETED BY

R. McKenzie Daniel,
DVM, DABVP
(Canine and Feline)

IMAGING PERFORMED BY

Dr Gira

HOSPITAL NAME

Healthy Paws Forward

REFERRING VET

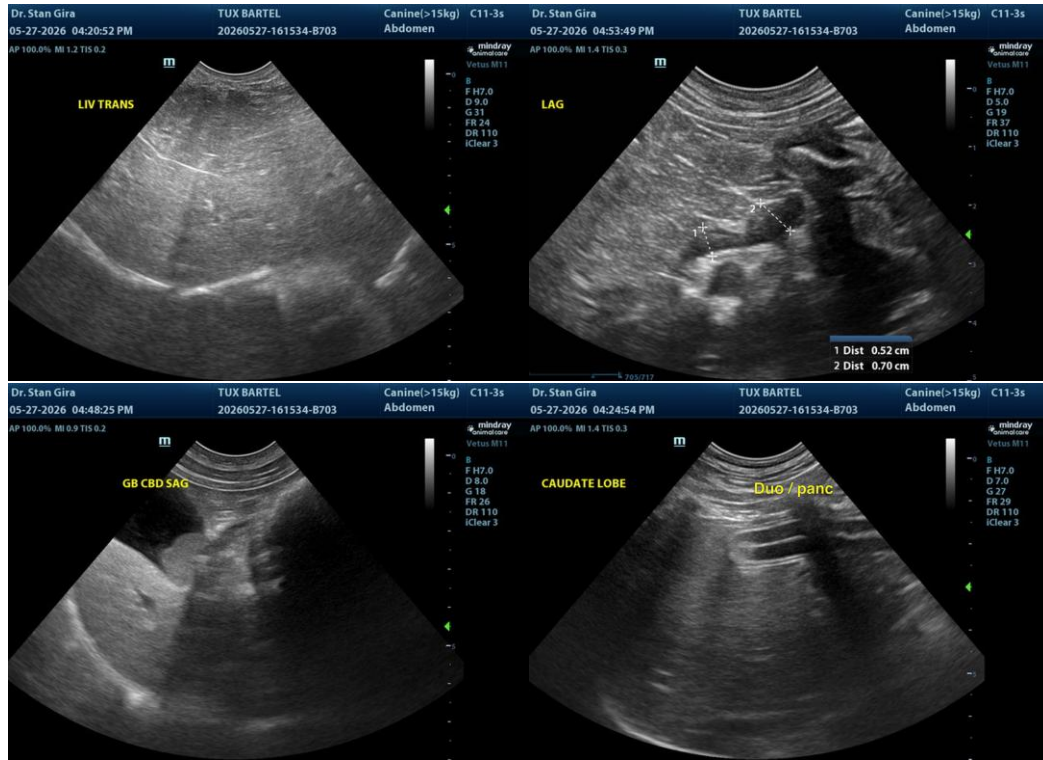
Dr Hamed

INVOICE

24971

DATE

05/27/2026



The information and recommendations provided are based on the images presented by the referring veterinarian/sonographer. No evaluation can be communicated regarding pathology that was not visible in the image/video clips provided.

Thank you for this referral. If the clinical or image interpretation does not parallel your findings or if I can be of any further assistance, please contact me.

R. McKenzie Daniel, DVM, DABVP (Canine/Feline Practice)
info@sonopath.com