



PATIENT

Nezu Tengwell

SPECIES

Feline

BREED

DSH

SEX

Neutered Male

AGE

9 Years

WEIGHT

7.3 lbs

INTERPRETED BY

R. McKenzie Daniel,
 DVM, DABVP (Canine
 / Feline Practice)

IMAGING PERFORMED BY

Chloe Lowe, CVT

HOSPITAL NAME

Newton Veterinary
 Hospital

REFERRING VET

Dr. Hipkin

INVOICE

16540

DATE

05/27/26

PRESENTING CLINICAL SIGNS

DKA, severe hypokalemia 1.7 at admit. Dull menace emaciated; BG/ ketones plateaved. Insulin R CRI (IVECC protocol), LRS with KCL, Cerenia, elura.

Abnormal PE/Chem/CBC/UA Results: BUN 100.7, creat 2, phos 2.1, TP 8.9, Alb 4.2, gluc 597, ket 2.5, chol > 450, Alt 134, Tbili 1.2, Na 119, k 1.7, Cl 81, Wbc 41k, neu 40k, lym 0.42

ULTRASONOGRAPHIC EXAMINATION OF THE HEART & ABDOMEN

FELINE CARDIAC PARAMETERS	BODY WEIGHT (lbs)	HR (BPM)	IVSd (cm)	LVIDd (cm)	LVWd (cm)	FS (%)	EF (%)
NORMAL PARAMETER	-----	150-240	0.3-0.6	1.0-2.1	0.25-0.6	35-67	80-100
PATIENT	7.3	212	0.44	1.45	0.44	40	74
FELINE CARDIAC PARAMETERS	LA/AO (M-mode)	LA/AO HEART BASE (Sisson)	LAD LA MAX 4 Chamber		LVOT VEL. (m/s)	RVOT VEL. (m/s)	IVRT (m/)
NORMAL PARAMETER	<1.5	1.6	0.7-1.7		<1.6	<1.3	40-60
PATIENT	--	1.4	1.4		1.3	0.7	NM
Adapted from June Boon, Veterinary Echocardiography, 1998 Sisson D et al. JVIM 1991; 5: 232, Jacobs et al. Am J Vet Res 1985; 46:1705							

Cardiac Presentation

The echocardiogram in this patient demonstrated normal **left atrial** dimension based on 2 LA measurements. The cranial and caudal **mitral** valve leaflets presented normal linear structure and kinetics. The **left ventricle** presented normal thicknesses with linear contour and was not dilated nor restricted. The **myocardium** presented normal echogenicity without subjective evidence of significant fibrotic or ischemic disease. **Contractility** of the ventricular walls was adequate and in normal range for this patient evidenced by the fractional shortening measurement and subjective evaluation of the different regions and angles of the myocardium. The **left ventricular outflow** tract demonstrated normal laminar flow and subjective structural integrity. The **right atrium** and auricle revealed normal size, structure and content. No evidence of masses was noted or chamber overload. **Tricuspid** valvular assessment demonstrated adequate linear morphology and kinetics. The **right ventricle** was of normal size (1/3 diameter of LV), chordae structure, myocardial echogenicity and thickness. **Pulmonic** tract assessment revealed normal valve structure, laminar flow, and diameter (approx. 1:1 pa/ao ratio). No visible **pericardial** or free pleura fluid was noted or extra cardiac pathology in the visible planes. The cranial **mediastinum** and **pericardial regions** were free of masses in the visible window.

Urinary System

The urinary bladder, trigone, cystourethral junction, and visible pelvic urethra to a depth of 3.0 cm exhibited normal thickness and tone. Anechoic urine was present in the lumen with no uroliths or



PATIENT

Nezu Tengwell

sediment. The ureteral papillae were normal. The ureters were not visible which is normal. No evidence of inflammatory or neoplastic change were noted.

SPECIES

Feline

Mild enlargement and symmetrical margination was present in the kidneys. A normal 1:3 cortex / medulla ratio was maintained. The medulla and cortices were uniform in texture with some increased echogenicity and mild loss of corticomedullary symmetry and definition expected for the age of the patient. No evidence of pelvic dilation was present. The left kidney measured 5.1 cm in length. The right kidney measured 4.5 cm in length.

BREED

DSH

Adrenal Glands

The adrenal glands were mildly enlarged with symmetrical contour and homogenous parenchyma. The left adrenal gland measured 0.67 cm width. The right adrenal gland measured 0.61 cm width.

SEX

Neutered Male

Spleen

The spleen presented subnormal in size (consistent with volume contraction) and exhibited a finely textured and homogenous parenchyma which was hyperechoic to the liver and renal cortical parenchyma. The capsule was smooth and regular without apparent expansion. The splenic vasculature at the hilus was normal in volume with no evidence of congestion or thrombosis. Acute to chronic inflammatory, neoplastic, or benign parenchyma changes were not noted.

AGE

9 Years

WEIGHT

7.3 lbs

Liver & Gallbladder

The liver presented mildly enlarged in size. The parenchyma of the liver was subjectively normal in echogenicity compared to the spleen and renal cortices. The liver parenchyma was uniform with a mildly coarse echotexture. The capsule of the liver was symmetrically rounded to mildly swollen in margination. The hepatic and portal vasculature were normal in appearance without signs of congestion.

INTERPRETED BY

R. McKenzie Daniel,
DVM, DABVP (Canine
/ Feline Practice)

The gallbladder was non distended in size with mild biliary sludge. The common bile duct was not visualized.

IMAGING PERFORMED BY

Chloe Lowe, CVT

Gastrointestinal

The stomach presented intact wall layering with a normal wall layer ratio. The lumen of the stomach was empty with no signs of ileus, obstruction or foreign material.

HOSPITAL NAME

Newton Veterinary
Hospital

The small intestine presented primarily intact nonthickened wall with propensity for subtle prominence of generalized intestinal muscularis layer. A small nonobstructive jejunal mass was present in the mid to cranial abdomen primarily secondary to segmental moderately thickened jejuna; muscularis layer measuring approximately 1.4 cm in diameter. Nonthickened small intestine wall measured 0.20 cm wall width.

REFERRING VET

Dr. Hipkin

INVOICE

16540

Normal visible colon wall layers were present with apparent formed feces in lumen.

Pancreas

DATE

05/27/26

The pancreas presented prominent in size exhibiting mild nonhomogenous hypoechoic parenchyma compared to adjacent nonreactive or inflamed omentum.

Free Abdomen



PATIENT

No overt lymphadenopathy or peritoneal effusion was present.

Nezu Tengwell

ULTRASONOGRAPHIC FINDINGS

SPECIES

- Normal echocardiogram.
- Bilateral adrenomegaly exhibiting intact architecture- possible diabetic nephropathy.
- Mild hepatomegaly- subjective benign.
- Mild gallbladder debris.
- Chronic/chronic active pancreatitis.
- Bilateral mild renomegaly.
- Emerging to small jejunal mural mass- nonobstructive.

Feline

BREED

DSH

SEX

Neutered Male

INTERPRETATION OF THE FINDINGS & FURTHER RECOMMENDATIONS

Adrenal workup, given the diabetes as well as serum aldosterone level, given hypokalemia, is recommended in conjunction with the bilateral mild adrenomegaly. Further renal staging to include urine C/S and protein: creatinine ratio on sterile urine sample may be considered.

AGE

9 Years

A spec fPL is warranted. Continued empirical therapy for diabetic ketoacidosis with electrolyte supplementation and clinical monitoring is indicated. If patient is stabilized, concurrent sonographic monitoring of the emerging to small jejunal mural mass for evidence of progression with consideration for mass sampling for further clarification is recommended.

WEIGHT

7.3 lbs

INTERPRETED BY

R. McKenzie Daniel,
 DVM, DABVP (Canine
 / Feline Practice)

IMAGING PERFORMED BY

Chloe Lowe, CVT

HOSPITAL NAME

Newton Veterinary
 Hospital

REFERRING VET

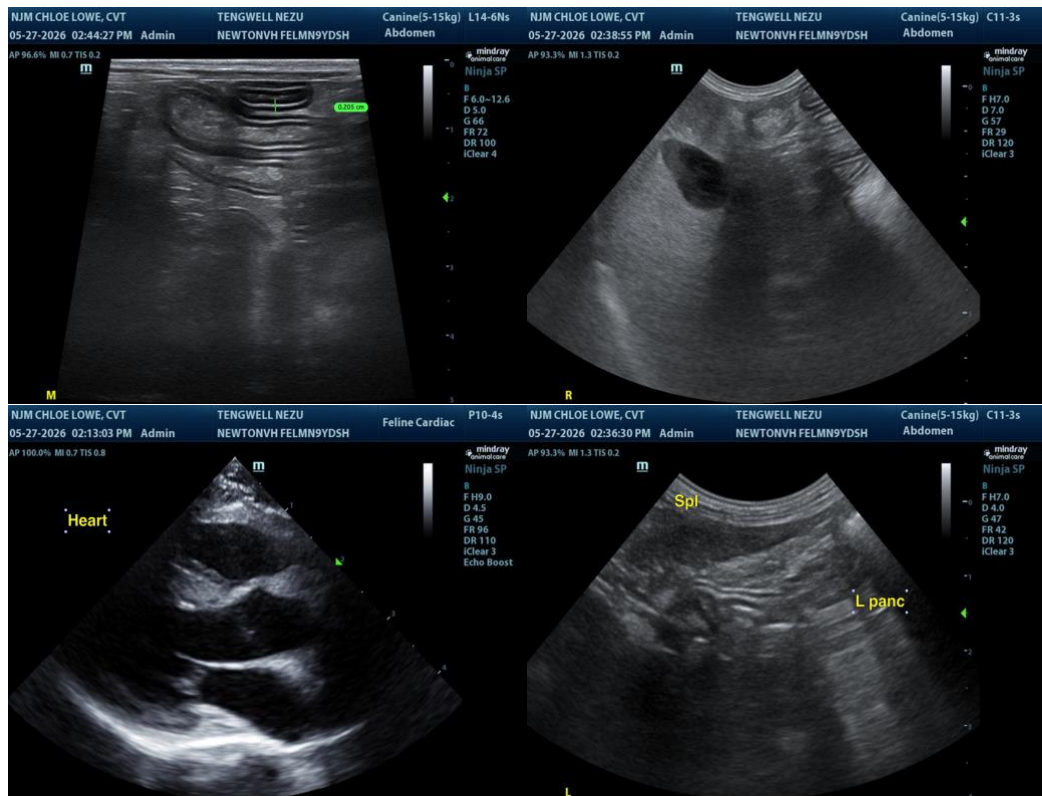
Dr. Hipkin

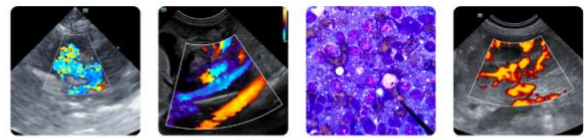
INVOICE

16540

DATE

05/27/26





PATIENT

Nezu Tengwell

SPECIES

Feline

BREED

DSH

SEX

Neutered Male

AGE

9 Years

WEIGHT

7.3 lbs

INTERPRETED BY

R. McKenzie Daniel,
 DVM, DABVP (Canine
 / Feline Practice)

IMAGING PERFORMED BY

Chloe Lowe, CVT

HOSPITAL NAME

Newton Veterinary
 Hospital

REFERRING VET

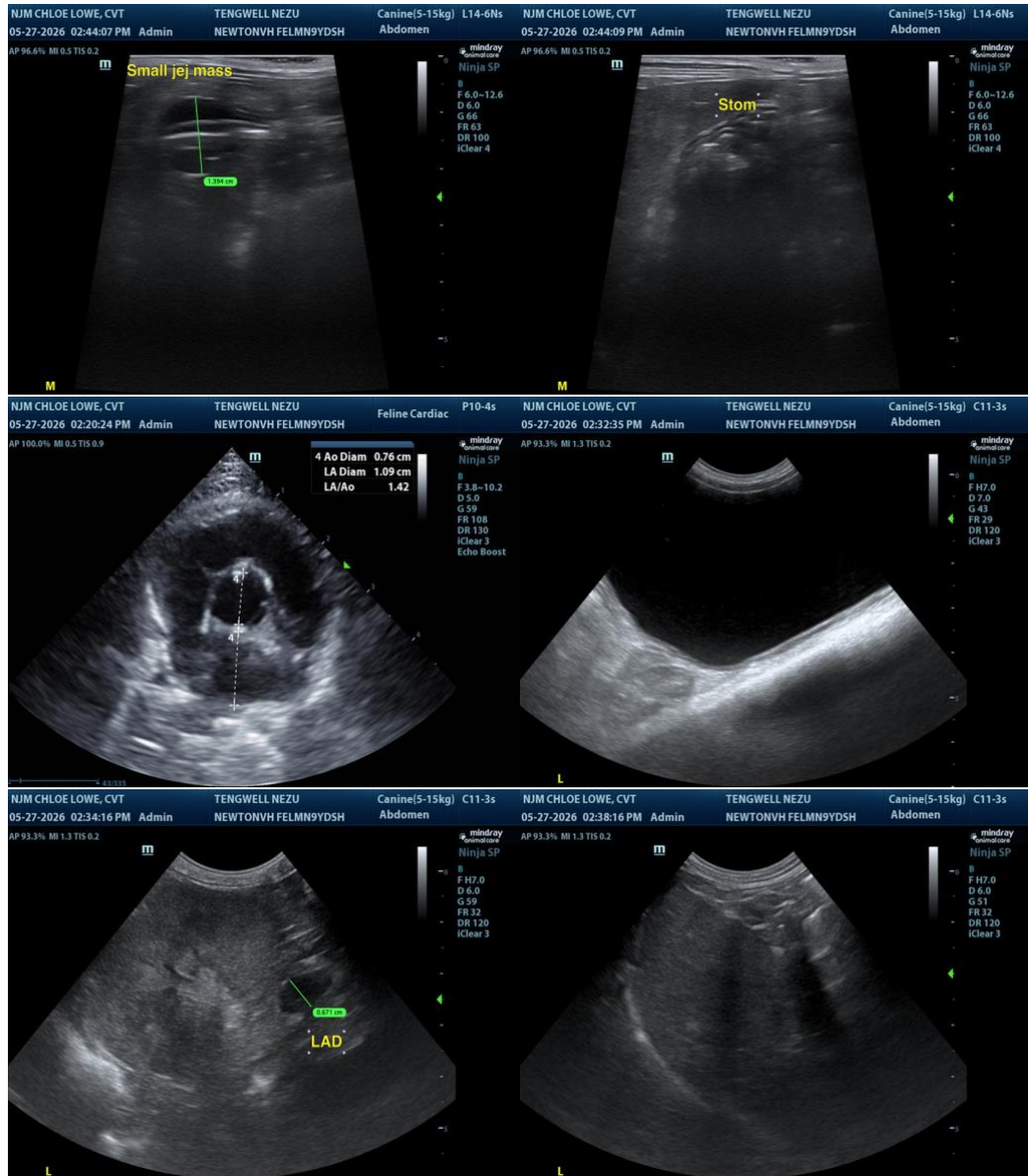
Dr. Hipkin

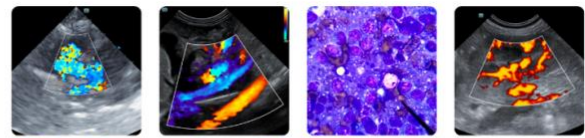
INVOICE

16540

DATE

05/27/26





PATIENT

Nezu Tengwell

SPECIES

Feline

BREED

DSH

SEX

Neutered Male

AGE

9 Years

WEIGHT

7.3 lbs

INTERPRETED BY

R. McKenzie Daniel,
 DVM, DABVP (Canine
 / Feline Practice)

IMAGING PERFORMED BY

Chloe Lowe, CVT

HOSPITAL NAME

Newton Veterinary
 Hospital

REFERRING VET

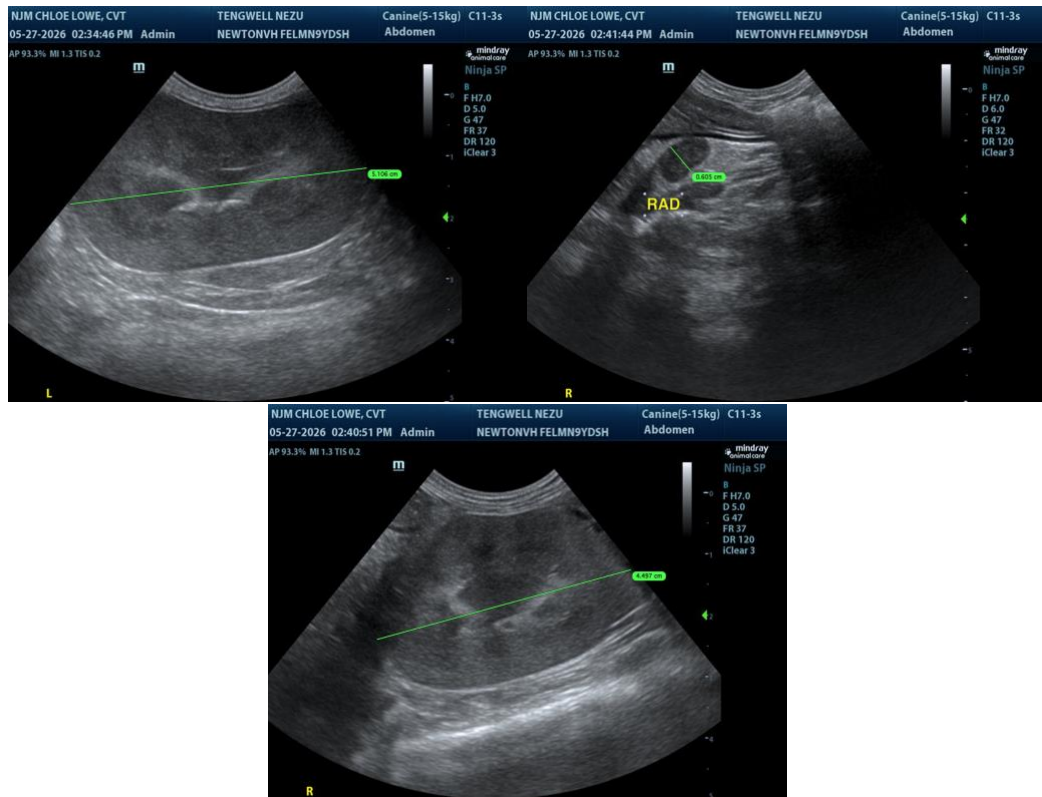
Dr. Hipkin

INVOICE

16540

DATE

05/27/26



The information and recommendations provided are based on the images presented by the referring veterinarian/sonographer. No evaluation can be communicated regarding pathology that was not visible in the image/video clips provided.

Thank you for this referral. If the clinical or image interpretation does not parallel your findings or if I can be of any further assistance, please contact me.

R. McKenzie Daniel, DVM, DABVP (Canine / Feline Practice)

info@SonoPath.com