



PATIENT

Dorian Depasquale

SPECIES

Feline

BREED

DSH

SEX

MN

AGE

14Y

WEIGHT

10lbs

PRESENTING CLINICAL SIGNS

Assessment of cardiac status prior to anesthesia, HM prev. noticed

ULTRASONOGRAPHIC EXAMINATION OF THE HEART

FELINE CARDIAC PARAMETERS	BODY WEIGHT (lbs)	HR (BPM)	IVSd (cm)	LVIDd (cm)	LVWd (cm)	FS (%)	EF (%)
NORMAL PARAMETER	-----	150-240	0.3-0.6	1.0-2.1	0.25-0.6	35-67	80-100
PATIENT	10.0	NM	0.5	1.4	0.5	48	81
FELINE CARDIAC PARAMETERS	LA/AO (M-mode)	LA/AO HEART BASE (Sisson)	LAD LA MAX 4 Chamber		LVOT VEL. (m/s)	RVOT VEL. (m/s)	IVRT (m/)
NORMAL PARAMETER	<1.5	1.6	0.7-1.7		<1.6	<1.3	40-60
PATIENT	--	1.3	1.3		1.1	0.8	NM
Adapted from June Boon, Veterinary Echocardiography, 1998 Sisson D et al. JVIM 1991; 5: 232, Jacobs et al. Am J Vet Res 1985; 46:1705							

INTERPRETED BY

R. McKenzie Daniel,
DVM, DABVP
(Canine and Feline)

IMAGING PERFORMED BY

Kerri Becker

HOSPITAL NAME

All creatures Fairfield

REFERRING VET

Dr. Perez

INVOICE

75139

DATE

5-26-26

Cardiac Presentation

The echocardiogram in this patient demonstrated normal **left atrial** size and structure. The cranial and caudal **mitral** valve leaflets presented minor irregular age-related changes that are not clinically significant at this time with adequate extension in systole and union in diastole. No overt MR or SAM. The **left ventricle** presented normal free wall and septal thicknesses with linear contour. Mildly prominent remodeled papillary muscle. The **myocardium** presented some echogenic remodeling consistent with expected age-related change. **Contractility** of the ventricular walls was adequate and in normal range for this breed and patient size. The **left ventricular outflow** tract demonstrated normal laminar flow with subjectively unremarkable structure. Normal measured LVOT velocity. Subjective assessment of the **right atrium** and auricle revealed normal size, structure and content. No evidence of masses was noted. **Tricuspid** valvular assessment demonstrated expected findings for this age patient. The **right ventricle** was of normal size (1/3 diameter of LV), echogenicity and thickness. Normal measured RVOT velocity. **Pulmonic** tract assessment revealed normal valve structure, laminar flow, and diameter (approx. 1:1 pa/ao ratio). No visible **pericardial** or free pleural fluid was noted. The **mediastinum** was free of masses in the visible window.

ULTRASONOGRAPHIC FINDINGS

- Normal cardiac structure/function with mild LV myocardial remodeling.

INTERPRETATION OF THE FINDINGS & FURTHER RECOMMENDATIONS

No evidence of clinical issues such as left or right heart chamber enlargement, LV systolic dysfunction, HCM criteria, or other structural cardiomyopathy or arrhythmia.



PATIENT

Dorian Depasquale

SPECIES

Feline

BREED

DSH

SEX

MN

AGE

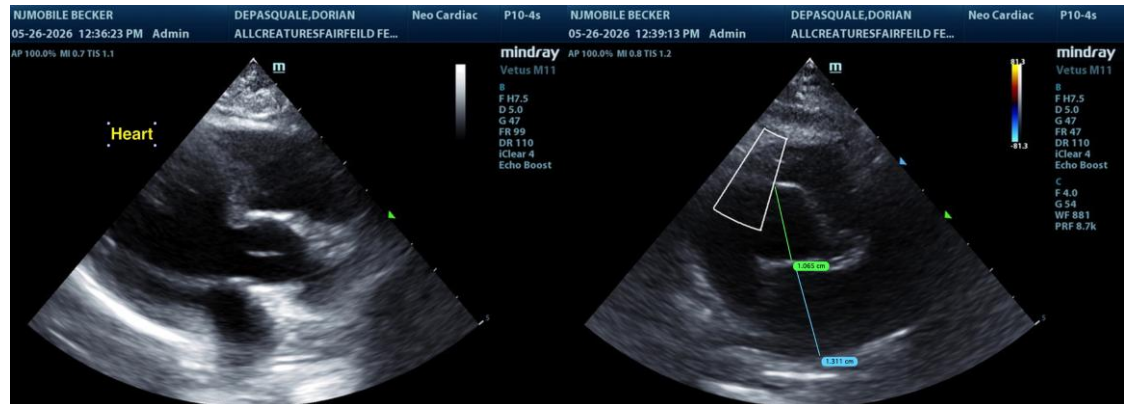
14Y

WEIGHT

10lbs

A definitive cause of the murmur was not identified. Assuming no volume changes such as dehydration or anemia, a benign flow murmur is probable. A small non-visualized flow abnormality is not excluded. Regardless of classification, the hemodynamic effects of the murmur are low. Monitoring of the heart murmur is recommended without indication for cardiac medications. Recheck echocardiogram is recommended in 6-12 months, sooner if murmur intensity increases or clinical signs arise. Anesthetic risk is considered mild. The following protocol is suggested:

Suggested anesthetic protocol may include opioid or Benzodiazepine pre-med, induction with Propofol or Alfaxalone, and appropriate gas anesthesia with avoidance of alpha 2 agonists.



INTERPRETED BY

R. McKenzie Daniel,
DVM, DABVP
(Canine and Feline)

The information and recommendations provided are based on the images presented by the referring veterinarian/sonographer. No evaluation can be communicated regarding pathology that was not visible in the image/video clips provided.

IMAGING PERFORMED BY

Kerri Becker

Thank you for this referral. If the clinical or image interpretation does not parallel your findings or if I can be of any further assistance, please contact me.

R. McKenzie Daniel, DVM, DABVP (Canine / Feline Practice)
info@sonopath.com

HOSPITAL NAME

All creatures Fairfield

REFERRING VET

Dr. Perez

INVOICE

75139

DATE

5-26-26