SonoPath
Clinical Sonography & Telecytology

EDUCATIONAL TELECONSULTATION SERVICES™

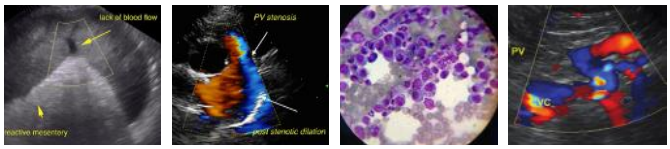

SonoPath.com
1-800-838-4268 info@sonopath.com

PATIENT
Molly Lincoln

SPECIES
Canine

BREED
Border Collie/Lab

SEX
FS

AGE
12 yr

WEIGHT
43 lb

INTERPRETED BY
R. McKenzie Daniel, DVM, DABVP (Canine and Feline)

IMAGING PERFORMED BY
Jessica Miller

HOSPITAL NAME
Livingston Animal Hospital

REFERRING VET
Dr. Messina

INVOICE
10662ag

DATE
05/25/2022

PRESENTING CLINICAL SIGNS

History: Recheck Renal Cyst Right. Current meds: Adequan, Dasuquin, Tramadol PRN, Galliprant

Last US 12/07/2021

ULTRASONOGRAPHIC RECHECK EXAMINATION OF THE ABDOMEN

Urinary System

The urinary bladder, trigone, cystourethral junction, and visible pelvic urethra to a depth of 3 cm exhibited normal thickness and tone. Anechoic urine was present in the lumen with no uroliths or sediment. The ureteral papillae were normal. The ureters were not visible which is normal. No evidence of inflammatory or neoplastic changes were noted.

Normal size and margination was present in the kidneys. A normal 1:3 cortex / medulla ratio was maintained. The medulla and cortices were uniform in texture with moderate increased echogenicity and loss of corticomedullary symmetry and definition expected for the age of the patient. No evidence of pelvic dilation was present. The left kidney exhibited a small thinly walled lateral cortical cyst containing anechoic fluid measuring 0.52 cm in diameter. The left kidney measured 6.1 cm in length. The right kidney measured 6.1 cm in length.

The area of the aortic trifurcation was free of pathology.

Adrenal Glands

The bilateral adrenal glands were normal in size. Mild parenchyma heterogeneity and mild capsule asymmetry was present without suspicion for overt neoplasia. The left adrenal gland measured 2.3 cm length and 0.56 cm width in the caudal pole. The right adrenal gland measured 2.3 cm length and 0.60 cm width in the caudal pole.

Spleen

The spleen exhibited a finely textured and homogenous parenchyma which was hyperechoic to the liver and renal cortical parenchyma. The capsule was smooth and regular without apparent expansion. The splenic vasculature at the hilus was normal in volume with no evidence of congestion or thrombosis. Acute to chronic inflammatory, neoplastic, or benign parenchyma changes were not noted.

Liver

The liver was subjectively normal in size, structure, and contour. The liver parenchyma was uniform and hypoechoic to the spleen with a mild coarse echotexture. The hepatic and portal vasculature were normal in appearance without signs of congestion. The gallbladder was non-distended in size with thin walls and primarily anechoic luminal content with mild debris. The cystic and common bile ducts were normal.

Gastrointestinal

The stomach presented intact wall layering with a normal wall layer ratio. The lumen of the stomach was empty with no signs of ileus, obstruction or foreign material.

The small intestine presented intact wall layering with 1:3 muscularis/mucosa ratio. The lumen of the small intestine was empty with no signs of ileus, obstruction or foreign material.

Normal visible colon wall layers were present with apparent formed feces in lumen.

SonoPath
Clinical Sonography & Telecytology

EDUCATIONAL TELECONSULTATION SERVICES™

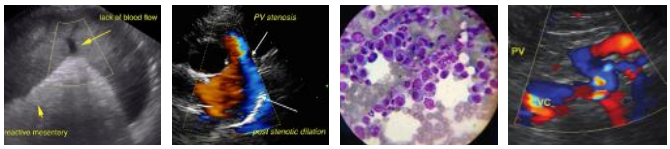

SonoPath.com
1-800-838-4268 info@sonopath.com

PATIENT

Molly Lincoln

SPECIES

Canine

BREED

Border Collie/Lab

SEX

FS

AGE

12 yr

WEIGHT

43 lb

INTERPRETED BY

R. McKenzie Daniel, DVM, DABVP (Canine and Feline)

IMAGING PERFORMED BY

Jessica Miller

HOSPITAL NAME

Livingston Animal Hospital

REFERRING VET

Dr. Messina

INVOICE

10662ag

DATE

05/25/2022

Pancreas

The parenchyma of the left limb, body and right limb of the pancreas presented isoechoic to the adjacent omental fat. A normal curvilinear capsule contour of the pancreas was present. The visible pancreatic duct was normal. No signs of active inflammation or neoplastic disease was evident.

Free Abdomen

No overt lymphadenopathy or peritoneal effusion was present.

ULTRASONOGRAPHIC FINDINGS

- Static chronic renal changes with small left kidney cortical cyst
- Otherwise overtly normal abdomen
- Mild gallbladder debris likely incidental (non-mucocele)

INTERPRETATION OF THE FINDINGS & FURTHER RECOMMENDATIONS

The left renal changes were subjectively static without evidence of recurrence of previously noted large right kidney cyst. Correlation with UA +/- C/S and baseline UPC for further renal staging could be considered if not recently done.

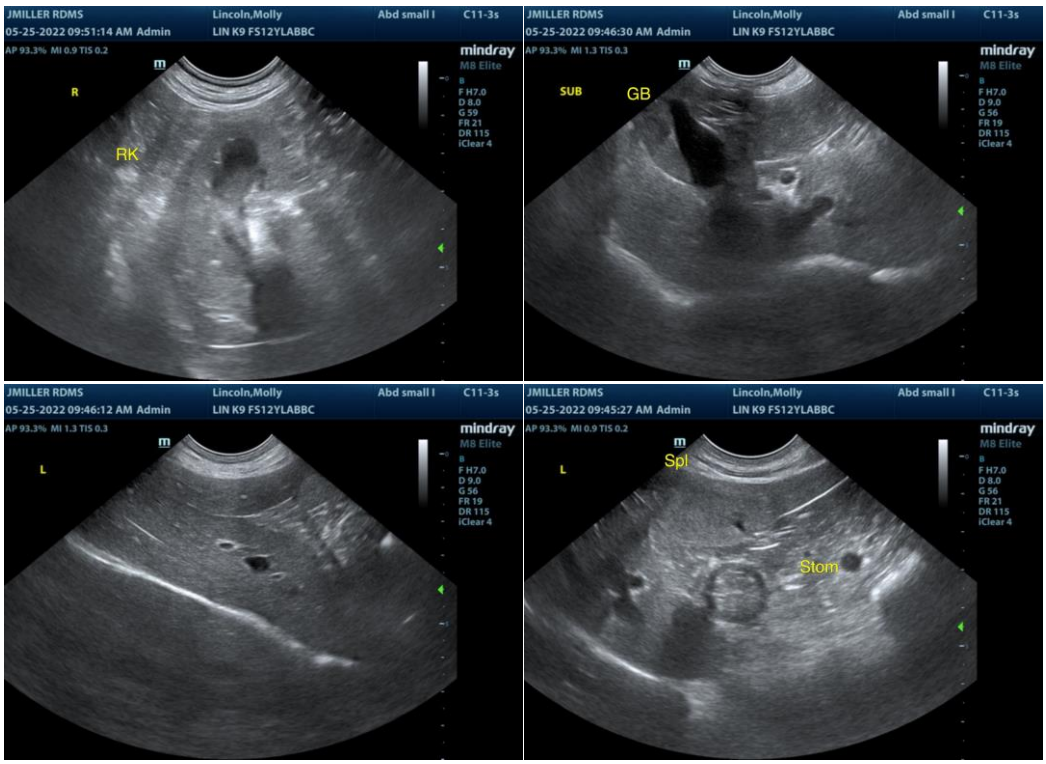

SonoPath

Clinical Sonography & Telecytology

EDUCATIONAL TELECONSULTATION SERVICES™

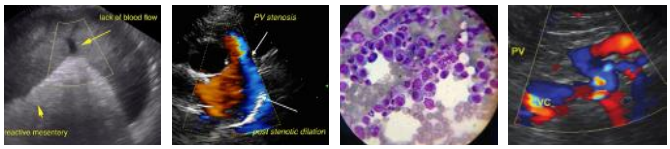

SonoPath.com

1-800-838-4268 info@sonopath.com

PATIENT

Molly Lincoln

SPECIES

Canine

BREED

Border Collie/Lab

SEX

FS

AGE

12 yr

WEIGHT

43 lb

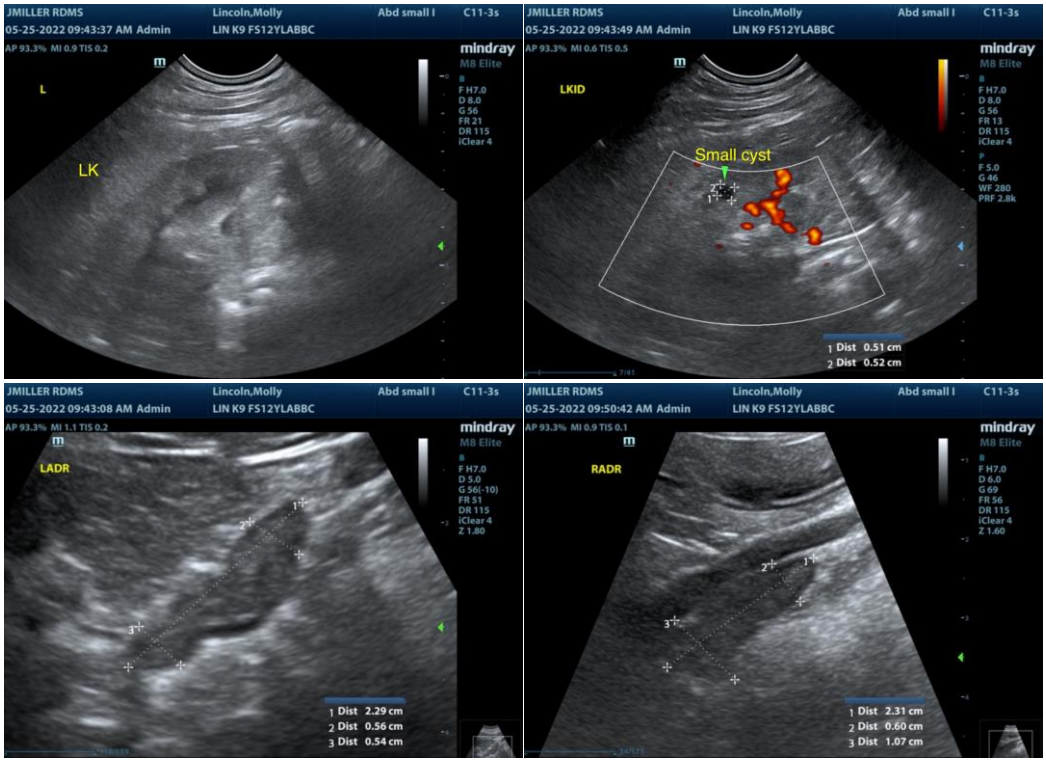

INTERPRETED BY

R. McKenzie Daniel, DVM, DABVP (Canine and Feline)

IMAGING PERFORMED BY

Jessica Miller

HOSPITAL NAME

Livingston Animal Hospital

REFERRING VET

Dr. Messina

INVOICE

10662ag

DATE

05/25/2022

The information and recommendations provided are based on the images presented by the referring veterinarian/sonographer. No evaluation can be communicated regarding pathology that was not visible in the image/video clips provided.

Thank you for this referral. If the clinical or image interpretation does not parallel your findings or if I can be of any further assistance please contact me.

R. McKenzie Daniel, DVM, DABVP (Canine / Feline Practice)

info@SonoPath.com