



PATIENT

Dagney Jakubowics

SPECIES

Feline

BREED

Dom

SEX

FS

AGE

14 years

WEIGHT

Not Provided

INTERPRETED BY

R. McKenzie Daniel,
DVM, DABVP
(Canine and Feline)

IMAGING PERFORMED BY

Jessica Miller

HOSPITAL NAME

Marsh AH

REFERRING VET

Dr Milwicki

INVOICE

13929

DATE

5/24/22

PRESENTING CLINICAL SIGNS

Hyper thyroid, Renal Disease, Litter mate passed away from cardiac issue yesterday. Current meds: Methimazole

Abnormal PE/Chem/CBC/UA Results: Chole 221, Amy 1865, Plt 43, SDMA 19.1

ULTRASONOGRAPHIC EXAMINATION OF THE HEART & ABDOMEN

FELINE CARDIAC PARAMETERS	BODY WEIGHT (kg)	HR (BPM)	IVSd (cm)	LVIDd (cm)	LVWd (cm)	FS (%)	EF (%)
NORMAL PARAMETER	-----	150-240	0.3-0.6	1.0-2.1	0.25-0.6	35-67	80-100
PATIENT		186	0.5	1.4	0.43	45.7	80.5
FELINE CARDIAC PARAMETERS	LA/AO (Boon)	LA/AO HEART BASE (Sisson)	LA 2D 4-chamber long axis AS to FW (Sisson) (cm)	LVOT VEL. (m/s)	RVOT VEL. (m/s)	IVRT (m/)	
NORMAL PARAMETER	<1.5	0.88-1.79	0.7-1.7	<1.6	<1.3	40-60	
PATIENT	1.16	1.1	1.1	1.0	0.75	NM	
Adapted from June Boon, Veterinary Echocardiography, 1998 Sisson D et al. JVIM 1991; 5: 232, Jacobs et al. Am J Vet Res 1985; 46:1705							

Cardiac Presentation

The echocardiogram in this patient demonstrated normal **left atrial** size and structure. Chamber volume and blood echogenicity were normal. The cranial and caudal **mitral** valve leaflets presented minor irregular age-related changes that are not clinically significant at this time with adequate extension in systole and union in diastole. Mild eccentric MR was present on doppler. The **left ventricle** presented normal free wall and septal thicknesses with mild alinear contour. The **myocardium** presented some myocardial remodeling expected for age. **Contractility** of the ventricular walls was adequate and in normal range for this breed and patient size. The **left ventricular outflow** tract demonstrated minor subjective dynamic to turbulent outflow, yet subjectively unremarkable structure. Subjective assessment of the **right atrium** and auricle revealed normal size, structure and content. No evidence of masses was noted. **Tricuspid** valvular assessment demonstrated expected findings for this age patient. The **right ventricle** was of normal size (1/3 diameter of LV), echogenicity and thickness. **Pulmonic** tract assessment revealed normal valve structure, laminar flow, and diameter (approx.1:1 pa/ao ratio). Minor pulmonic insufficiency was noted on doppler. No visible **pericardial** or free pleural fluid was noted. The **mediastinum** was free of masses in the visible window.

Urinary System

The urinary bladder, trigone, cystourethral junction, and visible pelvic urethra to a depth of 2.0 cm exhibited normal thickness and tone. Anechoic urine was present in the lumen with no uroliths or



PATIENT	sediment. The ureteral papillae were normal. The ureters were not visible which is normal. No evidence of inflammatory or neoplastic changes was noted.
Dagney Jakubowics	
SPECIES	The area of the aortic trifurcation was free of pathology.
Feline	Normal size and margination were present in the kidneys. A normal 1:3 cortex / medulla ratio was maintained. The medulla and cortices were uniform in texture with some increased echogenicity and moderate loss of corticomedullary symmetry and definition expected for the age of the patient. A solitary cranial cortical cyst was present in the left kidney measuring 0.6 cm diameter. No evidence of pelvic dilation was present. The left kidney measured 3.7 cm in length. The right kidney measured 3.7 cm in length.
BREED	
Dom	
SEX	
FS	
AGE	
14 years	
WEIGHT	
Not Provided	
INTERPRETED BY	
R. McKenzie Daniel, DVM, DABVP (Canine and Feline)	
IMAGING PERFORMED BY	
Jessica Miller	
HOSPITAL NAME	
Marsh AH	
REFERRING VET	
Dr Milwicki	
INVOICE	
13929	
DATE	
5/24/22	

Adrenal Glands

The bilateral adrenal glands were normal in size with symmetrical contour. Subtle nonhomogeneous left and right adrenal parenchyma were present with no evidence of mineralization. The left adrenal gland measured 0.51 width and the right adrenal gland measured 0.56 width.

Spleen

The spleen exhibited a finely textured and homogenous parenchyma which was hyperechoic to the liver and renal cortical parenchyma. The capsule was smooth and regular without apparent expansion. The splenic vasculature at the hilus was normal in volume with no evidence of congestion or thrombosis. Acute to chronic inflammatory, neoplastic, or benign parenchyma changes were not noted.

Liver/ Gallbladder

The liver was subjectively normal in size, structure, and contour. The liver parenchyma was mildly nonuniform and hypoechoic to the spleen with a moderate coarse echotexture and subjective mild to benign parenchymal remodeling. The hepatic and portal vasculature were normal in appearance without signs of congestion. The gallbladder was non-distended in size with thin walls and primarily anechoic luminal content. The cystic and common bile ducts were normal.

Gastrointestinal

The stomach presented intact wall layering with a normal wall layer ratio. Mild ingesta was present in the stomach.

The small intestine presented intact wall layering with 1:3 muscularis/mucosa ratio. The lumen of the small intestine was empty with no signs of ileus, obstruction, or foreign material.

Normal visible colon wall layers were present with apparent formed feces in lumen.

Pancreas

The pancreas was normal in size and contour with isoechoic to heterogeneous parenchyma compared to adjacent omentum. No signs of active inflammation or neoplasia.

Free Abdomen

No overt lymphadenopathy, omental masses, or peritoneal effusion were present.



PATIENT

Dagney Jakubowics

SPECIES

Feline

BREED

Dom

SEX

FS

AGE

14 years

WEIGHT

Not Provided

INTERPRETED BY

R. McKenzie Daniel,
DVM, DABVP
(Canine and Feline)

IMAGING PERFORMED BY

Jessica Miller

HOSPITAL NAME

Marsh AH

REFERRING VET

Dr Milwicki

INVOICE

13929

DATE

5/24/22

ULTRASONOGRAPHIC FINDINGS

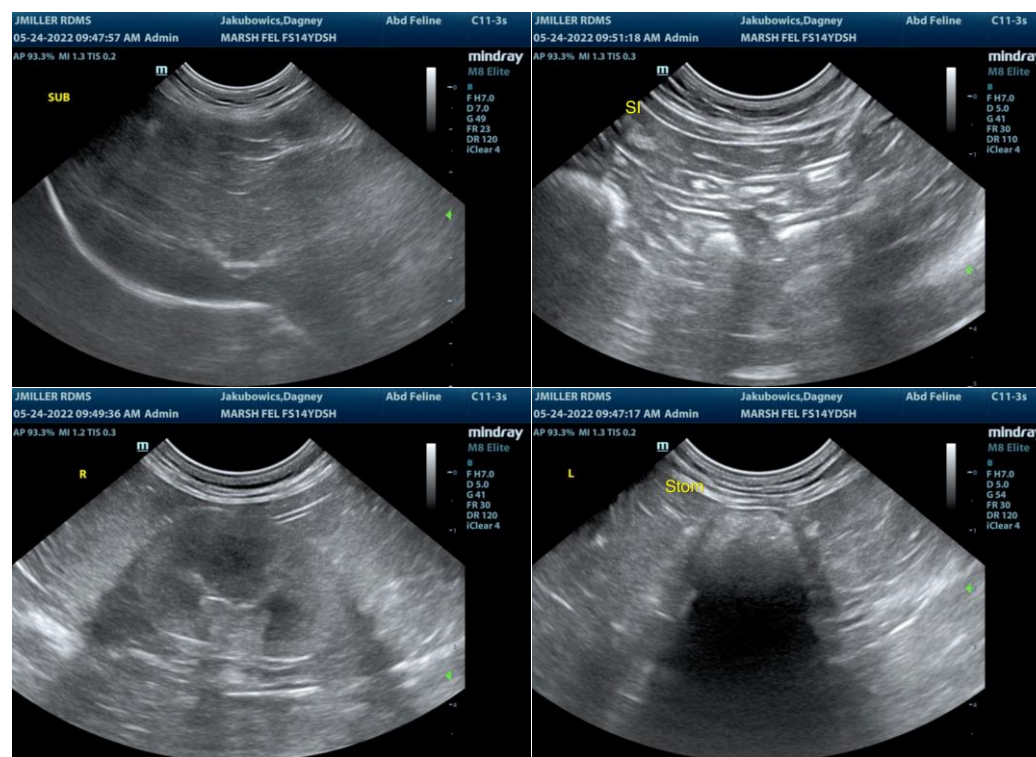
- Overtly normal cardiac structure and function for age with mild LV myocardial remodeling
- Mild MR and trace pulmonic insufficiency
- Bilateral chronic renal changes with small left kidney cortical cyst
- Mild gastric ingesta - likely recent meal ingestion

INTERPRETATION OF THE FINDINGS & FURTHER RECOMMENDATIONS

No overt evidence of structural or functional cardiomyopathy with expected age-related cardiac changes present. No clinical issues such as evidence of hypertrophic cardiomyopathy, LV systolic dysfunction, or left or right heart chamber enlargement. No indication for cardiac medications was evident. Potential for physiologic or flow murmur is possible if a murmur is noted.

No overt evidence of significant abdominal visceral pathology with mild geriatric abdominal changes was noted.

Further renal staging to include urine C/S and protein: creatinine ratio on sterile urine sample may be considered. CKD therapy with continued monitoring of renal parameters would be reasonable. Assessment of systemic blood pressure is suggested.





PATIENT

Dagney Jakubowics

SPECIES

Feline

BREED

Dom

SEX

FS

AGE

14 years

WEIGHT

Not Provided

INTERPRETED BY

R. McKenzie Daniel,
DVM, DABVP
(Canine and Feline)

IMAGING PERFORMED BY

Jessica Miller

HOSPITAL NAME

Marsh AH

REFERRING VET

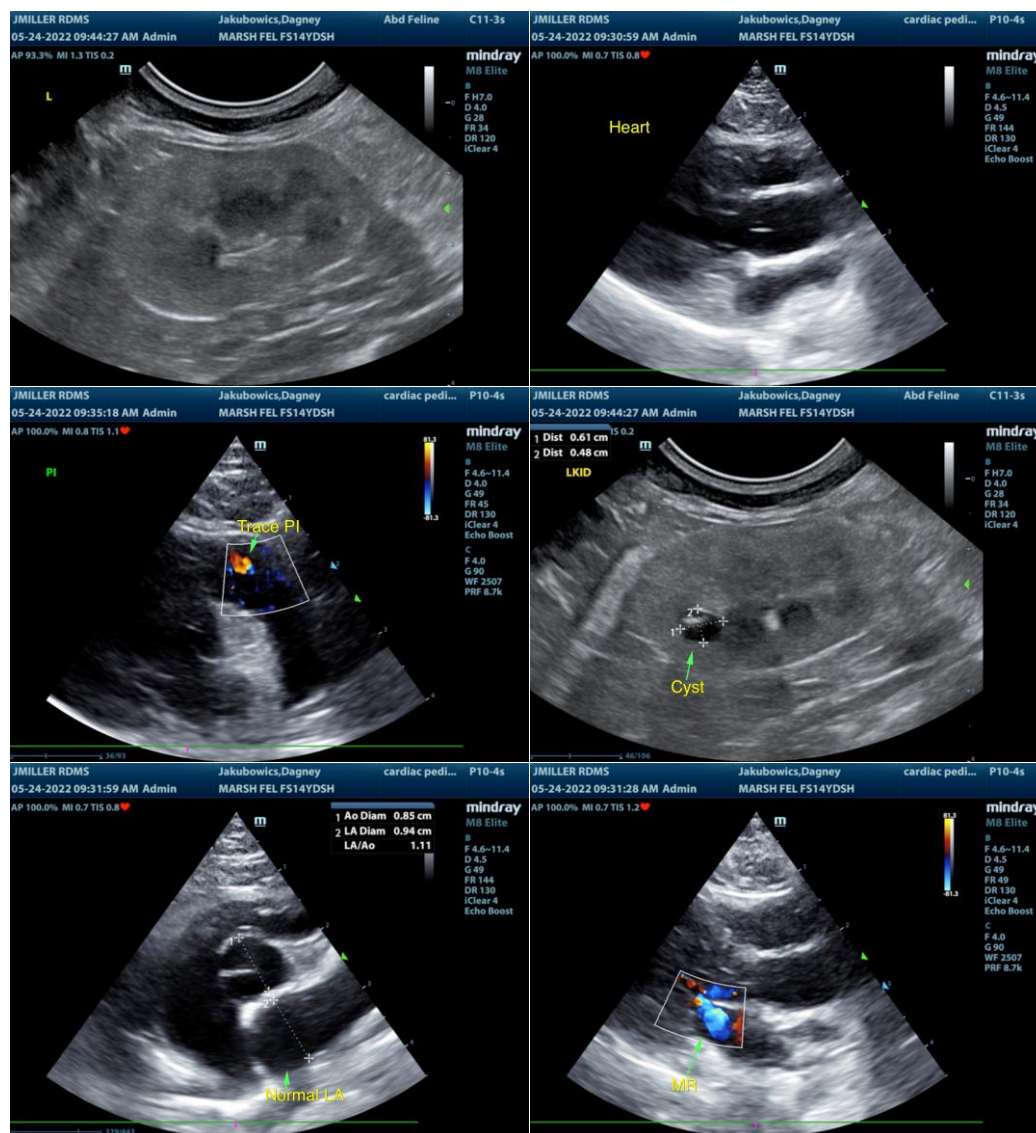
Dr Milwicki

INVOICE

13929

DATE

5/24/22



The information and recommendations provided are based on the images presented by the referring veterinarian/sonographer. No evaluation can be communicated regarding pathology that was not visible in the image/video clips provided.

Thank you for this referral. If the clinical or image interpretation does not parallel your findings or if I can be of any further assistance please contact me.

R. McKenzie Daniel, DVM, DABVP (Canine / Feline Practice)
info@SonoPath.com