

## PATIENT

Lucy Macauley/Stears

## SPECIES

Canine

## BREED

Saint Bernard

## SEX

Spayed Female

## AGE

4 Years

## WEIGHT

48 kg

## INTERPRETED BY

R. McKenzie Daniel,  
DVM, DABVP (Canine  
/ Feline Practice)

## IMAGING PERFORMED BY

Loetitia Saint-Jacques,  
LVT

## HOSPITAL NAME

Peavine Animal  
Hospital

## REFERRING VET

Dr. Morford, DVM

## INVOICE

16438

## DATE

05/22/26

## PRESENTING CLINICAL SIGNS

P presented beginning of May for urgent care. Diarrhea and vomiting. Vomiting on and off for a few days prior to appointment. Eating grass. FASTED 12 hours confirmed. MEDS- Metro 500mg BID, Cerenia 120mg SID for 4 days, Provable, Hills GI biome, Propectalin. Any additional information. Diarrhea has not resolved with therapy

Labs and Radiographs- no obvious concerns, Spec CPL neg

## ULTRASONOGRAPHIC EXAMINATION OF THE ABDOMEN

### *Urinary System*

The urinary bladder, trigone, cystourethral junction, and visible pelvic urethra to a depth of 3.0 cm exhibited normal thickness and tone. Anechoic urine was present in the lumen with no uroliths or sediment. The ureteral papillae were normal. The ureters were not visible which is normal. No evidence of inflammatory or neoplastic change were noted.

Normal size and margination was present in the left kidney with subjective mild subnormal right kidney size compared to left kidney, which is nonspecific and likely a patient variant. A normal 1:3 cortex / medulla ratio and normal corticomedullary definition were maintained. The echogenicity of the cortex was similar to or slightly less than normal liver parenchyma while the medulla echogenicity was hypoechoic to the cortex with no evidence of pelvic dilation. The left kidney measured 8.0 cm in length. The right kidney measured 7.3 cm in length.

### *Adrenal Glands*

The left adrenal gland was uniform in size and contour with a uniformly hypoechoic parenchyma. The left adrenal gland measured 0.56 cm width at the caudal pole.

The right adrenal gland was uniform in size and contour with a uniformly hypoechoic parenchyma. The right adrenal gland measured 0.64 cm width at the caudal pole.

### *Spleen*

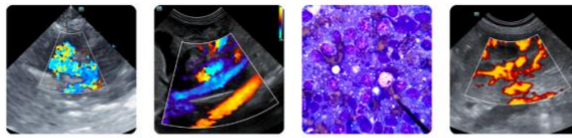
The spleen exhibited a finely textured and homogenous parenchyma which was hyperechoic to the liver and renal cortical parenchyma. The capsule was smooth and regular without apparent expansion. The splenic vasculature at the hilus was normal in volume with no evidence of congestion or thrombosis. Acute to chronic inflammatory, neoplastic, or benign parenchyma changes were not noted.

### *Liver & Gallbladder*

The liver was subjectively normal in size, structure, and contour. The liver parenchyma was uniform and hypoechoic to the spleen with a mild coarse echotexture. The hepatic and portal vasculature were normal in appearance without signs of congestion.

The gallbladder was non-distended in size with thin walls and primarily anechoic luminal content. The cystic and common bile ducts were normal.

### *Gastrointestinal*



**PATIENT**

Lucy Macauley/Steers

The stomach presented intact wall layering with a normal wall layer ratio. The lumen of the stomach contained echogenic ingesta exhibiting mild distal acoustic shadowing and lumen gas, most consistent with probable food echogenicity.

**SPECIES**

Canine

The small intestine presented intact wall layering with 1:3 muscularis/mucosa ratio. Segmental similar appearing nonshadowing ingesta and lumen gas without obstructive pattern to the level of the colon. The duodenum wall measured 0.5 cm wall width. The jejunum wall measured 0.39 cm wall width.

**BREED**

Saint Bernard

Normal visible colon wall layers were present with formed to semi formed fecal matter.

**SEX**

Spayed Female

**Pancreas**  
The area of the pancreas was sonographically normal.

**AGE**

4 Years

**Free Abdomen**

Intermittent jejunocolic nodes were present. The lymph nodes were essentially isoechoic to adjacent omentum without evidence of peripheral inflammation and maintaining a normal width: length ratio (<0.5). An example of the lymph nodes measured 2.7 cm x 1.0 cm. No evidence of peritoneal effusion.

**WEIGHT**

48 kg

**ULTRASONOGRAPHIC FINDINGS**

- Overall, structurally unremarkable gastrointestinal tract/colon with gastrointestinal ingesta and formed to semi-formed fecal matter in colon.
- Normal area of pancreas.
- Mild jejunocolic lymphadenopathy-subjective benign.
- Normal adrenal glands.

**INTERPRETED BY**

R. McKenzie Daniel,  
DVM, DABVP (Canine  
/ Feline Practice)

**INTERPRETATION OF THE FINDINGS & FURTHER RECOMMENDATIONS**

The appearance of the gastrointestinal tract is non-specific and subjectively benign with considerations including dietary intolerance / food hypersensitivity, infectious disease, dysbiosis, enterotoxin, inflammatory bowel disease, mild pancreatitis, occult parasitism, occult Addison's Disease, occult neoplasia (thought unlikely), or other.

**IMAGING PERFORMED BY**

Loetitia Saint-Jacques,  
LVT

A GI panel to include PLI/TLI/Cobalamin/Folate, fresh fecal analysis to assess for parasitic ova / Giardia and cortisol level are recommended. Empirically, a limited antigen or hydrolyzed diet trial with potential long term dietary therapy, prophylactic deworming (Panacur 50 mg/kg SID x 5 consecutive days with repeat protocol in 3 weeks even if fecal testing is negative), high colony count probiotic (Proviale or Visbiome), and as needed gastroprotectants is suggested with clinical monitoring. Note that recent research has shown that indiscriminate use of antibiotics may actually cause harm. Sonographic monitoring is indicated if persistent gastrointestinal signs. Gold standard biopsies may be required for a definitive diagnosis.

**HOSPITAL NAME**

Peavine Animal  
Hospital

**REFERRING VET**

Dr. Morford, DVM

**INVOICE**

16438

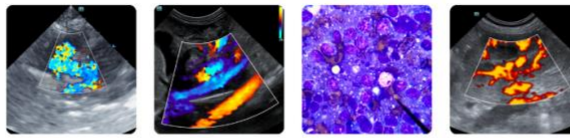
**DATE**

05/22/26

Imaging performed by



Peavine Animal Hospital, Inc.  
pawsonography@gmail.com  
530-786-8340



**Clinical Sonography & Telectology**  
Educational Teleconsultation Services™

**SonoPath**

FOSTERING THE ART OF VETERINARY MEDICINE™

SonoPath.com info@sonopath.com 1.800.838.4268

**PATIENT**

Lucy Macauley/Stears

**SPECIES**

Canine

**BREED**

Saint Bernard

**SEX**

Spayed Female

**AGE**

4 Years

**WEIGHT**

48 kg

**INTERPRETED BY**

R. McKenzie Daniel,  
DVM, DABVP (Canine  
/ Feline Practice)

**IMAGING PERFORMED BY**

Loetitia Saint-Jacques,  
LVT

**HOSPITAL NAME**

Peavine Animal  
Hospital

**REFERRING VET**

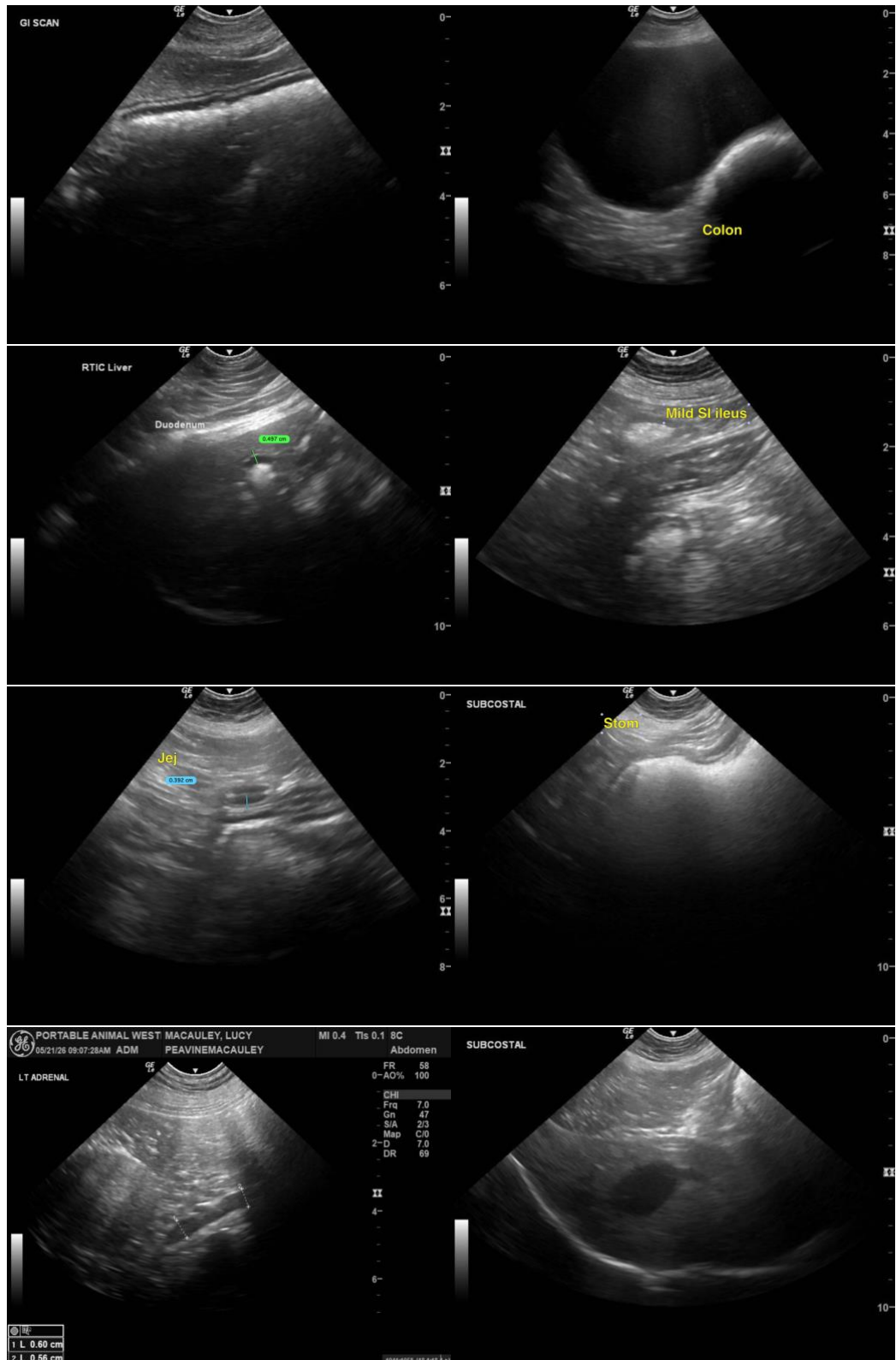
Dr. Morford, DVM

**INVOICE**

16438

**DATE**

05/22/26



Imaging performed by



Peavine Animal Hospital, Inc.  
pawsonography@gmail.com  
530-786-8340



**Clinical Sonography & Telecytology**  
Educational Teleconsultation Services™

# SonoPath

FOSTERING THE ART OF VETERINARY MEDICINE™

SonoPath.com [info@sonopath.com](mailto:info@sonopath.com) 1.800.838.4268

### PATIENT

Lucy Macauley/Stears

### SPECIES

Canine

### BREED

Saint Bernard

### SEX

Spayed Female

### AGE

4 Years

### WEIGHT

48 kg

### INTERPRETED BY

R. McKenzie Daniel,  
DVM, DABVP (Canine  
/ Feline Practice)

### IMAGING PERFORMED BY

Loetitia Saint-Jacques,  
LVT

### HOSPITAL NAME

Peavine Animal  
Hospital

### REFERRING VET

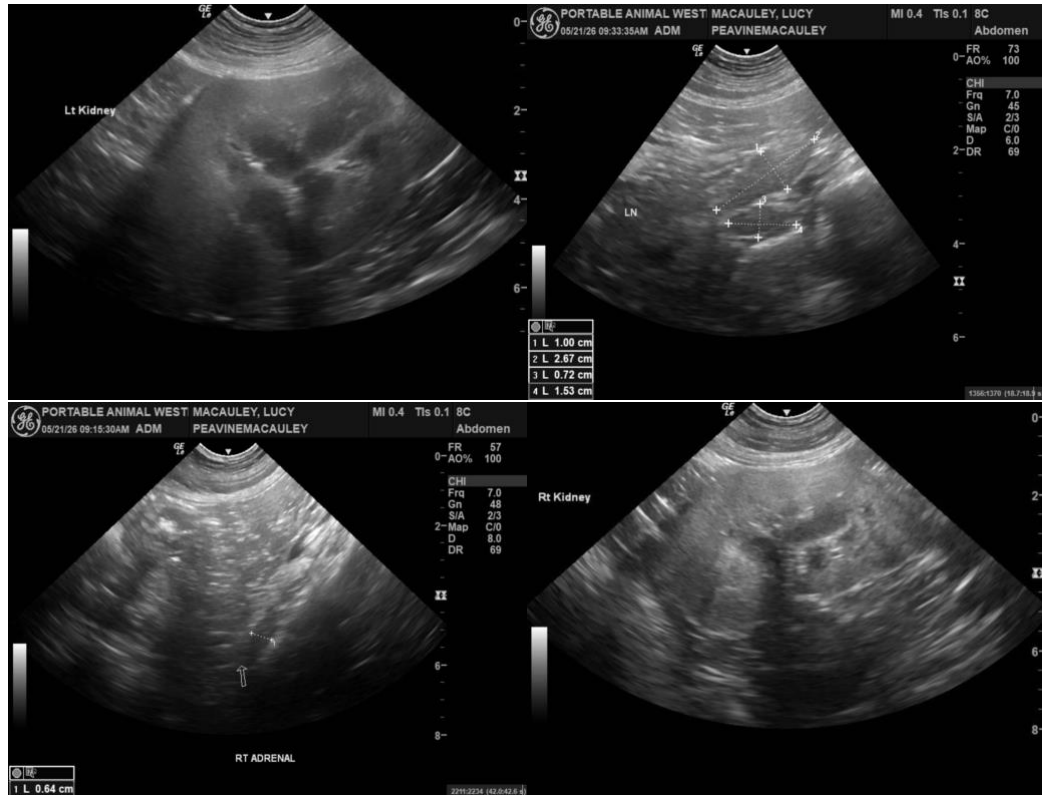
Dr. Morford, DVM

### INVOICE

16438

### DATE

05/22/26



The information and recommendations provided are based on the images presented by the referring veterinarian/sonographer. No evaluation can be communicated regarding pathology that was not visible in the image/video clips provided.

Thank you for this referral. If the clinical or image interpretation does not parallel your findings or if I can be of any further assistance, please contact me.

R. McKenzie Daniel, DVM, DABVP (Canine / Feline Practice)

[info@SonoPath.com](mailto:info@SonoPath.com)