SonoPath
Clinical Sonography & Telecytology

EDUCATIONAL TELECONSULTATION SERVICES™

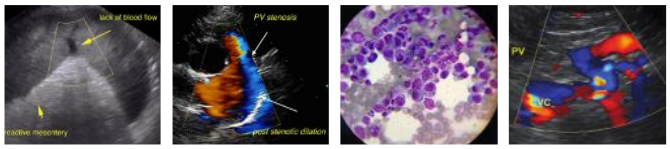

SonoPath.com
1-800-838-4268 info@sonopath.com

PATIENT
Lily Orlandi

SPECIES
Feline

BREED
DSH

SEX
Spayed Female

AGE
13 Years

WEIGHT
3.2 kg

INTERPRETED BY
R. McKenzie Daniel, DVM, DABVP (Canine and Feline)

IMAGING PERFORMED BY
Erin Wicks

HOSPITAL NAME
Shores VEC

REFERRING VET
Dr. Lupole

INVOICE
37840

DATE
5/22/22

PRESENTING CLINICAL SIGNS

Presented at our hospital for seeming weak per O and not herself. Pt had a lesion removed from R side bottom jaw on Tuesday. Last night pt not interested in food or water and has been having very large loose stools with undigested food in it. Previous Health Concerns: ionized radiation, stage 3 renal failure, weak hind end Current Medications: Dasuquin, proviable, vetosil, Cerenia, gaba, immunobast, adequan
Abnormal PE/Chem/CBC/UA Results: EPOC:BE,ECF- -7.1 L; BUN- 40 H; Creat- 3.65 H; Glu- 165 H CBC: NEU- 13.44 H; MONO- 0.05 L; MONO%- 0.3 L; PLT- 530 H CHEM: BUN- 43.9 H; Creat- 3.6 H; Glob- 4.9 H; Glu- 163 H; AMY- 1511 H

ULTRASONOGRAPHIC EXAMINATION OF THE ABDOMEN

Urinary System

The urinary bladder, trigone, cystourethral junction, and visible pelvic urethra to a depth of 2.0 cm exhibited normal thickness and tone. Anechoic urine was present in the lumen with no uroliths or sediment. The ureteral papillae were normal. The ureters were not visible which is normal. No evidence of inflammatory or neoplastic changes were noted.

Normal size and margination were present in the kidneys. A normal 1:3 cortex / medulla ratio was maintained. The medulla and cortices were uniform in texture with some increased echogenicity and moderate loss of corticomedullary symmetry and definition expected for the age of the patient. No evidence of pelvic dilation was present. The left kidney measured 3.2 cm. The right kidney measured 3.3 cm.

The area of the aortic trifurcation was free of pathology.

Adrenal Glands

The adrenal glands were uniform in size and contour with a uniformly hypoechoic parenchyma. The left adrenal gland measured 0.25 cm. The right adrenal gland measured 0.35 cm.

Spleen

The spleen exhibited a finely textured and homogenous parenchyma which was hyperechoic to the liver and renal cortical parenchyma. The capsule was smooth and regular without apparent expansion. The splenic vasculature at the hilus was normal in volume with no evidence of congestion or thrombosis. Acute to chronic inflammatory, neoplastic, or benign parenchyma changes were not noted.

Liver

The liver was subjectively normal in size, structure, and contour. The liver parenchyma was uniform and hypoechoic to the spleen with a mild coarse echotexture. The hepatic and portal vasculature were normal in appearance without signs of congestion. The gallbladder was non-distended in size with thin walls and primarily anechoic luminal content. The cystic and common bile ducts were normal.

Gastrointestinal

The stomach presented intact wall layering with a normal wall layer ratio. The lumen of the stomach was empty with no signs of ileus, obstruction or foreign material. Gastric body wall measured 0.25 cm.

The small intestine presented intact wall layering with altered muscularis/mucosa ratio secondary to generalized mildly prominent muscularis layer. The lumen of the small intestine was empty with no signs

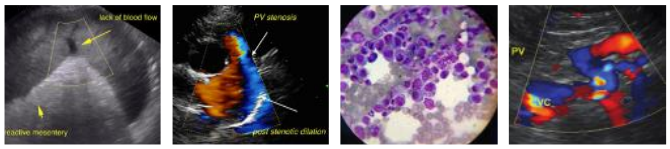

SonoPath.com
1-800-838-4268 info@sonopath.com

PATIENT
Lily Orlandi

SPECIES
Feline

BREED
DSH

SEX
Spayed Female

AGE
13 Years

WEIGHT
3.2 kg

INTERPRETED BY
R. McKenzie Daniel, DVM, DABVP (Canine and Feline)

IMAGING PERFORMED BY
Erin Wicks

HOSPITAL NAME
Shores VEC

REFERRING VET
Dr. Lupole

INVOICE
37840

DATE
5/22/22

of ileus, obstruction or foreign material. Jejunum wall measured up to 0.33 cm. Potential segmental indistinct jejunal wall layering possible, yet not definitive. No overt evidence of intestinal masses.

The visualized colon exhibited sonographically unremarkable wall layering with subjective semiformed to soft feces present in the lumen.

Pancreas

The parenchyma of the left limb, body and right limb of the pancreas presented isoechoic to the adjacent omental fat. A normal curvilinear capsule contour of the pancreas was present. The visible pancreatic duct was normal. No signs of active inflammation or neoplastic disease was evident.

Free Abdomen

No omental masses, significant lymphadenopathy, or evidence of peritoneal effusion.

ULTRASONOGRAPHIC FINDINGS

- Moderate chronic kidneys.
- Infiltrative enteropathy – suspect IBD/eosinophilic enteritis, low-grade neoplastic enteropathy (i.e., lymphoma) possible, yet thought less likely.
- Normal colon with semiformed feces.
- Overtly normal pancreas.

INTERPRETATION OF THE FINDINGS & FURTHER RECOMMENDATIONS

The appearance of the bilateral kidneys is sonographically consistent with Iris Stage 3 CKD. The bilateral kidneys did not appear to be end stage. Further renal staging to include urine C/S and protein: creatinine ratio on sterile urine sample may be considered. Assessment of systemic BP recommended.

A GI panel to include PLI/TLI/Cobalamin/Folate is recommended. Low-grade pancreatitis, which can present normal and often seen with intestinal disease, cannot be excluded. Full thickness intestinal biopsies likely required for definitive diagnosis. Empirical IBD protocol could be considered if clinically indicated (i.e., evidence of IBD signs, weight loss, etc.).

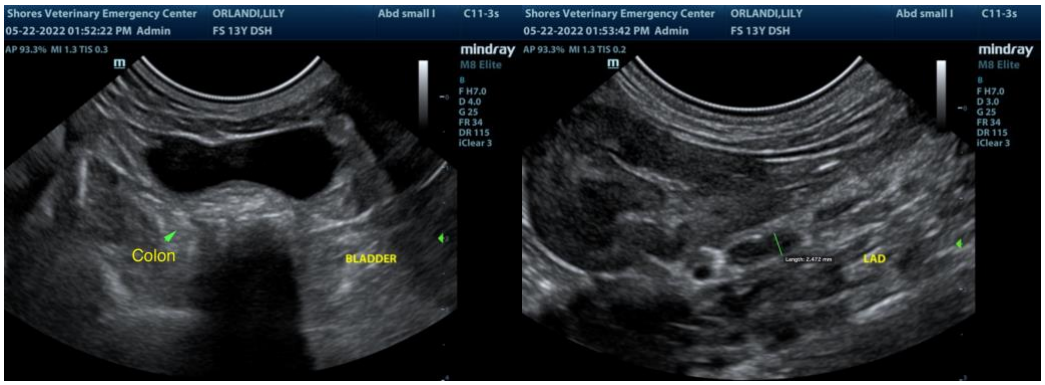

SonoPath

Clinical Sonography & Telecytology

EDUCATIONAL TELECONSULTATION SERVICES™

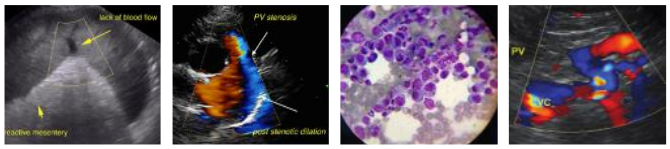

SonoPath.com
1-800-838-4268 info@sonopath.com

PATIENT

Lily Orlandi

SPECIES

Feline

BREED

DSH

SEX

Spayed Female

AGE

13 Years

WEIGHT

3.2 kg

INTERPRETED BY

R. McKenzie Daniel, DVM, DABVP (Canine and Feline)

IMAGING PERFORMED BY

Erin Wicks

HOSPITAL NAME

Shores VEC

REFERRING VET

Dr. Lupole

INVOICE

37840

DATE

5/22/22

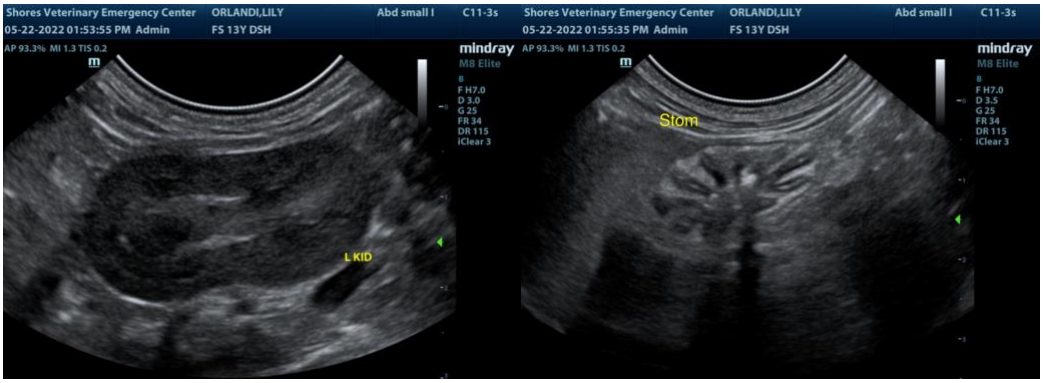

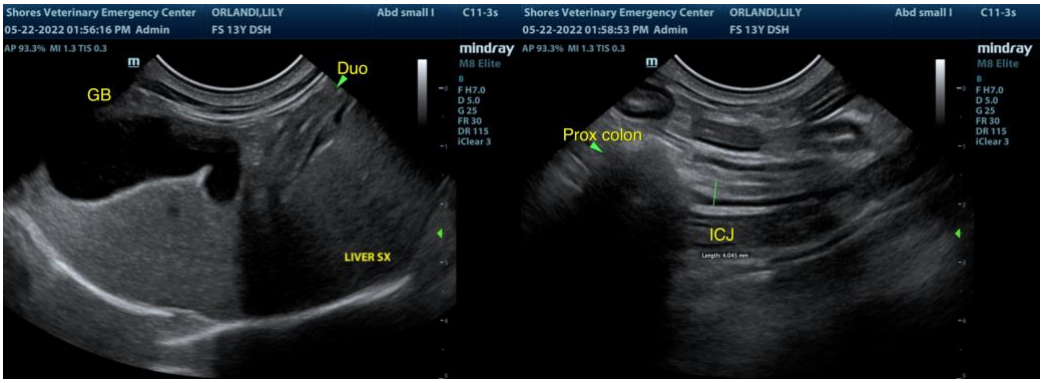

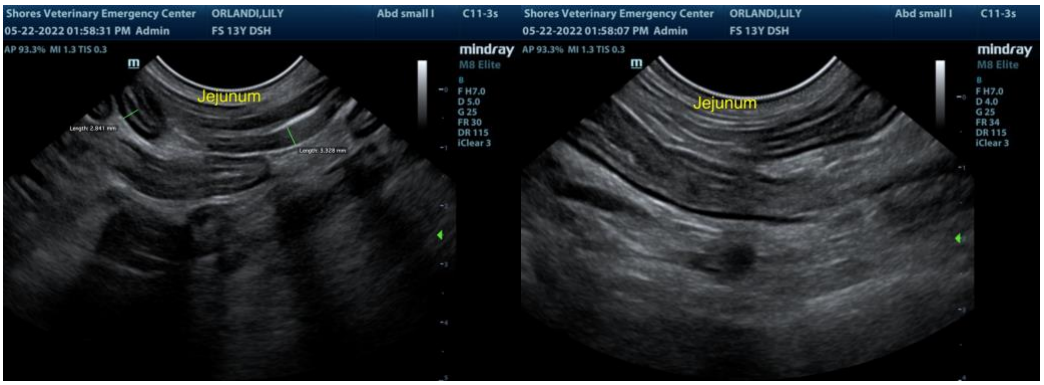

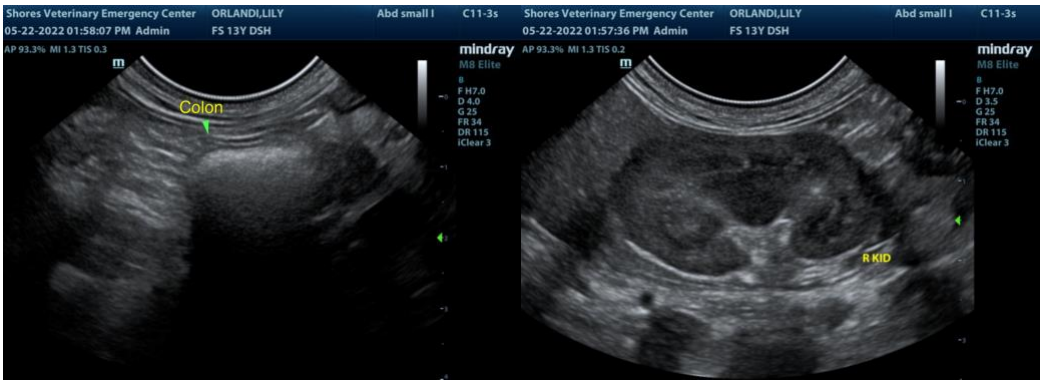

SonoPath

Clinical Sonography & Telecytology

EDUCATIONAL TELECONSULTATION SERVICES™

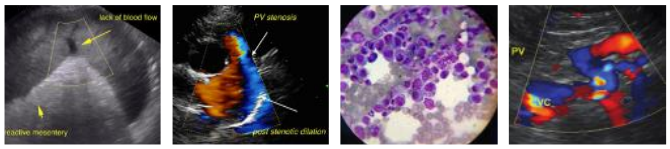

SonoPath.com™
1-800-838-4268 info@sonopath.com

PATIENT

Lily Orlandi

SPECIES

Feline

BREED

DSH

SEX

Spayed Female

AGE

13 Years

WEIGHT

3.2 kg

INTERPRETED BY

R. McKenzie Daniel, DVM, DABVP (Canine and Feline)

IMAGING PERFORMED BY

Erin Wicks

HOSPITAL NAME

Shores VEC

REFERRING VET

Dr. Lupole

INVOICE

37840

DATE

5/22/22

The information and recommendations provided are based on the images presented by the referring veterinarian/sonographer. No evaluation can be communicated regarding pathology that was not visible in the image/video clips provided.

Thank you for this referral. If the clinical or image interpretation does not parallel your findings or if I can be of any further assistance please contact me.

R. McKenzie Daniel, DVM, DABVP (Canine / Feline Practice)

info@SonoPath.com