



PATIENT	PRESENTING CLINICAL SIGNS
Shady Toenniges	Vomiting every 2hrs since last night. Diarrhea. Abnormal PE/Chem/CBC/UA Results: Chest rads WNL. Glob: 5.1, Chol: 342, T4<0.5.
SPECIES	ULTRASONOGRAPHIC EXAMINATION OF THE ABDOMEN
Canine	Urinary System
BREED	The urinary bladder, trigone, cystourethral junction, and visible pelvic urethra to a depth of – cm exhibited normal thickness and tone. Anechoic urine was present in the lumen with no uroliths or sediment. The ureteral papillae were normal. The ureters were not visible which is normal. No evidence of inflammatory or neoplastic changes were noted.
Shepherd X	
SEX	No overt pathology in the area of the residual prostate.
Neutered Male	Normal size and margination were present in the kidneys. A normal 1:3 cortex / medulla ratio was maintained. The medulla and cortices were uniform in texture with some increased echogenicity and loss of corticomedullary symmetry and definition expected for the age of the patient. No evidence of pelvic dilation was present. The right kidney measured 6.5 cm. The left kidney measured 7.2 cm.
AGE	The area of the aortic trifurcation was free of pathology. No evidence of medial iliac or sublumbar lymphadenopathy.
11 Years	
WEIGHT	Adrenal Glands
68 Pounds	The adrenal glands were uniform in size and contour with a uniformly hypoechoic parenchyma. The left adrenal gland measured 3.1 cm length x 0.90 cm. The right adrenal gland measured 2.5 cm length x 0.72 cm at the caudal pole.
INTERPRETED BY	Spleen
R. McKenzie Daniel, DVM, DABVP (Canine and Feline)	The spleen exhibited primarily finely textured parenchyma which was hyperechoic to the liver and renal cortical parenchyma. Mild generalized parenchyma heterogeneity was present without evidence of nodular changes. The capsule was smooth and regular without apparent expansion. The splenic vasculature at the hilus was normal in volume with no evidence of congestion or thrombosis. The parenchymal heterogeneity is likely consistent with benign changes such as extramedullary hematopoiesis or age related remodeling with minor potential for inflammatory or neoplastic disease.
IMAGING PERFORMED BY	Liver
Dr. Rodriguez	The liver exhibited subjective enlargement with symmetrical to mildly swollen contour. The hepatic parenchyma revealed diffuse reduced echogenicity compared to the spleen and renal cortical parenchyma with a mild coarse echotexture. Increased portal vein prominence was evident.. Distinct masses or nodules were not evident. The hepatic and portal vasculature were normal in appearance. The gallbladder was non-distended in size with primarily anechoic luminal content. The cystic and common bile ducts were normal.
HOSPITAL NAME	Gastrointestinal
Foxfield Vet Services	The stomach presented intact wall layering with a normal wall layer ratio. The lumen of the stomach was empty with no signs of ileus, obstruction or foreign material.
REFERRING VET	The small intestine presented primarily intact wall layering with altered wall layer ratio owing to variably prominent mucosa, submucosa and muscularis layers. A moderately sized expansive mass appearing to originate from unspecified intestinal segment was noted measuring approximately 6-7 cm in diameter.
Dr. Rodriguez	
INVOICE	
37834	
DATE	
5/21/22	



PATIENT

Shady Toenniges

The mass was asymmetrically margined, exhibiting non-homogeneous to mixed echogenic parenchyma.

The colon walls presented intact yet prominent wall layering with mild thickened to echogenic submucosa. Nonformed feces present, consistent with reported diarrhea.

SPECIES

Canine

Pancreas

The pancreas was not overtly visualized owing to regional peripancreatic increased omental artifact.

BREED

Shepherd X

Free Abdomen

Regional to generalized mildly non-uniform hyperechoic mesentery, primarily around the intestinal mass, was noted, along with mild volume free fluid exhibiting mild subjective echogenic changes consistent with likely cellular component.

SEX

Neutered Male

PRIMARY FINDINGS

- Diffuse infiltrative enteropathy with a moderately sized, expansive, non-homogeneous intestinal mass.
- Associated peritonitis.
- Hepatomegaly exhibiting parenchyma hypoechogenicity.

AGE

11 Years

SECONDARY FINDINGS

- Bilateral mild chronic renal changes.
- Age related splenic changes.

WEIGHT

68 Pounds

INTERPRETATION OF THE FINDINGS & FURTHER RECOMMENDATIONS

Although sampling is required for further assessment, the intestinal mass as well as the likely generalized small intestine is consistent with neoplastic criteria. Potential for non-neoplastic etiology (i.e., severe inflammatory or granulomatous disease) possible yet thought less likely. Assuming normal clotting status, ultrasound guided FNA of the intestinal mass as well as screening FNA of the liver using 25-gauge needle recommended for screening cytology.

The extent of potential small intestinal involvement was difficult to ascertain. Likewise, concern for regional omental seeding around the intestinal mass as with carcinomatosis, lymphomatosis or similar warranted, yet not definitive. Unfortunately, an unfavorable prognosis is likely indicated.

INTERPRETED BY

R. McKenzie Daniel,
DVM, DABVP
(Canine and Feline)

IMAGING PERFORMED BY

Dr. Rodriguez

HOSPITAL NAME

Foxfield Vet Services

REFERRING VET

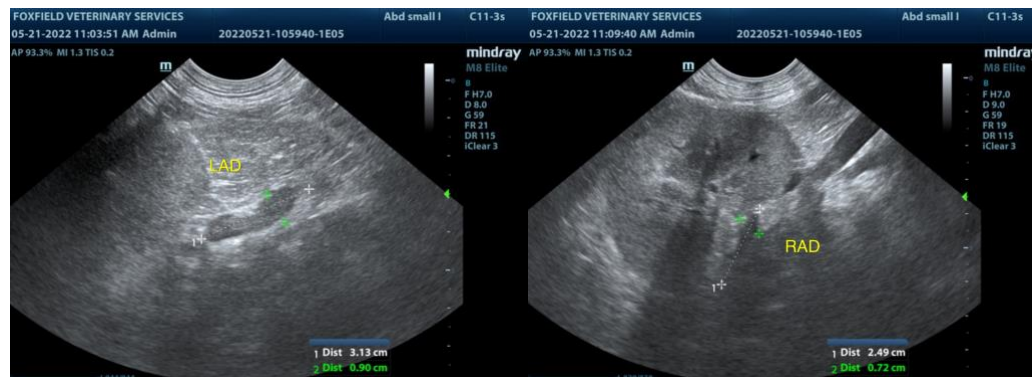
Dr. Rodriguez

INVOICE

37834

DATE

5/21/22





PATIENT

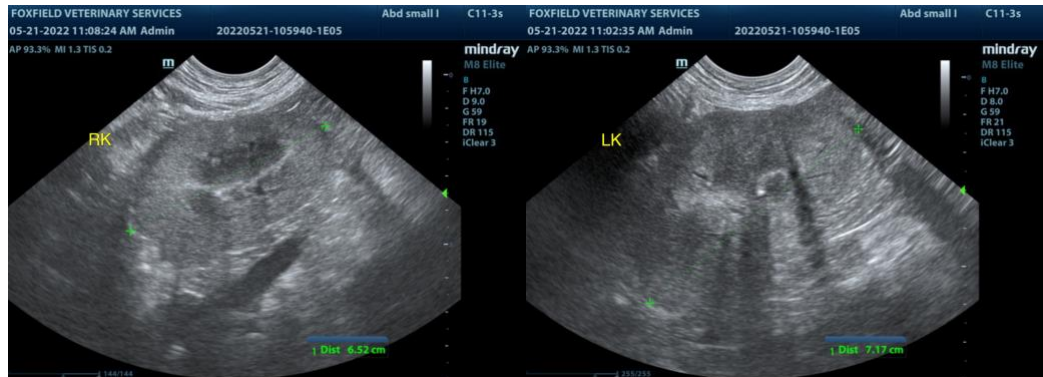
Shady Toenniges

SPECIES

Canine

BREED

Shepherd X



SEX

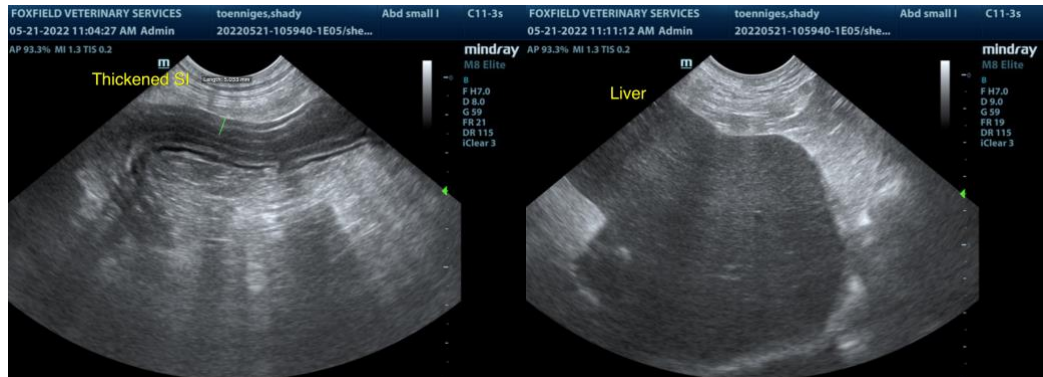
Neutered Male

AGE

11 Years

WEIGHT

68 Pounds

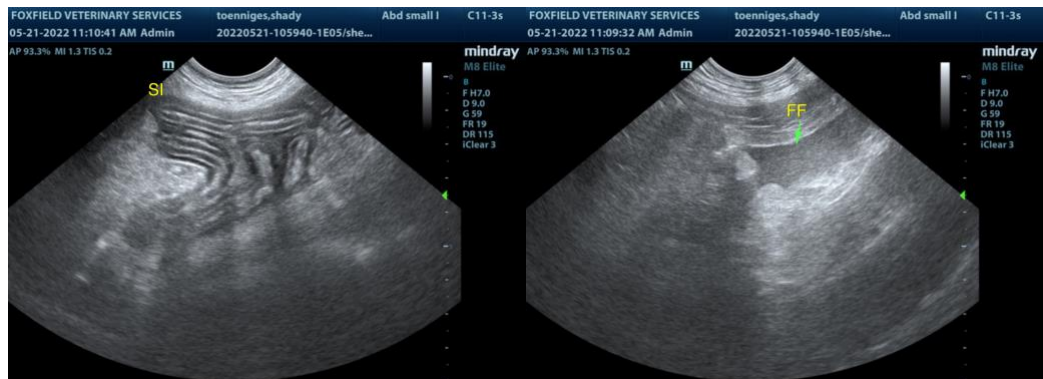


INTERPRETED BY

R. McKenzie Daniel,
DVM, DABVP
(Canine and Feline)

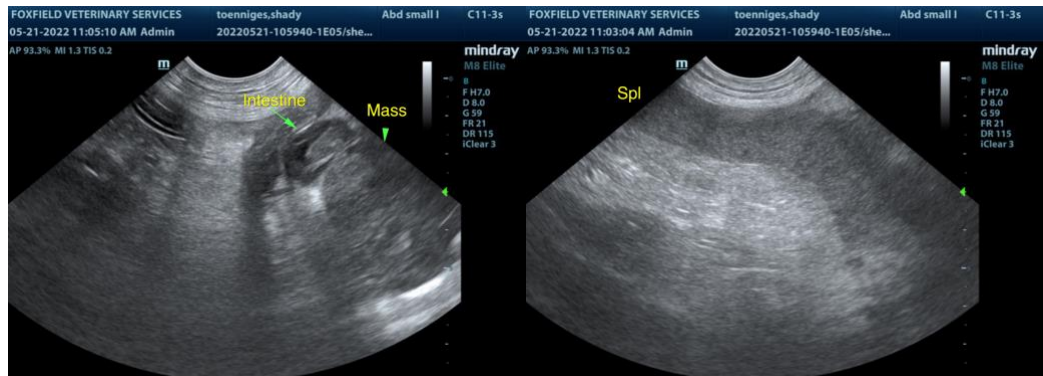
IMAGING PERFORMED BY

Dr. Rodriguez



HOSPITAL NAME

Foxfield Vet Services



REFERRING VET

Dr. Rodriguez

INVOICE

37834

DATE

5/21/22



PATIENT

Shady Toenniges

SPECIES

Canine

BREED

Shepherd X

SEX

Neutered Male

AGE

11 Years

WEIGHT

68 Pounds

INTERPRETED BY

R. McKenzie Daniel,
DVM, DABVP
(Canine and Feline)

**IMAGING
PERFORMED BY**

Dr. Rodriguez

HOSPITAL NAME

Foxfield Vet Services

REFERRING VET

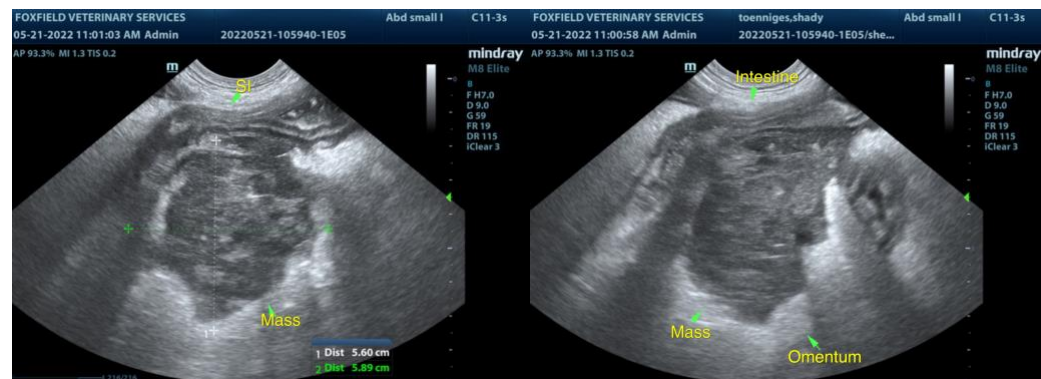
Dr. Rodriguez

INVOICE

37834

DATE

5/21/22



The information and recommendations provided are based on the images presented by the referring veterinarian/sonographer. No evaluation can be communicated regarding pathology that was not visible in the image/video clips provided.

Thank you for this referral. If the clinical or image interpretation does not parallel your findings or if I can be of any further assistance please contact me.

R. McKenzie Daniel, DVM, DABVP (Canine / Feline Practice)

info@SonoPath.com