

PATIENT

Delialah Fancy

SPECIES

Feline

BREED

DSH

SEX

Female Spayed

AGE

4 years, 9 months

WEIGHT

19.6 lbs.

INTERPRETED BY

R. McKenzie Daniel,
DVM, DABVP
(Canine and Feline)

IMAGING PERFORMED BY

Dr. Shark

HOSPITAL NAME

Kew Gardens AH

REFERRING VET

Dr. Shark

INVOICE

10902

DATE

5/20/26

PRESENTING CLINICAL SIGNS

heart murmur grade 3-4/6.

ULTRASONOGRAPHIC EXAMINATION OF THE HEART

FELINE CARDIAC PARAMETERS	BODY WEIGHT	HR (BPM)	IVSd (cm)	LVIDd (cm)	LVWd (cm)	FS (%)	EF (%)
NORMAL PARAMETER	-----	150-240	0.3-0.6	1.0-2.1	0.25-0.6	35-67	80-100
PATIENT	19.6 lbs.	NM	0.51	10.2	0.57	50	82
FELINE CARDIAC PARAMETERS	LA/AO (M-mode)	LA/AO HEART BASE (Sisson)	LAD LA MAX 4 Chamber		LVOT VEL. (m/s)	RVOT VEL. (m/s)	IVRT (m/)
NORMAL PARAMETER	<1.5	1.6	0.7-1.7		<1.6	<1.3	40-60
PATIENT	-	1.4	1.35		-	0.92	-
Adapted from June Boon, Veterinary Echocardiography, 1998							
Sisson D et al. JVIM 1991; 5: 232, Jacobs et al. Am J Vet Res 1985; 46:1705							

Cardiac Presentation

The echocardiogram in this patient demonstrated normal **left atrial** size based on 3 separate LA measurements. The cranial and caudal **mitral** valve leaflets presented normal linear structure and kinetics. The **left ventricle** presented normal thicknesses with linear contour and was not dilated nor restricted. The **myocardium** presented normal echogenicity without subjective evidence of significant fibrotic or ischemic disease. **Contractility** of the ventricular walls was adequate and in normal range for this patient evidenced by the fractional shortening measurement and subjective evaluation of the different regions and angles of the myocardium. The **left ventricular outflow** tract demonstrated normal laminar flow and subjective structural integrity. The **right atrium** and auricle revealed normal size, structure and content. No evidence of masses was noted or chamber overload. **Tricuspid** valvular assessment demonstrated adequate linear morphology and kinetics. The **right ventricle** was of normal size (1/3 diameter of LV), chordae structure, myocardial echogenicity and thickness. **Pulmonic** tract assessment revealed normal valve structure, laminar flow, and diameter (approx. 1:1 pa/ao ratio). No visible **pericardial** or free pleura fluid was noted or extra cardiac pathology in the visible planes. The cranial **mediastinum and pericardial regions** were free of masses in the visible window.

ULTRASONOGRAPHIC FINDINGS

- Normal cardiac structure / function



PATIENT

Delialah Fancy

SPECIES

Feline

BREED

DSH

SEX

Female Spayed

AGE

4 years, 9 months

WEIGHT

19.6 lbs.

INTERPRETED BY

R. McKenzie Daniel,
DVM, DABVP
(Canine and Feline)

IMAGING PERFORMED BY

Dr. Shark

HOSPITAL NAME

Kew Gardens AH

REFERRING VET

Dr. Shark

INVOICE

10902

DATE

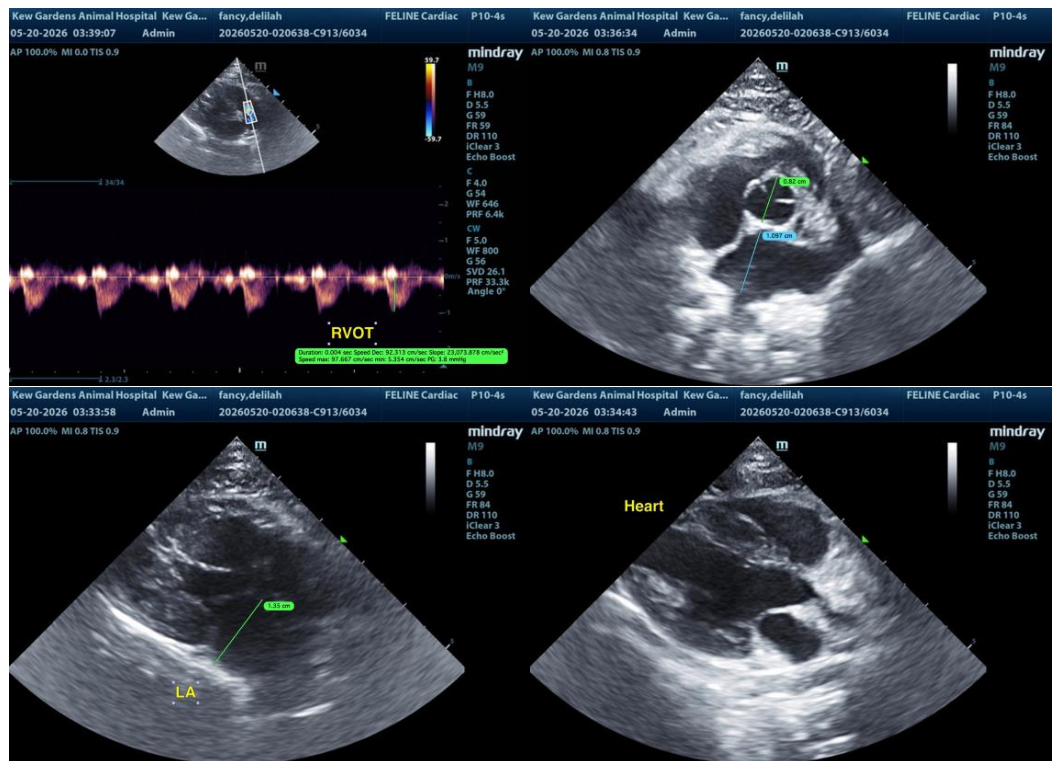
5/20/26

INTERPRETATION OF THE FINDINGS & FURTHER RECOMMENDATIONS

There is no evidence of clinical issues such as left or right heart chamber enlargement, LV systolic dysfunction, pulmonary hypertension, or arrhythmia.

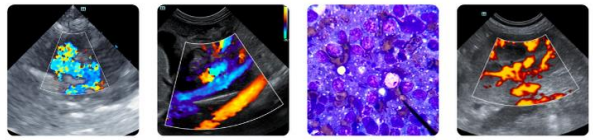
A definitive cause of the murmur was not identified. Assuming no volume changes such as dehydration or anemia, a benign flow murmur is probable. A small, non-visualized flow abnormality is not excluded. Regardless of classification, the hemodynamic effects of the murmur are low. Monitoring of the heart murmur is recommended without indication for cardiac medications. Recheck echocardiogram is recommended in 6-12 months, sooner if murmur intensity increases or clinical signs arise. Cardiac anesthetic risk is considered low to mild. If required, the following protocol is suggested.

Suggested anesthetic protocol may include opioid or Benzodiazepine pre-med, induction with Propofol or Alfaxalone, and appropriate gas anesthesia with avoidance of alpha 2 agonists.



The information and recommendations provided are based on the images presented by the referring veterinarian/sonographer. No evaluation can be communicated regarding pathology that was not visible in the image/video clips provided.

Thank you for this referral. If the clinical or image interpretation does not parallel your findings or if I can be of any further assistance please contact me.



PATIENT

Delialah Fancy

R. McKenzie Daniel, DVM, DABVP (Canine/Feline Practice)

info@sonopath.com

SPECIES

Feline

BREED

DSH

SEX

Female Spayed

AGE

4 years, 9 months

WEIGHT

19.6 lbs.

INTERPRETED BY

R. McKenzie Daniel,
DVM, DABVP
(Canine and Feline)

IMAGING PERFORMED BY

Dr. Shark

HOSPITAL NAME

Kew Gardens AH

REFERRING VET

Dr. Shark

INVOICE

10902

DATE

5/20/26