



PATIENT

Sandie Conyers

SPECIES

Canine

BREED

Chihuahua X

SEX

Spayed Female

AGE

7.5 Years

WEIGHT

12.3 Pounds

INTERPRETED BY

R. McKenzie Daniel,
DVM, DABVP
(Canine and Feline)

IMAGING PERFORMED BY

Emily Kirk

HOSPITAL NAME

Shiloh Vet Hospital

REFERRING VET

Dr. Audra Alley

INVOICE

37823

DATE

5/20/22

PRESENTING CLINICAL SIGNS

1 week ago presented for vomiting episodes. PE was WNL. Cerenia and Low fat EN given, dog did ok for 1 week. 5/19 had vomiting spell again.
Abnormal PE/Chem/CBC/UA Results: See attached. Lab work overall unremarkable.

ULTRASONOGRAPHIC EXAMINATION OF THE ABDOMEN

Urinary System

The urinary bladder, trigone, cystourethral junction, and visible pelvic urethra to a depth of – cm exhibited normal thickness and tone. Anechoic urine was present in the lumen with no uroliths or sediment. The ureteral papillae were normal. The ureters were not visible which is normal. No evidence of inflammatory or neoplastic changes were noted.

Normal size and margination were present in the kidneys. A normal 1:3 cortex / medulla ratio and normal corticomedullary definition were maintained. The echogenicity of the cortex was similar to or slightly less than normal liver parenchyma while the medulla echogenicity was hypoechoic to the cortex with no evidence of pelvic dilation. The kidneys measured 3.8 cm each.

Adrenal Glands

The adrenal glands were uniform in size and contour with a uniformly hypoechoic parenchyma. The left adrenal gland measured 0.45 cm in width. The right adrenal gland measured 0.52 cm at the cranial pole and 0.47 cm at the caudal pole.

Spleen

The spleen exhibited a finely textured and homogenous parenchyma which was hyperechoic to the liver and renal cortical parenchyma. The capsule was smooth and regular without apparent expansion. The splenic vasculature at the hilus was normal in volume with no evidence of congestion or thrombosis. Acute to chronic inflammatory, neoplastic, or benign parenchyma changes were not noted.

Liver

The liver was subjectively normal in size, structure, and contour. The liver parenchyma was uniform and hypoechoic to the spleen with a mild coarse echotexture. The hepatic and portal vasculature were normal in appearance without signs of congestion. The gallbladder was non distended in size with mild, non-dependent yet non-organized biliary sludge. The cystic duct and common bile ducts were normal without evidence of dilation.

Gastrointestinal

The stomach presented intact yet subjective mild prominent wall layering for patient size. The stomach was primarily empty with minor retained fluid and chyme along with luminal gas. Gastric body wall measured 0.33 cm.

The small intestine presented intact wall layering with primarily maintained 1:3 muscularis/mucosa ratio with propensity for mild generalized prominent mucosa. Duodenum wall measured 0.45 cm. Jejunum wall measured 0.28 cm.

Normal visible colon wall layers were present with semiformal to soft feces.



PATIENT

Sandie Conyers

SPECIES

Canine

BREED

Chihuahua X

SEX

Spayed Female

AGE

7.5 Years

WEIGHT

12.3 Pounds

INTERPRETED BY

R. McKenzie Daniel,
DVM, DABVP
(Canine and Feline)

IMAGING PERFORMED BY

Emily Kirk

HOSPITAL NAME

Shiloh Vet Hospital

REFERRING VET

Dr. Audra Alley

INVOICE

37823

DATE

5/20/22

Pancreas

The parenchyma of the left limb, body and right limb of the pancreas presented isoechoic to the adjacent omental fat. A normal curvilinear capsule contour of the pancreas was present. The visible pancreatic duct was normal. No signs of active inflammation or neoplastic disease was evident.

Free Abdomen

No overt lymphadenopathy or peritoneal effusion was present.

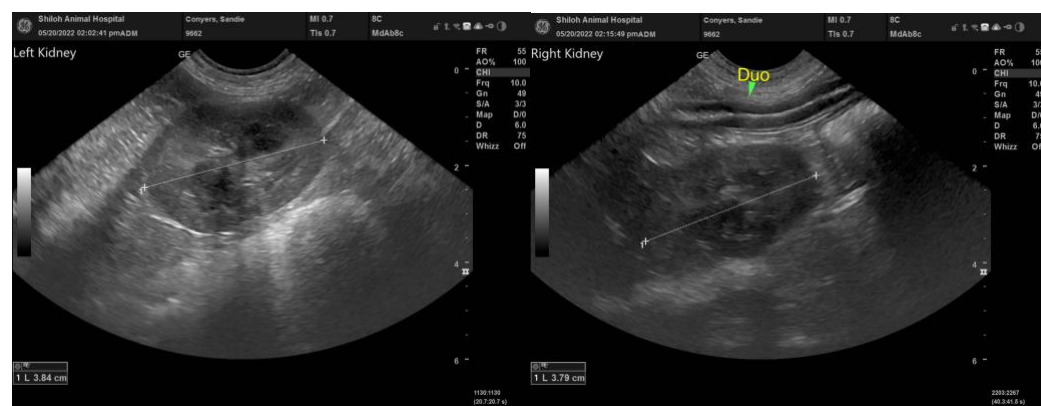
ULTRASONOGRAPHIC FINDINGS

- Non-specific gastroenteropathy, possible inflammatory bowel.
- Mild gallbladder debris – incidental, potentially secondary to fasting or non-clinical cholestasis.

INTERPRETATION OF THE FINDINGS & FURTHER RECOMMENDATIONS

Overall, no overt evidence of significant visceral (specifically gastroenterocolic) pathology. At times, the sonographic presentation of the gastrointestinal tract does not correlate with present gastrointestinal signs. In patients with recurrent gastrointestinal signs, considerations may include dysbiosis, dietary hypersensitivity/food allergy, low-grade to chronic pancreatitis, or inflammatory bowel disease, both of which may present in a similar sonographic manner. Occult parasitism also possible. No overt evidence of mechanical gastrointestinal obstruction or foreign material.

Further assessment may include GI panel to include PLI, TLI, cobalamin and folate. If vomiting only is present, hydrolyzed diet with potential multiple smaller, more frequent feedings and gastroprotectants with assessment of clinical response would be reasonable. Potential for long-term limited antigen or hydrolyzed diet may be indicated. Broad-spectrum deworming suggested (i.e., Panacur 50 mg/kg PO SID for 5 consecutive days) even if fecal testing is negative.





PATIENT

Sandie Conyers

SPECIES

Canine

BREED

Chihuahua X

SEX

Spayed Female

AGE

7.5 Years

WEIGHT

12.3 Pounds

INTERPRETED BY

R. McKenzie Daniel,
DVM, DABVP
(Canine and Feline)

IMAGING PERFORMED BY

Emily Kirk

HOSPITAL NAME

Shiloh Vet Hospital

REFERRING VET

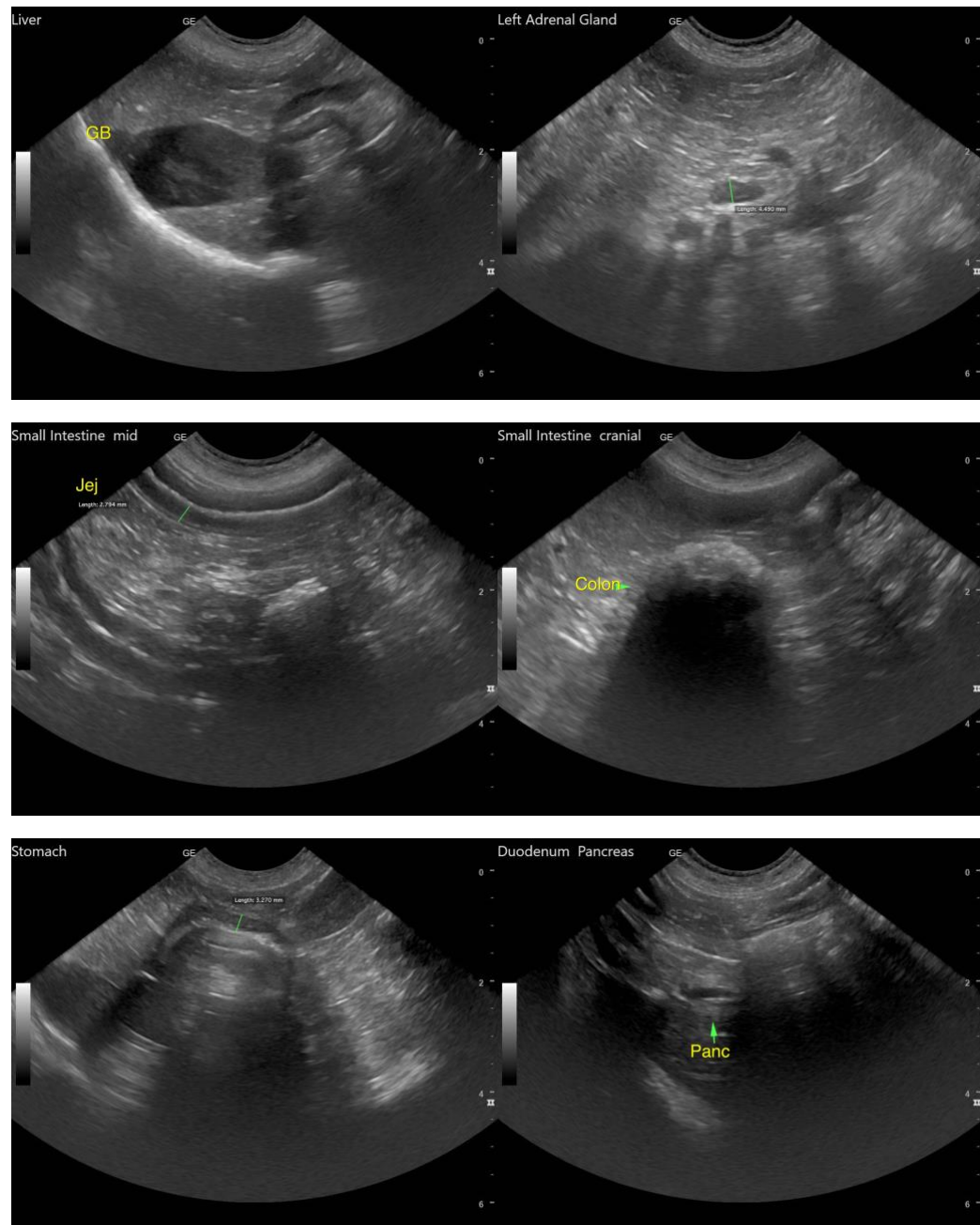
Dr. Audra Alley

INVOICE

37823

DATE

5/20/22





PATIENT

Sandie Conyers

SPECIES

Canine

BREED

Chihuahua X

SEX

Spayed Female

AGE

7.5 Years

WEIGHT

12.3 Pounds

INTERPRETED BY

R. McKenzie Daniel,
DVM, DABVP
(Canine and Feline)

IMAGING PERFORMED BY

Emily Kirk

HOSPITAL NAME

Shiloh Vet Hospital

REFERRING VET

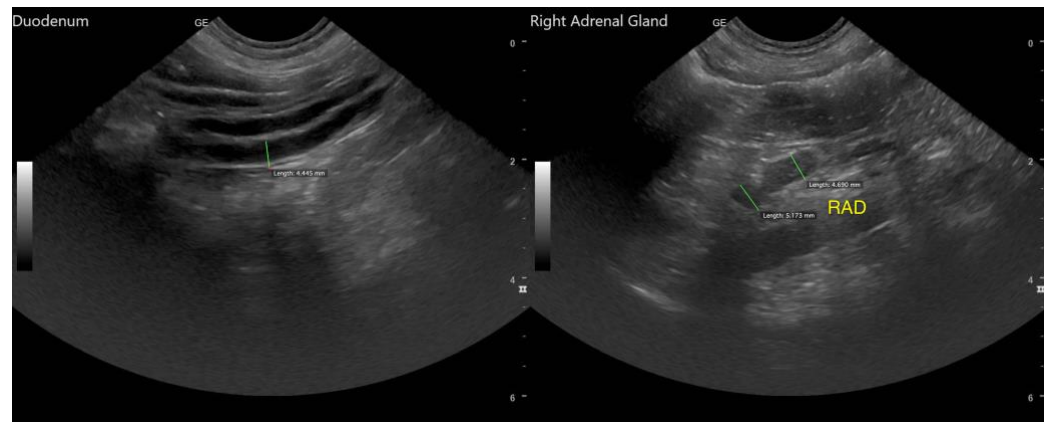
Dr. Audra Alley

INVOICE

37823

DATE

5/20/22



The information and recommendations provided are based on the images presented by the referring veterinarian/sonographer. No evaluation can be communicated regarding pathology that was not visible in the image/video clips provided.

Thank you for this referral. If the clinical or image interpretation does not parallel your findings or if I can be of any further assistance please contact me.

R. McKenzie Daniel, DVM, DABVP (Canine / Feline Practice)

info@SonoPath.com