



## PATIENT

Marley Gomory

## PRESENTING CLINICAL SIGNS

Patient presents with a grade 4/6 heart murmur, patient needs procedure under general anesthesia.

## SPECIES

Canine

## ULTRASONOGRAPHIC EXAMINATION OF THE HEART

## BREED

Dachshund X

## SEX

Neutered Male

## AGE

10 Years

## WEIGHT

14.3 Pounds

CANINE CARDIAC PARAMETERS	MR VMAX (m/s)	TR VMAX (m/s)	LA/AO (Boon method)	LA/AO (Heart Base; Swe)	FS (%)	EF (%)	EPSS (cm)
NORMAL PARAMETER	4.5-5.5	<2.7	1.3	<1.6	28-40	40-100	<0.6
PATIENT	6.4		1.14	1.3	36	72.1	0.2
CANINE CARDIAC PARAMETERS	HR (BPM)	AV VMAX (m/s)	PV MAX (m/s)	BODY WEIGHT (kg)	LA 2D short axis Base view (cm)	LVIDd Avg; 2D and m-mode short axis (cm)	LVIDs Avg; 2D and m-mode short axis (cm)
NORMAL PARAMETER	50-100	0.7-1.7	0.7-1.6	BELOW	BELOW	BELOW	BELOW
PATIENT	114	1.5	1.0		2.7	2.5	

## Cardiac Presentation

## INTERPRETED BY

R. McKenzie Daniel,  
DVM, DABVP  
(Canine and Feline)

The echocardiogram in this patient demonstrated normal **left atrial** size based on 3 different LA measurement methods. Chamber volumes and echogenicity were normal. The cranial and caudal **mitral** valve leaflets presented vegetative thickening consistent with endocardiosis. Doppler indicated measurable eccentric insufficiency. Mild elevated MR velocity. The **left ventricle** presented thicknesses with linear contour and was not dilated nor restricted. The **myocardium** presented normal echogenicity without subjective evidence of significant fibrotic or ischemic disease. **Contractility** of the ventricular walls was adequate and in normal range for this patient evidenced by the fractional shortening measurement and subjective evaluation of the different regions of the myocardium. The **left ventricular outflow** tract demonstrated normal laminar flow and subjective structural integrity. The **right atrium** and auricle revealed normal size, structure and content. No evidence of masses was noted or chamber overload. **Tricuspid** valvular assessment demonstrated adequate linear morphology. The **right ventricle** was of normal size (1/3 diameter of LV), chordae structure, myocardial echogenicity and thickness. **Pulmonic** tract assessment revealed normal valve structure, laminar flow, and diameter (approx.1:1 pa/ao ratio). No visible **pericardial** or free pleura fluid was noted. No echographically detectable evidence of infiltrative disease was visible. The cranial **mediastinum and pericardial regions** were free of masses in the visible window.

## IMAGING PERFORMED BY

Kelly Vazquez

## HOSPITAL NAME

Animal Paradise

## REFERRING VET

Dr. ElShafie

## ULTRASONOGRAPHIC FINDINGS

- Chronic mitral valve disease (ACVIM B1)

## INVOICE

37815

## INTERPRETATION OF THE FINDINGS & FURTHER RECOMMENDATIONS

The cause of the murmur is chronic degenerative valvular changes with secondary eccentric mitral valve insufficiency. No other clinical issues such as LV systolic dysfunction or evidence of clinical pulmonary hypertension were noted. The lack of left atrial enlargement implies that the risk of

## DATE

5/20/22



**PATIENT**

Marley Gomory

complication secondary to mitral valve insufficiency is low at this time and, without current clinical signs, indicates that medical therapy is not required. Conservative monitoring is recommended with a recheck echocardiogram in 6-12 months, sooner if clinical signs suggestive of heart disease develop. No anesthetic contraindications. Suggested anesthetic protocol may include opioid or Benzodiazepine pre-med, induction with Propofol or Alfaxalone, and appropriate gas anesthesia with avoidance of alpha 2 agonists.

**SPECIES**

Canine

**BREED**

Dachshund X

**SEX**

Neutered Male

**AGE**

10 Years

**WEIGHT**

14.3 Pounds

**INTERPRETED BY**

R. McKenzie Daniel, DVM, DABVP (Canine and Feline)

**IMAGING PERFORMED BY**

Kelly Vazquez

**HOSPITAL NAME**

Animal Paradise

**REFERRING VET**

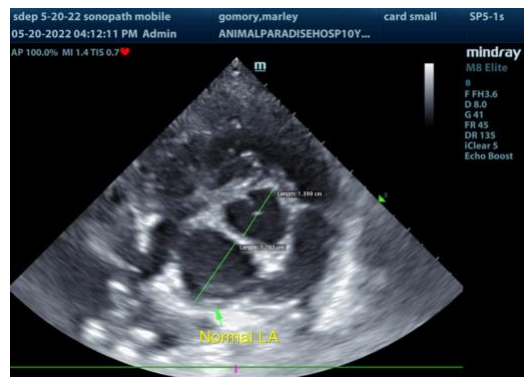
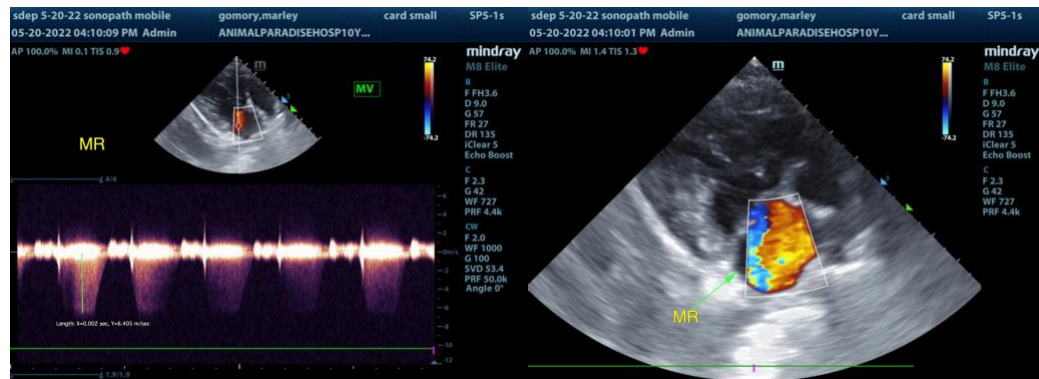
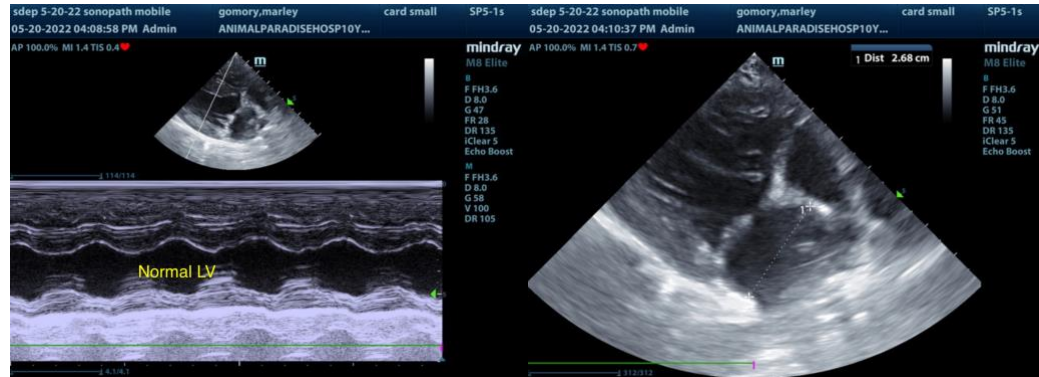
Dr. ElShafie

**INVOICE**

37815

**DATE**

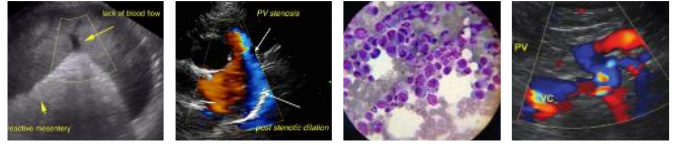
5/20/22



The information and recommendations provided are based on the images presented by the referring veterinarian/sonographer. No evaluation can be communicated regarding pathology that was not visible in the image/video clips provided.

Thank you for this referral. If the clinical or image interpretation does not parallel your findings or if I can be of any further assistance please contact me.

R. McKenzie Daniel, DVM, DABVP (Canine / Feline Practice)



**PATIENT**

info@SonoPath.com

Marley Gomory

**SPECIES**

Canine

**BREED**

Dachshund X

**SEX**

Neutered Male

**AGE**

10 Years

**WEIGHT**

14.3 Pounds

**INTERPRETED BY**

R. McKenzie Daniel,  
DVM, DABVP  
(Canine and Feline)

**IMAGING  
PERFORMED BY**

Kelly Vazquez

**HOSPITAL NAME**

Animal Paradise

**REFERRING VET**

Dr. ElShafie

**INVOICE**

37815

**DATE**

5/20/22