



**PATIENT**

Bob VanGunst

**SPECIES**

Canine

**BREED**

Beagle Mix

**SEX**

MN

**AGE**

12y 4m

**WEIGHT**

40.9 lbs.

**INTERPRETED BY**

R. McKenzie Daniel,  
 DVM, DABVP  
 (Canine and Feline)

**IMAGING PERFORMED BY**

Vincent Ravancho, CVT

**HOSPITAL NAME**

Long Valley AH

**REFERRING VET**

Dr. Earl

**INVOICE**

10890

**DATE**

5/19/26

**PRESENTING CLINICAL SIGNS**

PU/PD. ACTH test consistent with Cushings. Clinical findings - O reports recent increase in drinking and urination. Recent labwork consistent with Cushings. Requesting U/S to differentiate between pituitary vs adrenal. Hill's Z/D diet. Sedated with Torb/Gabapentin

Abnormal PE/Chem/CBC/UA Results: ALP 491, Lymphopenia/Eosinopenia + Monocytosis, Borderline hyperproteinemia/hyperalbuminemia. Chronic Anaplasma.

**ULTRASONOGRAPHIC EXAMINATION OF THE ABDOMEN**

**Urinary System**

The urinary bladder, trigone, cystourethral junction, and visible pelvic urethra to a depth of 3.0 cm exhibited normal thickness and tone. Anechoic urine was present in the lumen with no uroliths or sediment. The ureteral papillae were normal. The ureters were not visible which is normal. No evidence of inflammatory or neoplastic changes were noted.

The area of the residual prostate appeared normal and free of pathology.

The area of the iliac trifurcation was free of pathology.

Normal size and margination were present in the kidneys. A normal 1:3 cortex / medulla ratio was maintained. The medulla and cortices were uniform in texture with some increased echogenicity and mild loss of corticomodullary symmetry and definition expected for the age of the patient. No evidence of pelvic dilation was present. The left kidney measured 5.7 cm in length. The right kidney measured 6.8 cm in length.

**Adrenal Glands**

Bilateral symmetrical adrenal gland enlargement with uniformly hypoechoic parenchyma was present. The left adrenal gland measured 2.8 cm length x 0.95 cm width at the caudal pole. The right adrenal gland measured 3.0 cm length x 1.1 cm width at the caudal pole.

**Spleen**

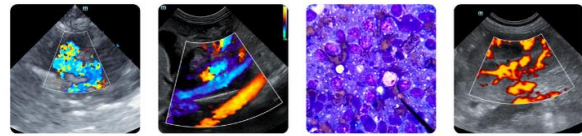
The spleen exhibited a finely textured and homogenous parenchyma which was hyperechoic to the liver and renal cortical parenchyma. The capsule was smooth and regular without apparent expansion. The splenic vasculature at the hilus was normal in volume with no evidence of congestion or thrombosis. Acute to chronic inflammatory, neoplastic, or benign parenchyma changes were not noted.

**Liver/Gallbladder**

The liver presented mild to moderately enlarged in size. The parenchyma of the liver was subjectively normal in echogenicity compared to the spleen and renal cortices. The liver parenchyma was uniform with a mildly coarse echotexture. The capsule of the liver was symmetrically rounded to mildly swollen in margination. The hepatic and portal vasculature were normal in appearance without signs of congestion. The gallbladder was non-distended in size containing primarily anechoic content with mild, nonorganized gallbladder debris. The cystic and common bile ducts were normal.

**Gastrointestinal**

The stomach presented intact wall layering with a normal wall layer ratio. The lumen of the stomach was empty without evidence of retained ingesta, fluid, or foreign material.



**PATIENT**

Bob VanGunst

**SPECIES**

Canine

**BREED**

Beagle Mix

**SEX**

MN

**AGE**

12y 4m

**WEIGHT**

40.9 lbs.

**INTERPRETED BY**

R. McKenzie Daniel,  
 DVM, DABVP  
 (Canine and Feline)

**IMAGING PERFORMED BY**

Vincent Ravancho, CVT

**HOSPITAL NAME**

Long Valley AH

**REFERRING VET**

Dr. Earl

**INVOICE**

10890

**DATE**

5/19/26

The small intestine presented intact wall layering with 1:3 muscularis/mucosa ratio. The lumen of the small intestine was empty with no signs of ileus, obstruction, or foreign material.

Normal visible colon wall layers were present with formed feces in lumen.

***Pancreas***

The parenchyma of the left limb, body, and right limb of the pancreas presented isoechoic to the adjacent omental fat. A normal curvilinear capsule contour of the pancreas was present. The visible pancreatic duct was normal. No signs of active inflammation or neoplastic disease were evident.

***Free Abdomen***

No overt lymphadenopathy or peritoneal effusion was present.

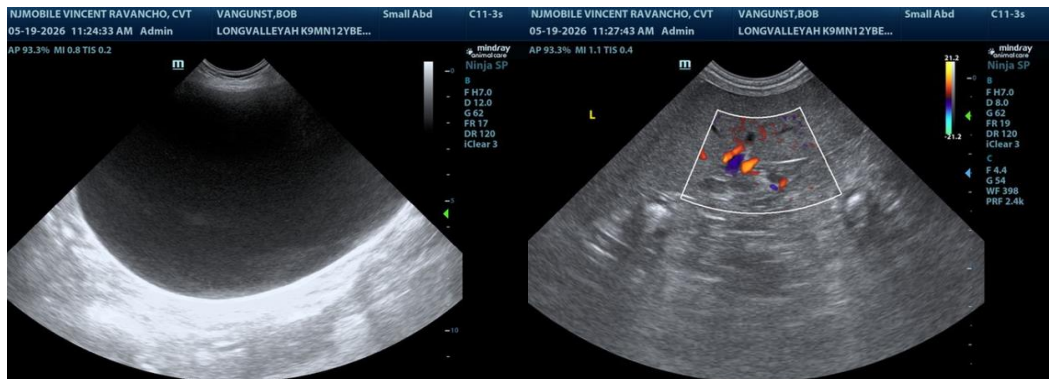
**ULTRASONOGRAPHIC FINDINGS**

- Bilateral adrenomegaly
- Mild chronic renal changes
- Vacuolar / steroid hepatopathy pattern
- Mild gallbladder debris (non mucocele)

**INTERPRETATION OF THE FINDINGS & FURTHER RECOMMENDATIONS**

The bilateral adrenomegaly is most consistent with pituitary-dependent hyperadrenocorticism without evidence of adrenal or abdominal neoplastic criteria. Empirical therapy for pituitary-dependent hyperadrenocorticism with hepatosupportive medications and clinical monitoring is recommended.

Further renal staging to include urine C/S or UPC level, if clinically indicated, may be considered.





**PATIENT**

Bob VanGunst

**SPECIES**

Canine

**BREED**

Beagle Mix

**SEX**

MN

**AGE**

12y 4m

**WEIGHT**

40.9 lbs.

**INTERPRETED BY**

R. McKenzie Daniel,  
 DVM, DABVP  
 (Canine and Feline)

**IMAGING PERFORMED BY**

Vincent Ravancho, CVT

**HOSPITAL NAME**

Long Valley AH

**REFERRING VET**

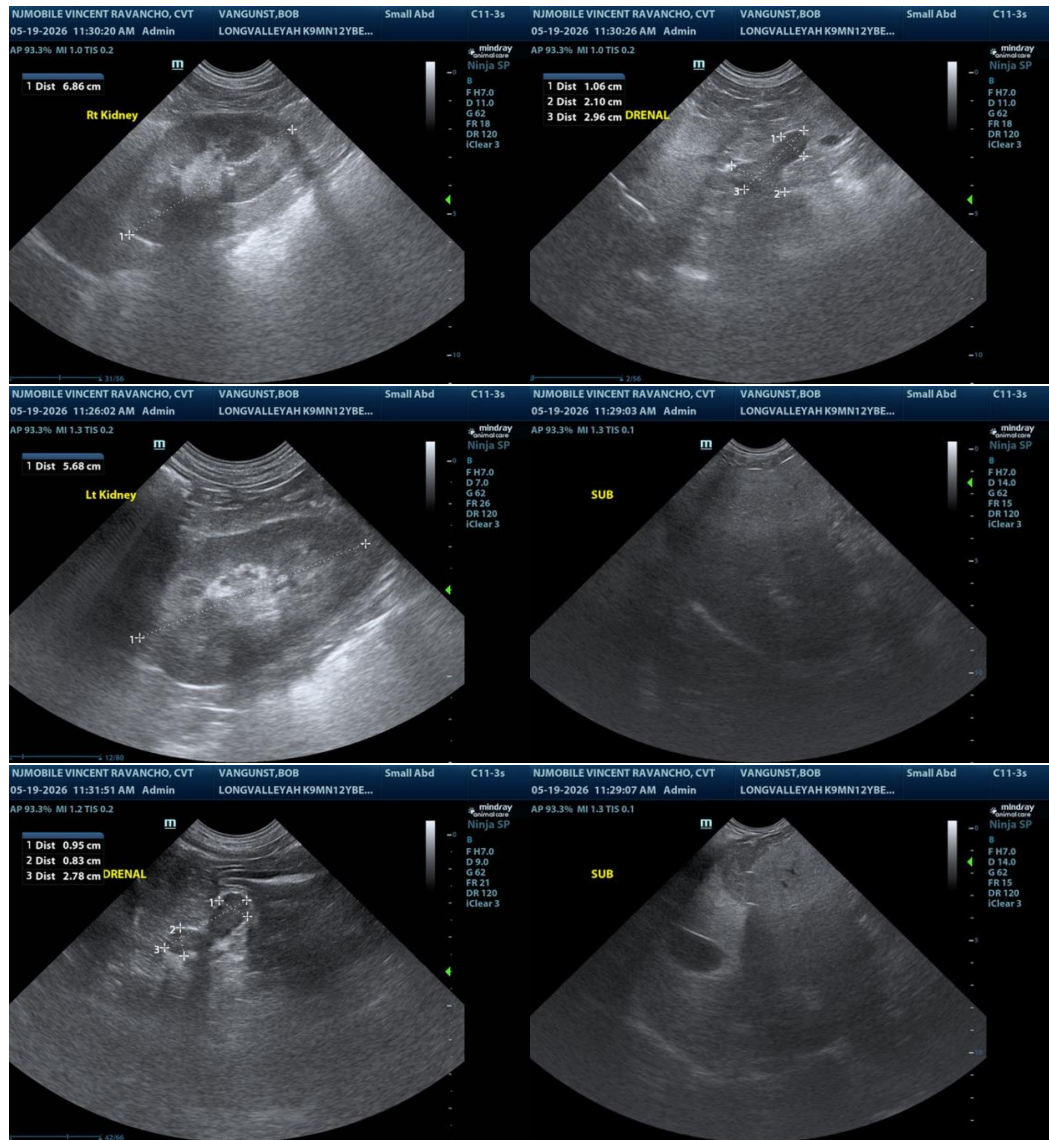
Dr. Earl

**INVOICE**

10890

**DATE**

5/19/26



The information and recommendations provided are based on the images presented by the referring veterinarian/sonographer. No evaluation can be communicated regarding pathology that was not visible in the image/video clips provided.

Thank you for this referral. If the clinical or image interpretation does not parallel your findings or if I can be of any further assistance, please contact me.

R. McKenzie Daniel, DVM, DABVP (Canine/Feline Practice)  
[info@sonopath.com](mailto:info@sonopath.com)