



## PATIENT

Brody Hyer

## SPECIES

Canine

## BREED

Poodle x

## SEX

Neutered Male

## AGE

7

## WEIGHT

23.4

## INTERPRETED BY

R. McKenzie Daniel,  
DVM, DABVP  
(Canine and Feline)

## IMAGING PERFORMED BY

Jenn

## HOSPITAL NAME

Rockaway Animal  
Hospital

## REFERRING VET

Dr. Kahn

## INVOICE

75225

## DATE

5/18/26

## PRESENTING CLINICAL SIGNS

Met check had anal gland adenocarcinoma removed 4/20/25 no regrowth on palpation chest rads clear Pt needs hip sx and want to make sure no major spread before proceeding Current meds Rimadyl Gaba Amantadine

## ULTRASONOGRAPHIC EXAMINATION OF THE ABDOMEN

### *Urinary System*

The urinary bladder, trigone, cystourethral junction, and visible pelvic urethra to a depth of – cm exhibited normal thickness and tone. Anechoic urine was present in the lumen with no uroliths or sediment. The ureteral papillae were normal. The ureters were not visible which is normal. No evidence of inflammatory or neoplastic changes were noted.

The residual prostate was symmetrically normal in size with uniform parenchyma and slight coarse echotexture.

No evidence of medial iliac or sublumbar lymphadenopathy or masses.

Normal size and margination were present in the kidneys. A normal 1:3 cortex / medulla ratio and normal corticomedullary definition were maintained. The echogenicity of the cortex was similar to or slightly less than normal liver parenchyma while the medulla echogenicity was hypoechoic to the cortex with no evidence of pelvic dilation. Right kidney measured 4.3 cm. Left kidney measured 4.7 cm.

### *Adrenal Glands*

The adrenal glands were uniform in size and contour with a uniformly hypoechoic parenchyma. Right measured 0.59 cm at the caudal pole. Left measured 0.45 cm at the caudal pole.

### *Spleen*

The spleen exhibited a finely textured and homogenous parenchyma which was hyperechoic to the liver and renal cortical parenchyma. The capsule was smooth and regular without apparent expansion. The splenic vasculature at the hilus was normal in volume with no evidence of congestion or thrombosis. Acute to chronic inflammatory, neoplastic, or benign parenchyma changes were not noted.

### *Liver*

The liver was subjectively normal in size, structure, and contour. The liver parenchyma was uniform and hypoechoic to the spleen with a mild coarse echotexture. The hepatic and portal vasculature were normal in appearance without signs of congestion. The gallbladder was non-distended in size with thin walls and primarily anechoic luminal content. The cystic and common bile ducts were normal.

### *Gastrointestinal*

The stomach presented intact wall layering with a normal wall layer ratio. The lumen of the stomach was empty with no signs of ileus, obstruction or foreign material.

The small intestine presented intact wall layering with 1:3 muscularis/mucosa ratio. The lumen of the small intestine was empty with no signs of ileus, obstruction or foreign material.

Normal visible colon wall layers were present with apparent formed feces in lumen.



**PATIENT**

Brody Hyer

**SPECIES**

Canine

**BREED**

Poodle x

**SEX**

Neutered Male

**AGE**

7

**WEIGHT**

23.4

**INTERPRETED BY**

R. McKenzie Daniel,  
DVM, DABVP  
(Canine and Feline)

**IMAGING PERFORMED BY**

Jenn

**HOSPITAL NAME**

Rockaway Animal  
Hospital

**REFERRING VET**

Dr. Kahn

**INVOICE**

75225

**DATE**

5/18/26

**Pancreas**

The parenchyma of the left limb, body and right limb of the pancreas presented isoechoic to the adjacent omental fat. A normal curvilinear capsule contour of the pancreas was present. The visible pancreatic duct was normal. No signs of active inflammation or neoplastic disease was evident.

**Free Abdomen**

No overt lymphadenopathy or peritoneal effusion was present.

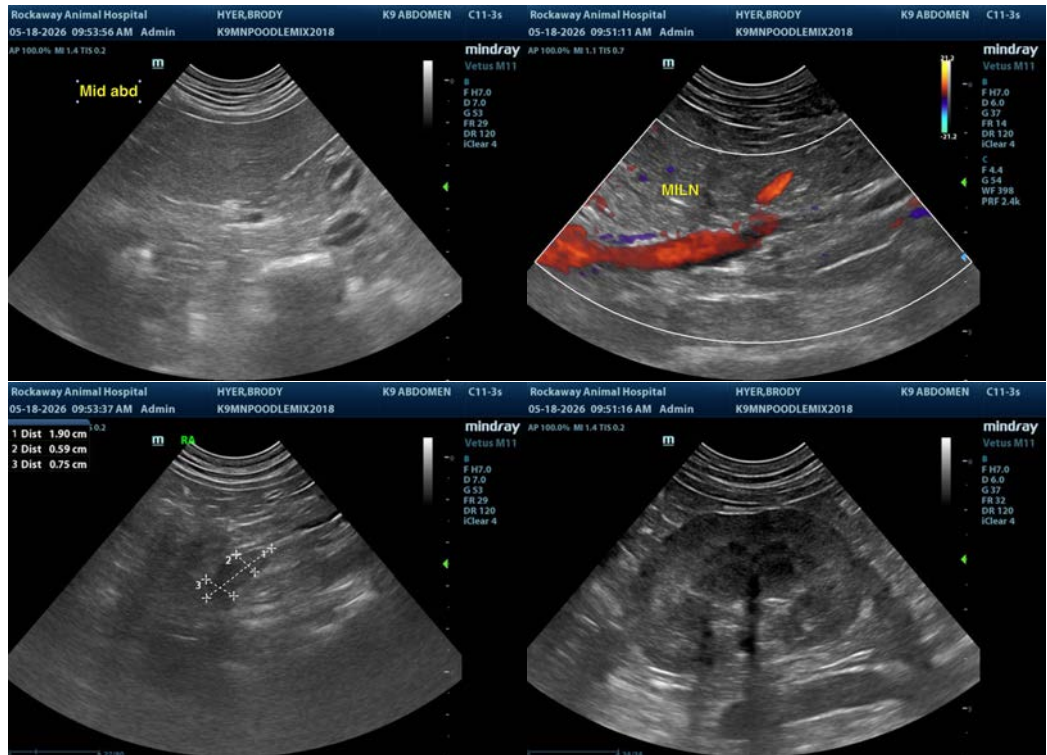
Rapid view of the heart revealed no evidence of pericardial masses or effusion in the visible window.

**ULTRASONOGRAPHIC FINDINGS**

- Sonographically normal abdomen.

**INTERPRETATION OF THE FINDINGS & FURTHER RECOMMENDATIONS**

No evidence of visceral pathology, including no evidence of abdominal or retroperitoneal primary or metastatic neoplastic criteria.





**PATIENT**

Brody Hyer

**SPECIES**

Canine

**BREED**

Poodle x

**SEX**

Neutered Male

**AGE**

7

**WEIGHT**

23.4

**INTERPRETED BY**

R. McKenzie Daniel,  
DVM, DABVP  
(Canine and Feline)

**IMAGING PERFORMED BY**

Jenn

**HOSPITAL NAME**

Rockaway Animal  
Hospital

**REFERRING VET**

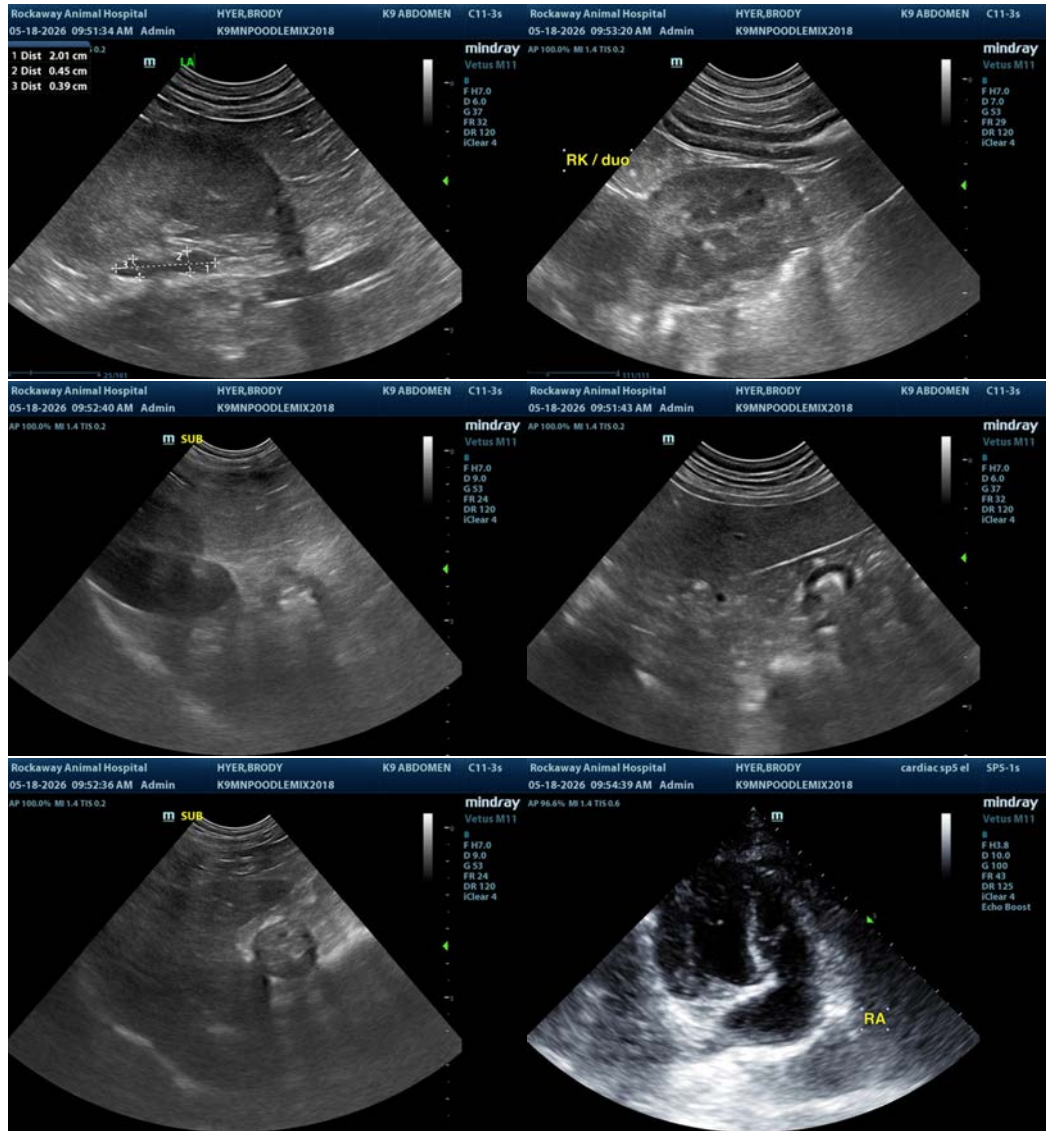
Dr. Kahn

**INVOICE**

75225

**DATE**

5/18/26



The information and recommendations provided are based on the images presented by the referring veterinarian/sonographer. No evaluation can be communicated regarding pathology that was not visible in the image/video clips provided.

Thank you for this referral. If the clinical or image interpretation does not parallel your findings or if I can be of any further assistance please contact me.

**R. McKenzie Daniel, DVM, DABVP (Canine / Feline Practice)**

info@SonoPath.com