

**PATIENT**

Neko Sheldrake

**SPECIES**

Feline

**BREED**

DSH

**SEX**

MN

**AGE**

8 years

**WEIGHT**

5.4 kg

**INTERPRETED BY**

R. McKenzie Daniel,  
DVM, DABVP

**IMAGING  
PERFORMED BY**

Crystal Hill

**HOSPITAL NAME**

Beatties Burlington  
PH

**REFERRING VET**

Dr. Murota

**INVOICE**

15257

**DATE**

5/18/22

**PRESENTING CLINICAL SIGNS**

Exam of May 11th - inappetence, appetite decreased of 75%, E/D a little still, slowly getting worst over the last 5-6 weeks, 2-3 x a week vomiting bile, hiding for longer period of time, formed BM, no diarrhea. Left with Lactulose and clavaseptin. BW done (see below). Exam May 16th - No improvement, Appetite decrease even more, only eats the treats, 0.16kg loss from last visit. No diarrhea formed stool. Intermittent vomiting - more ongoing At palpation - Possible firmer structure palpable dorsal mid abdomen (stomach? kidney?) p appeared comfortable. Small bladder, no obvious constipation noted lactulose 2.5mL in last 24hr, clavaseptin 62.5mg 1 tab BID, May  
Abnormal PE/Chem/CBC/UA Results: May 11th: CBC, Electrolytes, Chem: nsf Urine analysis: cocci bact

**ULTRASONOGRAPHIC EXAMINATION OF THE ABDOMEN**

**Urinary System**

The urinary bladder, trigone, cystourethral junction, and visible pelvic urethra to a depth of 2.0 cm exhibited normal thickness and tone. Primarily anechoic urine with focal dependent luminal mineral present. The ureteral papillae were normal. The ureters were not visible which is normal. No evidence of inflammatory or neoplastic changes was noted.

Normal size and margination were present in the kidneys. A normal 1:3 cortex / medulla ratio and normal corticomedullary definition were maintained. The echogenicity of the cortex was similar to or slightly less than normal liver parenchyma while the medulla echogenicity was hypoechoic to the cortex with no evidence of pelvic dilation. Pinpoint to focal area of nonobstructive medullary mineral noted in the left kidney, not overtly evident in the right kidney. The left kidney measured 4.0 cm in length. The right kidney measured 4.2 cm in length.

**Adrenal Glands**

The left adrenal gland was uniform in size and contour with a uniformly hypoechoic parenchyma. The left adrenal gland measured 0.50 cm.

The right adrenal gland was uniform in size and contour with a uniformly hypoechoic parenchyma. The right adrenal gland measured 0.38 cm.

**Spleen**

The spleen exhibited a finely textured and homogenous parenchyma which was hyperechoic to the liver and renal cortical parenchyma. The capsule was smooth and regular without apparent expansion. The splenic vasculature at the hilus was normal in volume with no evidence of congestion or thrombosis. Acute to chronic inflammatory, neoplastic, or benign parenchyma changes were not noted.

**Liver/ Gallbladder**

The liver was subjectively normal in size, structure, and contour. The liver parenchyma was uniform and hypoechoic to the spleen with a mild coarse echotexture. The hepatic and portal vasculature were normal in appearance without signs of congestion.

The gallbladder was non-distended in size with thin walls and primarily anechoic luminal content. The cystic and common bile ducts were normal.



**PATIENT**

Neko Sheldrake

***Gastrointestinal***

The visualized stomach was sonographically unremarkable with potential for minor retained non-shadowing ingesta/chyme.

**SPECIES**

Feline

A prominent intestinal mural mass, exhibiting moderate to marked mural hypertrophy, decreased mural echogenicity and loss of discernable wall layering was visualized in the area of the left mid to cranial abdomen medial to the spleen, caudal to the stomach, as well as subjectively cranial medial to the right kidney. The intestinal mural mass potentially measured 7-8 cm in length, but suspected to be larger, as the entire mass would not fit into a single viewing window and was visualized in several areas of the abdominal cavity. Wall width of the intestinal mass measured up to 1.3 cm. Concurrent segments of normal appearing small bowel, as well as normal appearing distal descending colon, cranial to the urinary bladder, were present. No overt evidence of mechanical gastrointestinal obstructive pattern.

**BREED**

DSH

**SEX**

MN

***Pancreas***

The parenchyma of the left limb, body, and right limb of the pancreas presented isoechoic to the adjacent omental fat. A normal curvilinear capsule contour of the pancreas was present. The visible pancreatic duct was normal. No signs of active inflammation or neoplastic disease were evident.

**AGE**

8 years

***Free Abdomen***

Subtle evidence of periintestinal reactive mesentery around the intestinal mural mass, as well as intermittent, indistinctly visualized yet mildly enlarged periintestinal mesenteric lymph nodes. An example of lymph node measured 0.48 cm in diameter. No evidence of peritoneal free fluid.

**WEIGHT**

5.4 kg

**ULTRASONOGRAPHIC FINDINGS**

**INTERPRETED BY**

R. McKenzie Daniel,  
DVM, DABVP

***Primary Findings***

- Intestinal mural mass
- Associated mild to indistinctly visualized periintestinal lymphadenopathy and minor regional periintestinal reactive mesentery.

**IMAGING PERFORMED BY**

Crystal Hill

***Secondary Findings***

- Focal urinary bladder dependent mineral
- Minor left kidney medullary mineral

**HOSPITAL NAME**

Beatties Burlington  
PH

**INTERPRETATION OF THE FINDINGS & FURTHER RECOMMENDATIONS**

**REFERRING VET**

Dr. Murota

Although sampling is required for further assessment, the intestinal mural mass is suggestive of neoplastic criteria (i.e., lymphoma, carcinoma or other) with nonneoplastic etiologies, such as severe inflammation or granulomatous disease (dry FIP) possible. Given the extent of the intestinal mural mass visualized in different area of the abdomen, definitive intestinal segments involved in the mass was difficult to ascertain. Potential for small and large bowel involvement in the mass possible. However, given the lack of reported diarrhea with formed stool, higher suspected potential for small bowel involvement may be indicated.

**INVOICE**

15257

**DATE**

5/18/22



**PATIENT**

Neko Shel Drake

Assuming normal clotting status, ultrasound guided FNA of the intestinal mural mass warranted for screening cytology and potential for oncology and/or surgical consult. Three-view chest radiographs recommended.

**SPECIES**

Feline

**BREED**

DSH

**SEX**

MN

**AGE**

8 years

**WEIGHT**

5.4 kg

**INTERPRETED BY**

R. McKenzie Daniel,  
DVM, DABVP

**IMAGING  
PERFORMED BY**

Crystal Hill

**HOSPITAL NAME**

Beatties Burlington  
PH

**REFERRING VET**

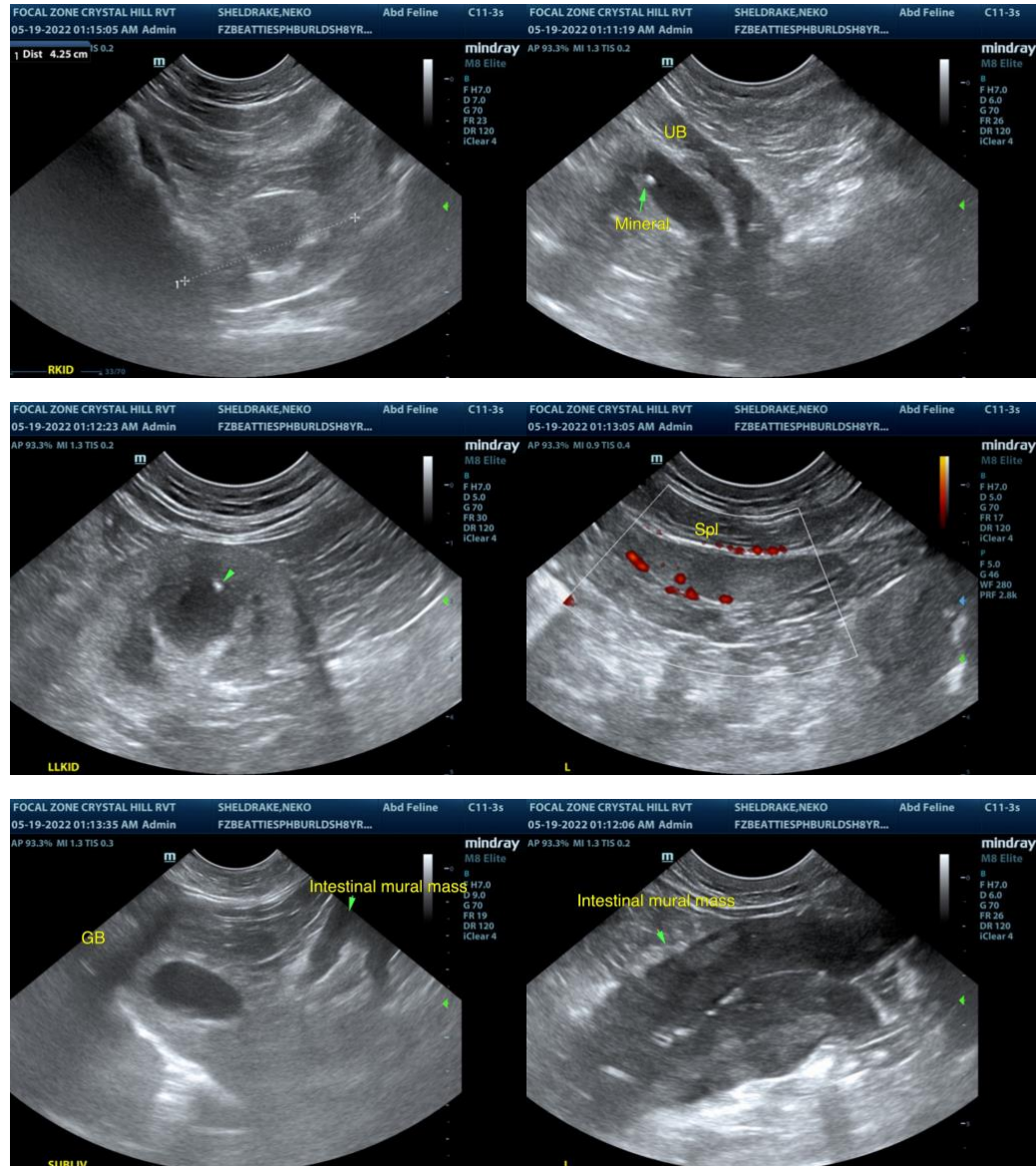
Dr. Murota

**INVOICE**

15257

**DATE**

5/18/22





**PATIENT**

Neko Shel Drake

**SPECIES**

Feline

**BREED**

DSH

**SEX**

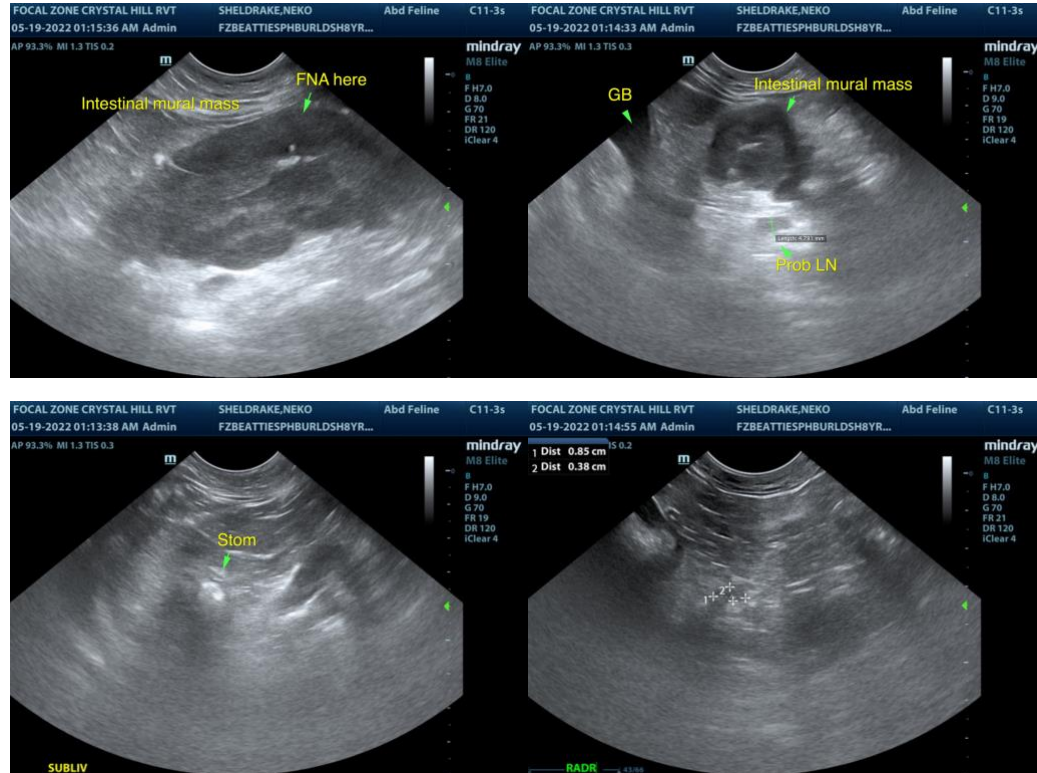
MN

**AGE**

8 years

**WEIGHT**

5.4 kg



**INTERPRETED BY**

R. McKenzie Daniel,  
DVM, DABVP

**IMAGING  
PERFORMED BY**

Crystal Hill

**HOSPITAL NAME**

Beatties Burlington  
PH

**REFERRING VET**

Dr. Murota

**INVOICE**

15257

**DATE**

5/18/22

The information and recommendations provided are based on the images presented by the referring veterinarian/sonographer. No evaluation can be communicated regarding pathology that was not visible in the image/video clips provided.

Thank you for this referral. If the clinical or image interpretation does not parallel your findings or if I can be of any further assistance please contact me.

**R. McKenzie Daniel, DVM, DABVP (Canine / Feline Practice)**  
info@SonoPath.com