



PATIENT

Vier Herr

SPECIES

Canine

BREED

Rottweiler

SEX

M

AGE

3 years

WEIGHT

122 lbs.

INTERPRETED BY

R. McKenzie Daniel,
DVM, DABVP
(Canine and Feline)

IMAGING PERFORMED BY

Jessica Miller

HOSPITAL NAME

ACC Flanders

REFERRING VET

Dr. Hallihan

INVOICE

13879

DATE

5/17/22

PRESENTING CLINICAL SIGNS

Grade IV/VI systolic murmur. Patient had echo 11/2019, at that time murmur was a grade III. No therapy warranted at that time, findings- aortic stenosis, pulmonic insufficiency, minor mitral insufficiency.

ULTRASONOGRAPHIC EXAMINATION OF THE HEART

| CANINE | MR | TR | LA/AO | LA/AO | FS | EF | EPSS |
|--------------------|------------|------------|---------------|-------------------|------------------------------|------------------------------------|------------------------------------|
| CARDIAC PARAMETERS | VMAX (m/s) | VMAX (m/s) | (Boon method) | (Heart Base; Swe) | (%) | (%) | (cm) |
| NORMAL PARAMETER | 4.5-5.5 | <2.7 | 1.3 | <1.3 | 28-40 | 40-100 | <0.6 |
| PATIENT | | | 1.1 | 1.1 | 35.7 | 65.6 | 0.1 |
| CANINE | HR | AV | PV | BODY WEIGHT | LA | LVIDd | LVIDs |
| CARDIAC PARAMETERS | (BPM) | VMAX (m/s) | MAX (m/s) | (kg) | 2D short axis Base view (cm) | Avg; 2D and m-mode short axis (cm) | Avg; 2D and m-mode short axis (cm) |
| NORMAL PARAMETER | 50-100 | 0.7-1.7 | 0.7-1.6 | | | | |
| PATIENT | 94 | 3.8 | 1.9 | | 5.0 | 4.25 | |

Cardiac Presentation

The echocardiogram in this patient demonstrated normal **left atrial** size based on 3 separate methods of LA evaluation. The cranial and caudal **mitral** valve leaflets presented mild thickening more prominent in the septal leaflet. Doppler Indicated subjective mild centralized to eccentric mitral valve Insufficiency. The **left ventricle** presented increased septal and free wall thicknesses with maintained linear contour. The **myocardium** presented normal echogenicity without subjective evidence of significant fibrotic or ischemic disease. **Contractility** of the ventricular walls was adequate and in normal range for this patient evidenced by the fractional shortening measurement and subjective evaluation of the different regions of the myocardium. The **left ventricular outflow** tract demonstrated turbulent to dynamic systolic flow. Elevated LVOT velocity, as well as aortic insufficiency (2.0 m/s max), were present on color doppler. The **right atrium** and auricle revealed normal size, structure and content. No evidence of masses was noted. **Tricuspid** valvular assessment demonstrated adequate linear morphology and kinesis. Potential for minor TR was noted, yet not considered clinically significant. The **right ventricle** was of normal size (1/3 diameter of LV), chordae structure, myocardial echogenicity and thickness. **Pulmonary outflow** tract assessment revealed overtly normal valve structure, laminar systolic flow, and overall diameter (approx. 1:1 pa/ao ratio). Previously noted, subjectively static pulmonary insufficiency was present on color doppler, measuring 0.97 cm. No visible **pericardial** or free pleura fluid was noted. The cranial **mediastinum and pericardial and extra-cardiac regions** were free of masses in the visible window.



PATIENT

Vier Herr

SPECIES

Canine

BREED

Rottweiler

SEX

M

AGE

3 years

WEIGHT

122 lbs.

INTERPRETED BY

R. McKenzie Daniel,
DVM, DABVP
(Canine and Feline)

IMAGING PERFORMED BY

Jessica Miller

HOSPITAL NAME

ACC Flanders

REFERRING VET

Dr. Hallihan

INVOICE

13879

DATE

5/17/22

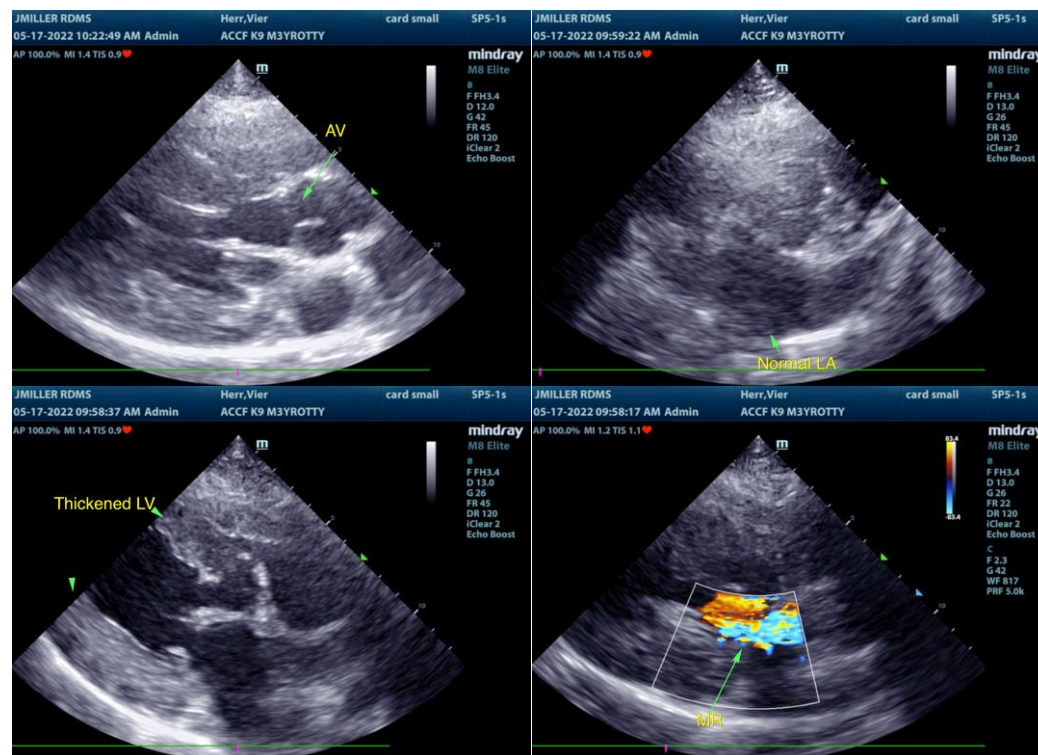
ULTRASONOGRAPHIC FINDINGS

- Moderate aortic stenosis
- LV hypertrophy, normal LA
- Suspect concurrent mitral valve dysplasia with secondary mitral valve insufficiency
- Mild Pulmonic insufficiency

INTERPRETATION OF THE FINDINGS & FURTHER RECOMMENDATIONS

The estimated pressure gradient based on measured LVOT velocity is consistent with moderate aortic stenosis. The hemodynamic effects of the moderate aortic stenosis appear to be moderate resulting in secondary LV hypertrophy. Overall, the heart appears to be compensated. However, the long-term prognosis in this patient, given the cardiac changes since the previous echocardiogram, is very guarded to likely unfavorable.

Exercise restriction is advised, while anesthesia should be avoided. Atenolol 1.0-2.0 mg/kg PO SID could be considered at this stage, although significant survival benefits with this medication have not been obviously documented. Serial sonographic monitoring is required for further prognosis. Cardiology referral for further assessment could also be considered.





PATIENT

Vier Herr

SPECIES

Canine

BREED

Rottweiler

SEX

M

AGE

3 years

WEIGHT

122 lbs.

INTERPRETED BY

R. McKenzie Daniel,
DVM, DABVP
(Canine and Feline)

IMAGING PERFORMED BY

Jessica Miller

HOSPITAL NAME

ACC Flanders

REFERRING VET

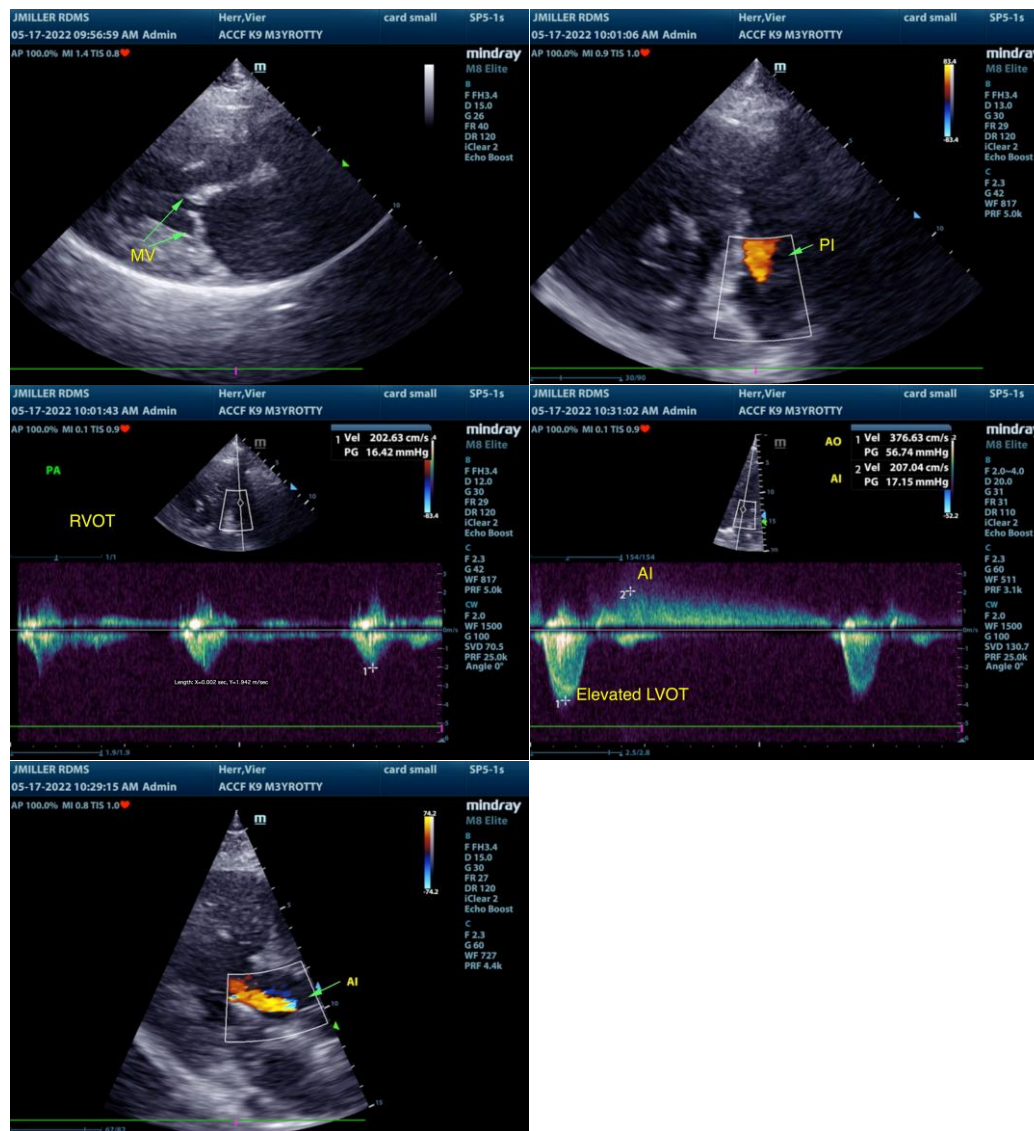
Dr. Hallihan

INVOICE

13879

DATE

5/17/22



The information and recommendations provided are based on the images presented by the referring veterinarian/sonographer. No evaluation can be communicated regarding pathology that was not visible in the image/video clips provided.

Thank you for this referral. If the clinical or image interpretation does not parallel your findings or if I can be of any further assistance please contact me.

R. McKenzie Daniel, DVM, DABVP (Canine / Feline Practice)
info@SonoPath.com