



**PATIENT**

Django Pennington

**SPECIES**

Feline

**BREED**

DSH

**SEX**

MN

**AGE**

8 years

**WEIGHT**

11.69 lbs.

**INTERPRETED BY**

R. McKenzie Daniel,  
DVM, DABVP  
(Canine and Feline)

**IMAGING  
PERFORMED BY**

Jenna Walsh, CVT

**HOSPITAL NAME**

VCA Salem AH

**REFERRING VET**

Dr. Wermuth

**INVOICE**

13892

**DATE**

5/17/22

**PRESENTING CLINICAL SIGNS**

Persistent vomiting and diarrhea. Free T4- WNL Radiographic Findings Findings: This report is based on 4 radiographs of the abdomen. The stomach and small intestine are non-distended with minimal gas. The large intestine contains normal-appearing fecal matter. Lack of fecal matter in the large intestine is compatible with history of diarrhea. No foreign material is identified. Serosal detail is normal. There is no sign of displacement to suggest a swollen pancreas. The kidneys and bladder look normal (faint rounded 6mm opacity superimposed on the bladder may be a focus of calcified fat). Remaining abdominal structures look normal. Assessment: Normal; the cause of vomiting is not apparent radiographically Primary Question/Differential to Be Answered in This Exam r/o UTI, urolith, IBD, alimentary lymphoma, GI indiscretion, parasitism, other

**ULTRASONOGRAPHIC EXAMINATION OF THE ABDOMEN**

**Urinary System**

The urinary bladder contained moderate, nondependent, particulate sediment, as well as a solitary dependent small calculus to adhered sand. No evidence of inflammatory urinary bladder mural changes was noted. The urethra was normal in structure and tone to a depth of 2.0 cm. The solitary, dependent small calculus or potential adhered sand measured 0.93 cm in diameter.

The area of the aortic trifurcation was free of pathology.

Normal size and margination were present in the kidneys. A normal 1:3 cortex / medulla ratio and normal corticomedullary definition were maintained. The echogenicity of the cortex was similar to or slightly less than normal liver parenchyma while the medulla echogenicity was hypoechoic to the cortex with no evidence of pelvic dilation. The left kidney measured 4.2 cm in length. The right kidney measured 4.3 cm in length.

**Adrenal Glands**

The left adrenal gland was uniform in size and contour with a uniformly hypoechoic parenchyma. The left adrenal gland measured 0.23 cm width. The right adrenal gland was uniform in size and contour with a uniformly hypoechoic parenchyma. The right adrenal gland measured 0.31 cm width.

**Spleen**

The spleen exhibited a finely textured and homogenous parenchyma which was hyperechoic to the liver and renal cortical parenchyma. The capsule was smooth and regular without apparent expansion. The splenic vasculature at the hilus was normal in volume with no evidence of congestion or thrombosis. Acute to chronic inflammatory, neoplastic, or benign parenchyma changes were not noted.

**Liver/ Gallbladder**

The liver was subjectively normal in size, structure, and contour. The liver parenchyma was uniform and hypoechoic to the spleen with a mild coarse echotexture. The hepatic and portal vasculature were



<b>PATIENT</b>	normal in appearance without signs of congestion. The gallbladder was non-distended in size with thin walls and primarily anechoic luminal content. The cystic and common bile ducts were normal.
Django Pennington	
<b>SPECIES</b>	<b><i>Gastrointestinal</i></b>
Feline	The stomach presented intact wall layering with a normal wall layer ratio. The lumen of the stomach was empty with no signs of ileus, obstruction, or foreign material. The gastric body wall width measured 0.24 cm.
<b>BREED</b>	The small intestine presented intact wall layering and primarily maintained a 1:3 muscularis/mucosa ratio with segmental propensity for mildly prominent muscularis layer, yet without evidence of intestinal mural thickening, loss of wall layer detail, or intestinal masses. The jejunum wall width measured 0.2 cm to potentially 0.29 cm.
DSH	
<b>SEX</b>	Normal visible colon wall layers were present with apparent formed feces in lumen.
MN	
<b>AGE</b>	<b><i>Pancreas</i></b>
8 years	The left pancreatic limb exhibited mild subjective prominent size with areas of capsule asymmetry. Subtle hypoechoic parenchyma compared to adjacent omentum with minor pancreatic duct dilation was present.
<b>WEIGHT</b>	<b><i>Free Abdomen</i></b>
11.69 lbs.	No overt lymphadenopathy or peritoneal effusion was present. No omental masses were noted.
<b>INTERPRETED BY</b>	<b>ULTRASONOGRAPHIC FINDINGS</b>
R. McKenzie Daniel, DVM, DABVP (Canine and Feline)	<ul style="list-style-type: none"><li>• Solitary dependent urinary bladder calculus vs. adhered sand with moderate nondependent particulate sediment</li><li>• Sonographically unremarkable stomach</li><li>• Possible mild inflammatory enteropathy and low-grade / chronic pancreatitis</li></ul>
<b>IMAGING PERFORMED BY</b>	<b>INTERPRETATION OF THE FINDINGS &amp; FURTHER RECOMMENDATIONS</b>
Jenna Walsh, CVT	Full urinary workup including urinalysis +/- culture and sensitivity, if evidence of inflammatory cells, is suggested.
<b>HOSPITAL NAME</b>	Although not definitive, the pancreas and small Intestine exhibited subtle sonographic changes which, although potential patient variant is possible, may suggest some degree of segmental Inflammatory enteropathy/low-grade IBD or low-grade to chronic pancreatitis. Low-grade to chronic pancreatitis may be suspected if evidence of cranial abdominal or subxiphoid discomfort on palpation.
VCA Salem AH	
<b>REFERRING VET</b>	
Dr. Wermuth	
<b>INVOICE</b>	A GI panel to include PLI/TLI/Cobalamin/Folate is warranted for further assessment. Dietary intolerance / food hypersensitivity or occult parasitism if the patient is indoor/outdoor, as contributing factors could also be possible. Empirically, a hydrolyzed diet trial, prophylactic deworming, high colony count probiotics such as Provable, empirical cobalamin supplementation, +/- additional
13892	
<b>DATE</b>	
5/17/22	



**PATIENT**

Django Pennington

**SPECIES**

Feline

**BREED**

DSH

**SEX**

MN

**AGE**

8 years

**WEIGHT**

11.69 lbs.

**INTERPRETED BY**

R. McKenzie Daniel,  
DVM, DABVP  
(Canine and Feline)

**IMAGING PERFORMED BY**

Jenna Walsh, CVT

**HOSPITAL NAME**

VCA Salem AH

**REFERRING VET**

Dr. Wermuth

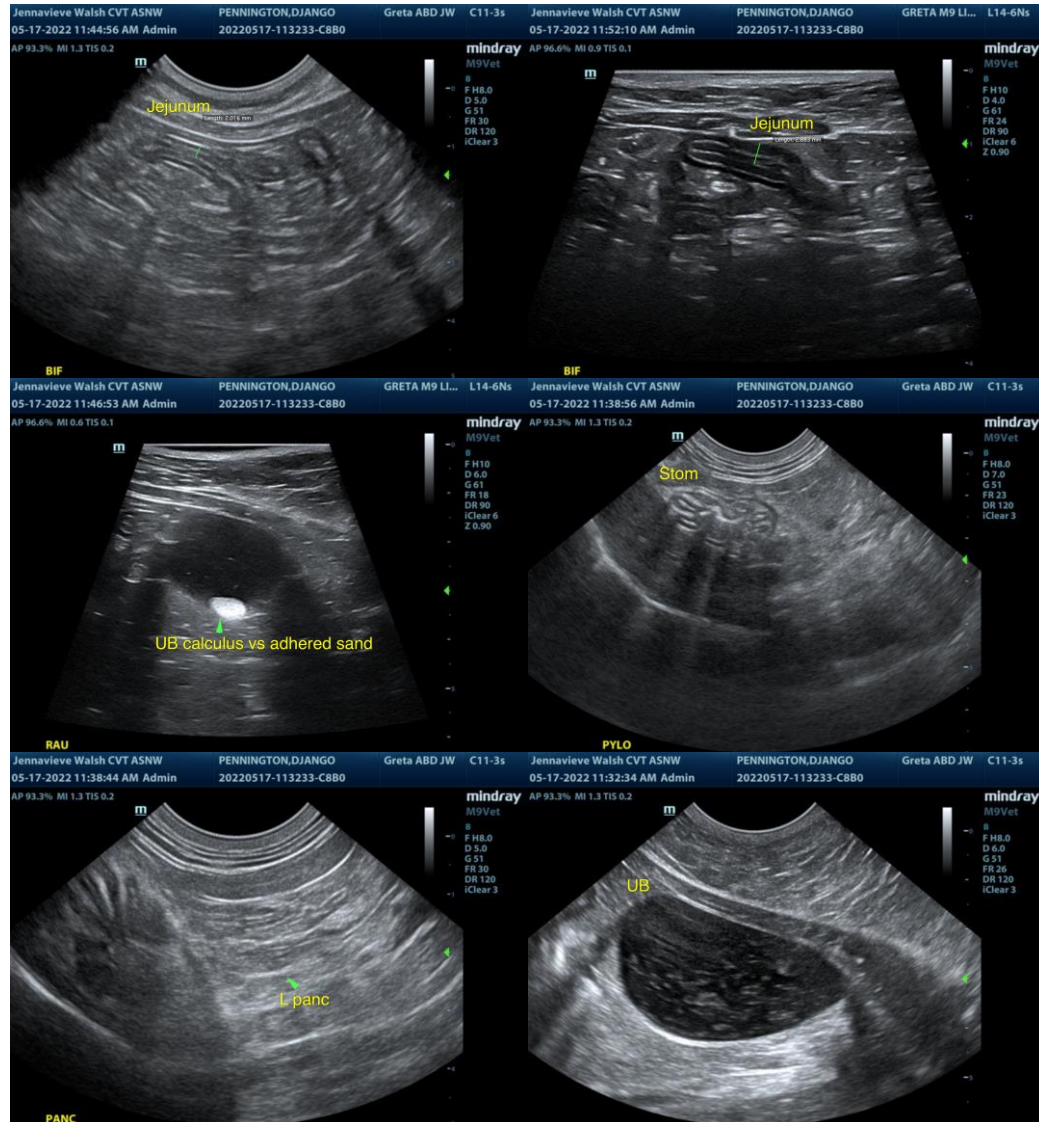
**INVOICE**

13892

**DATE**

5/17/22

conservative therapy for inflammatory enteropathy / low-grade pancreatitis with an assessment of clinical response would be reasonable. Sonographic reassessment of the gastrointestinal tract and pancreas is suggested to assess for evidence of progressive sonographic changes if persistent gastrointestinal signs despite supportive care are noted.





**PATIENT**

Django Pennington

**SPECIES**

Feline

**BREED**

DSH

**SEX**

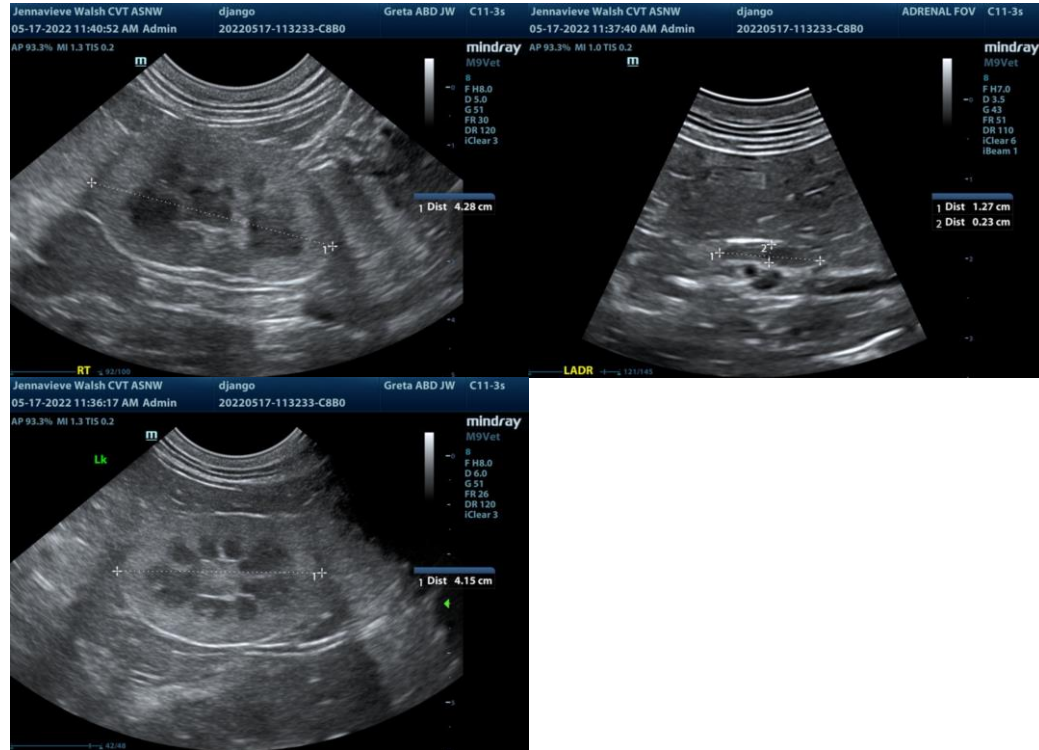
MN

**AGE**

8 years

**WEIGHT**

11.69 lbs.



**INTERPRETED BY**

R. McKenzie Daniel,  
DVM, DABVP  
(Canine and Feline)

**IMAGING PERFORMED BY**

Jenna Walsh, CVT

**HOSPITAL NAME**

VCA Salem AH

**REFERRING VET**

Dr. Wermuth

**INVOICE**

13892

**DATE**

5/17/22

The information and recommendations provided are based on the images presented by the referring veterinarian/sonographer. No evaluation can be communicated regarding pathology that was not visible in the image/video clips provided.

Thank you for this referral. If the clinical or image interpretation does not parallel your findings or if I can be of any further assistance please contact me.

**R. McKenzie Daniel, DVM, DABVP (Canine / Feline Practice)**  
info@SonoPath.com