



PATIENT PRESENTING CLINICAL SIGNS

Hank Shopp History: ADR; SWOLLEN POPLITEAL LYMPHNODES, WITH SWOLLEN LEFT REAR LEG; INAPPETANCE BUT VOMITS IF HE DOES EAT WITHIN 2 HOURS

SPECIES Abnormal PE/Chem/CBC/UA Results: Barium study WNL; x-rays revealed colon is being suppressed; prostate appears large

Canine

ULTRASONOGRAPHIC EXAMINATION OF THE ABDOMEN

BREED *Urinary System*

Bulldog The urinary bladder, trigone, cystourethral junction, and visible pelvic urethra exhibited normal thickness and tone. Anechoic urine was present in the lumen with no uroliths or sediment. The ureteral papillae were normal. The ureters were not visible which is normal. No evidence of inflammatory or neoplastic changes were noted.

SEX

MN

AGE

6 yr

Normal size and margination were present in the kidneys. A normal 1:3 cortex / medulla ratio and normal corticomedullary definition were maintained. The echogenicity of the cortex was similar to or slightly less than normal liver parenchyma while the medulla echogenicity was hypoechoic to the cortex with no evidence of pelvic dilation. The left kidney measured 6.3 cm in length. The right kidney measured 6.7 cm in length.

WEIGHT

63 lb

The residual prostate was indistinctly visualized yet exhibited potential for subjective mild enlargement with maintained symmetrical capsule integrity measuring approximately 2.0 cm in diameter. Subtle nonhomogeneous residual parenchyma was present yet no overt evidence of mineralization.

Adrenal Glands

INTERPRETED BY The left and right adrenal glands were not definitively visualized.

R. McKenzie Daniel,
DVM, DABVP
(Canine and Feline)

Spleen

The spleen exhibited a finely textured and homogenous parenchyma which was hyperechoic to the liver and renal cortical parenchyma. The capsule was smooth and regular without apparent expansion. The splenic vasculature at the hilus was normal in volume with no evidence of congestion or thrombosis. Acute to chronic inflammatory, neoplastic, or benign parenchyma changes were not noted.

IMAGING PERFORMED BY
Tash

Liver

HOSPITAL NAME

Dillsburg VC

The liver was subjectively normal in size, structure, and contour. The liver parenchyma was uniform and hypoechoic to the spleen with a mild coarse echotexture. The hepatic and portal vasculature were normal in appearance without signs of congestion. The gallbladder was non-distended in size with thin walls and primarily anechoic luminal content. The cystic and common bile ducts were normal.

REFERRING VET

Dr. Crow

Gastrointestinal

The stomach presented intact yet subjective mild prominent wall layering with moderate to marked distention and retained anechoic fluid. Overt evidence of mechanical pyloric outflow obstruction was not definitive yet cannot be definitively excluded.

INVOICE

10635ag

The visualized segments of small intestine exhibited subjective intact wall layering with 1:3 muscularis/mucosa ratio. The lumen of the small intestine was empty with no signs of ileus, obstruction or foreign material.

DATE

05/16/2022

Normal visible colon wall layers were present with apparent formed feces in lumen.



PATIENT *Pancreas*

Hank Shopp The parenchyma of the left limb, body and right limb of the pancreas presented isoechoic to the adjacent omental fat. A normal curvilinear capsule contour of the pancreas was present. The visible pancreatic duct was normal. No signs of active inflammation or neoplastic disease was evident.

SPECIES *Free Abdomen*

Canine No evidence of peritoneal effusion was present.

BREED A large expansive asymmetrically marginated nonhomogeneous hypoechoic mass was present in the area of the iliac trifurcation and sublumbar space subjectively extending cranially into the area of the caudal abdomen measuring at least 11 cm in diameter but potentially larger as the mass would not fit into a single viewing window.

SEX

MN

ULTRASONOGRAPHIC FINDINGS

AGE

6 yr

- Large unspecified mass in the area of the caudal abdomen, iliac trifurcation and sublumbar space-consistent with neoplastic criteria i.e. sarcoma, round cell neoplasia such as lymphoma or other
- Hypomotile stomach

WEIGHT

63 lb

INTERPRETATION OF THE FINDINGS & FURTHER RECOMMENDATIONS

Assuming normal clotting status, an ultrasound guided FNA of the large caudal abdominal peri iliac to sublumbar mass is recommended for further assessment. Potential for multicentric neoplastic process is suspected given the concurrent popliteal lymphadenopathy. Continued as needed GI supportive care is recommended. A cause of the gastric hypomotility was not definitively evident with metabolic or potential mechanical pyloric outflow obstruction possible. A cause of pyloric outflow obstruction was not obvious, potentially indicating a primary metabolic component to the gastric hypomotility yet this potential cannot be excluded. An abdominal CT is ideal for further assessment of the unspecified mass. Three view chest radiographs recommended.

INTERPRETED BY

R. McKenzie Daniel,
DVM, DABVP
(Canine and Feline)

IMAGING PERFORMED BY

Tash

HOSPITAL NAME

Dillsburg VC

REFERRING VET

Dr. Crow

INVOICE

10635ag

DATE

05/16/2022



PATIENT

Hank Shopp

SPECIES

Canine

BREED

Bulldog

SEX

MN

AGE

6 yr

WEIGHT

63 lb

INTERPRETED BY

R. McKenzie Daniel,
DVM, DABVP
(Canine and Feline)

IMAGING PERFORMED BY
Tash

HOSPITAL NAME

Dillsburg VC

REFERRING VET

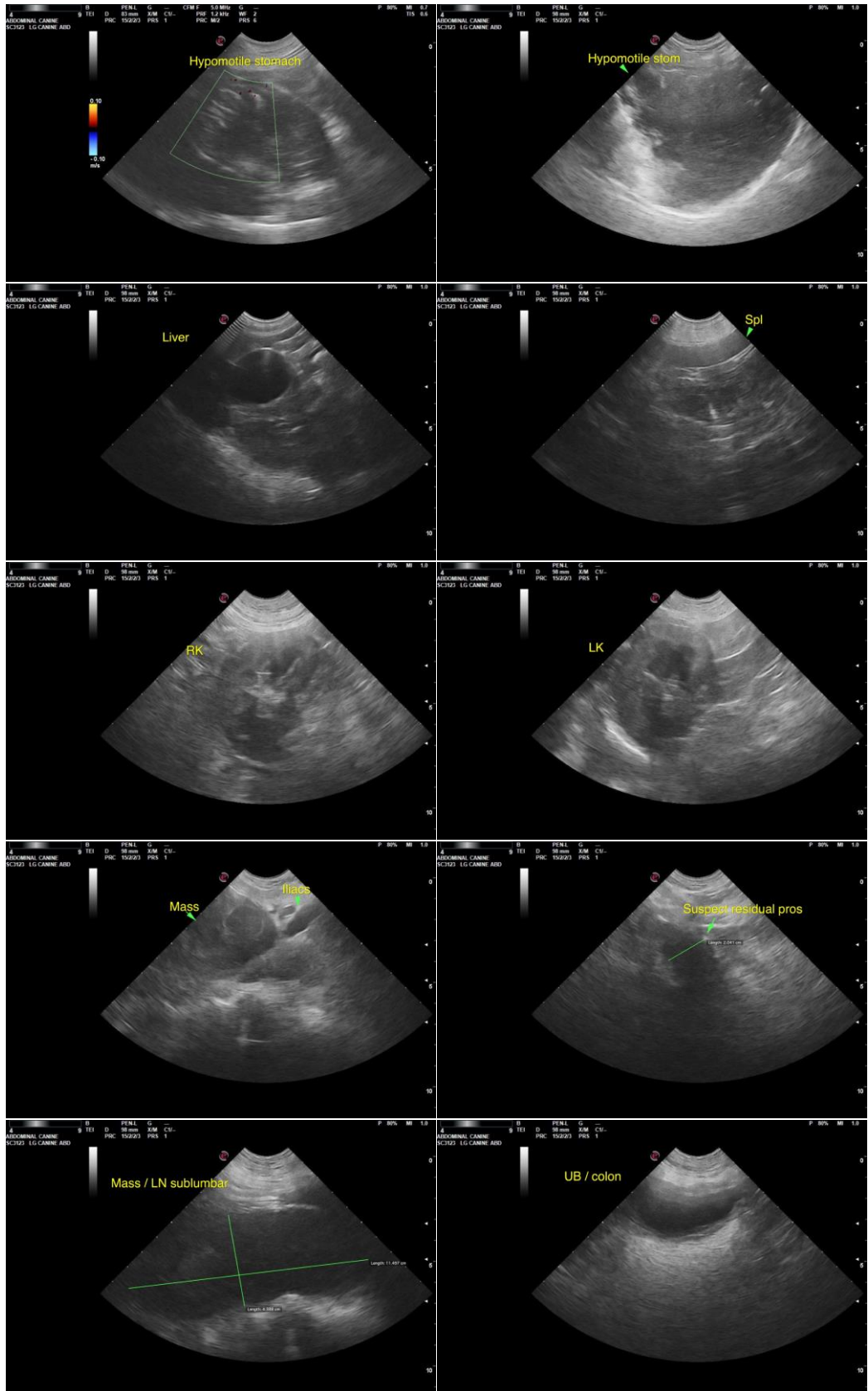
Dr. Crow

INVOICE

10635ag

DATE

05/16/2022





PATIENT

Hank Shopp

The information and recommendations provided are based on the images presented by the referring veterinarian/sonographer. No evaluation can be communicated regarding pathology that was not visible in the image/video clips provided.

SPECIES

Canine

Thank you for this referral. If the clinical or image interpretation does not parallel your findings or if I can be of any further assistance please contact me.

R. McKenzie Daniel, DVM, DABVP (Canine / Feline Practice)

BREED

Bulldog

info@SonoPath.com

SEX

MN

AGE

6 yr

WEIGHT

63 lb

INTERPRETED BY

R. McKenzie Daniel,
DVM, DABVP
(Canine and Feline)

**IMAGING
PERFORMED BY**

Tash

HOSPITAL NAME

Dillsburg VC

REFERRING VET

Dr. Crow

INVOICE

10635ag

DATE

05/16/2022