



## PATIENT

Rex Blakey

## SPECIES

Canine

## BREED

GSD

## SEX

Neutered Male

## AGE

5 Years

## WEIGHT

50 kg

## INTERPRETED BY

R. McKenzie Daniel,  
DVM, DABVP (Canine  
/ Feline Practice)

## IMAGING PERFORMED BY

Dr. Sarah Barthelemy

## HOSPITAL NAME

Argo Vet

## REFERRING VET

Argo Vet

## INVOICE

16182

## DATE

05/13/26

## PRESENTING CLINICAL SIGNS

Lethargy for a few weeks, exercise intolerance has developed, panting. Normal labs. No murmur. Patient received Dexdomitor

## ULTRASONOGRAPHIC EXAMINATION OF THE ABDOMEN

### *Urinary System*

The urinary bladder, trigone, cystourethral junction, and visible pelvic urethra to a depth of 2.0 cm exhibited normal thickness and tone. Anechoic urine was present in the lumen with no uroliths or sediment. The ureteral papillae were normal. The ureters were not visible which is normal. No evidence of inflammatory or neoplastic change were noted.

The area of the residual prostate appeared normal and free of pathology.

Normal size and margination was present in the kidneys. A normal 1:3 cortex / medulla ratio and normal corticomedullary definition were maintained. The echogenicity of the cortex was similar to or slightly less than normal liver parenchyma while the medulla echogenicity was hypoechoic to the cortex with no evidence of pelvic dilation. The left kidney measured 6.4 cm in length. The right kidney measured 7.5 cm in length.

### *Adrenal Glands*

The left and right adrenal glands were not definitively visualized yet no obvious pathology was present.

### *Spleen*

The spleen exhibited a finely textured and homogenous parenchyma which was hyperechoic to the liver and renal cortical parenchyma. The capsule was smooth and regular without apparent expansion. The splenic vasculature at the hilus was normal in volume with no evidence of congestion or thrombosis. Acute to chronic inflammatory, neoplastic, or benign parenchyma changes were not noted.

### *Liver & Gallbladder*

The liver was subjectively normal in size, structure, and contour. The liver parenchyma was uniform and hypoechoic to the spleen with a mild coarse echotexture. The hepatic and portal vasculature were normal in appearance without signs of congestion.

The gallbladder was non-distended in size with thin walls and primarily anechoic luminal content. The cystic and common bile ducts were normal.

### *Gastrointestinal*

The stomach presented intact wall layering with a normal wall layer ratio. The lumen of the stomach contained variably echogenic, primarily mild to moderate nonshadowing ingesta without signs of obstruction or foreign material.

The small intestine presented intact wall layering with 1:3 muscularis/mucosa ratio. Segmental similar appearing mild nonshadowing intestinal ingesta was visualized.

Normal visible colon wall layers were present with apparent formed feces in lumen.



**PATIENT**

**Pancreas**

Rex Blakey

The area of the pancreas was sonographically normal.

**SPECIES**

**Free Abdomen**

Canine

No overt lymphadenopathy or peritoneal effusion was present.

**BREED**

Brief subjective echocardiogram revealed normal left and right cardiac dimension with subjective mild decreased LV contractility, likely secondary to sedation. No overt arrhythmia was present. No evidence of cardiac tumors or pericardial effusion in the visible window.

GSD

**SEX**

Neutered Male

- Sonographically unremarkable abdomen with nonvisualized adrenal glands and gastrointestinal ingesta- ingesta consistent with food echogenicity.
- Subjective normal cardiac structure/function given sedation.

**AGE**

5 Years

**INTERPRETATION OF THE FINDINGS & FURTHER RECOMMENDATIONS**

**WEIGHT**

50 kg

No evidence of abdominal pathology or overt cardiomyopathy as an obvious contributing factor to the patient's clinical signs. Baseline cortisol level is recommended to assess for or rule out occult Addison's disease with full ACTH stimulation test if resting cortisol is less than 2.0. Correlation with thoracic radiographs and neurological/musculoskeletal exam is recommended. Pending additional diagnostics and if persistent clinical signs, full non-sedated echocardiogram and ECG may be considered.

**INTERPRETED BY**

R. McKenzie Daniel,  
DVM, DABVP (Canine  
/ Feline Practice)

**IMAGING PERFORMED BY**

Dr. Sarah Barthelmy

**HOSPITAL NAME**

Argo Vet

**REFERRING VET**

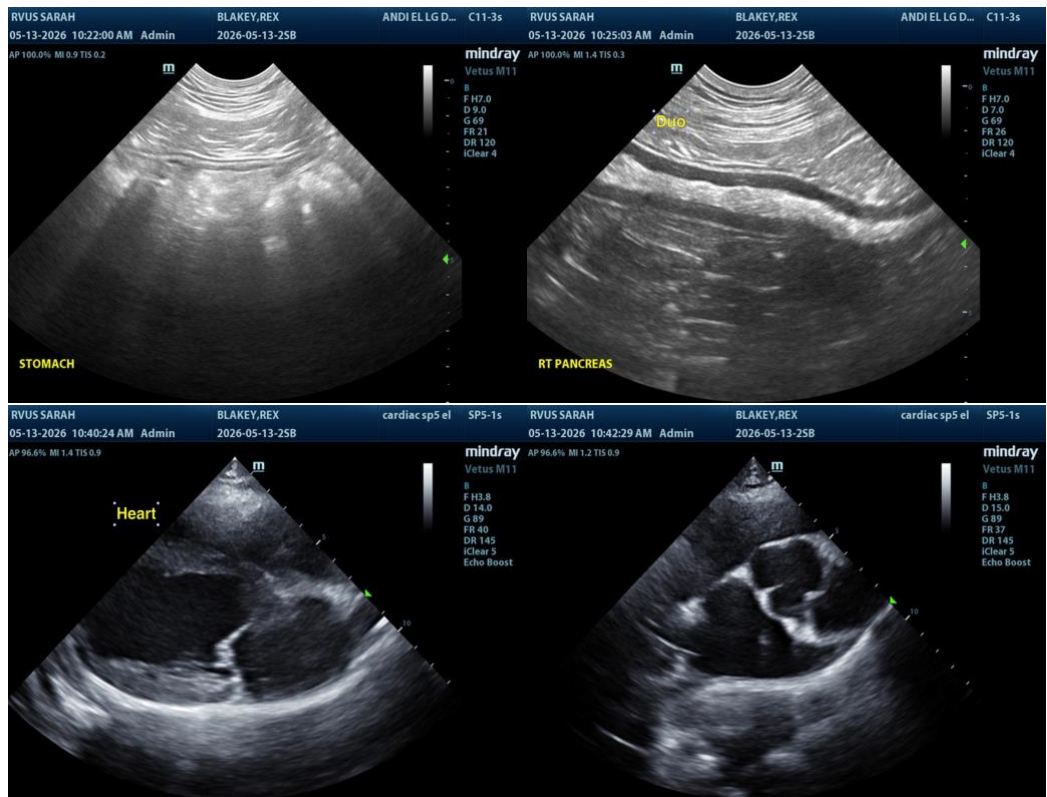
Argo Vet

**INVOICE**

16182

**DATE**

05/13/26





**PATIENT**

Rex Blakey

**SPECIES**

Canine

**BREED**

GSD

**SEX**

Neutered Male

**AGE**

5 Years

**WEIGHT**

50 kg

**INTERPRETED BY**

R. McKenzie Daniel,  
DVM, DABVP (Canine  
/ Feline Practice)

**IMAGING  
PERFORMED BY**

Dr. Sarah Barthelmy

**HOSPITAL NAME**

Argo Vet

**REFERRING VET**

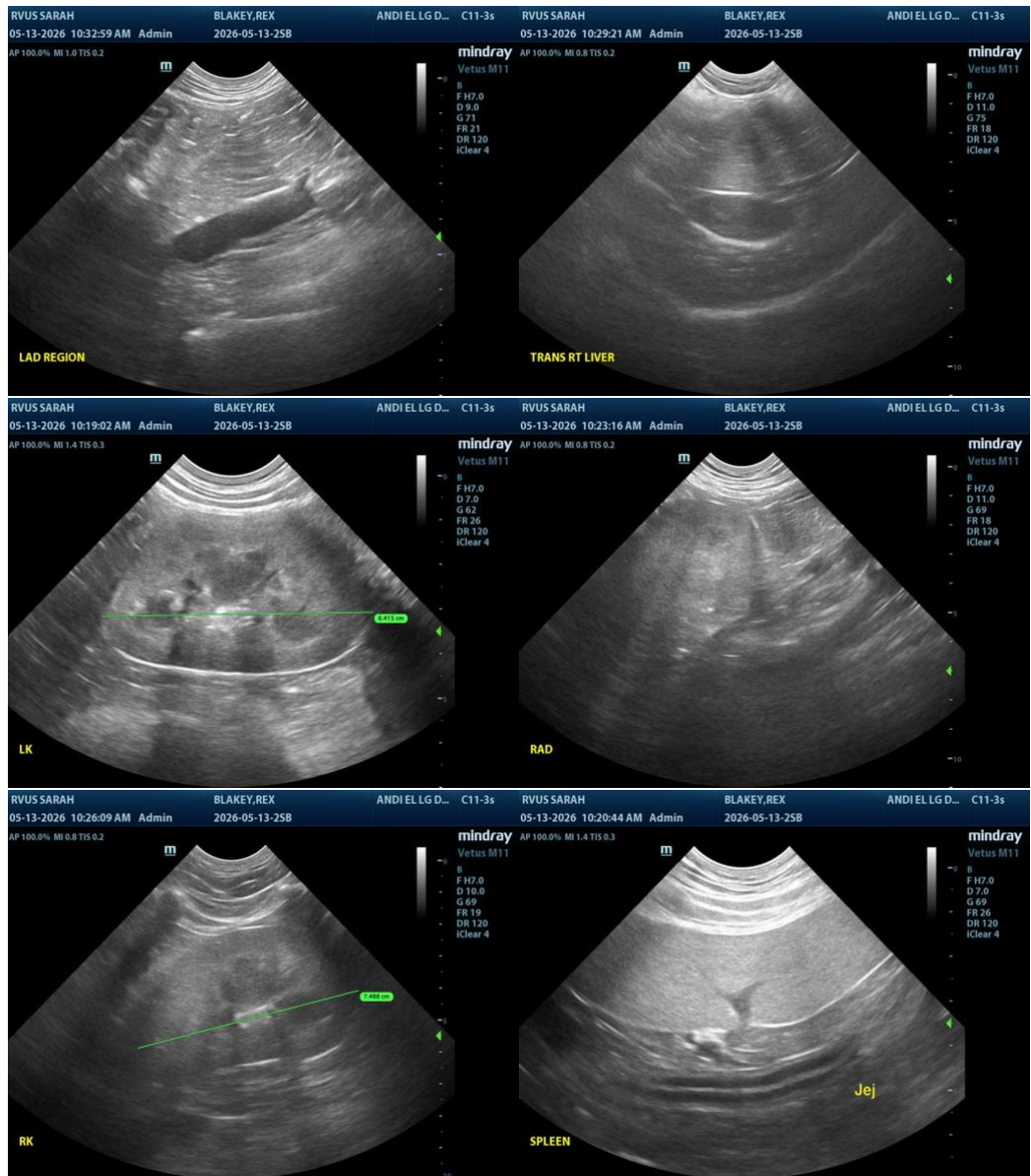
Argo Vet

**INVOICE**

16182

**DATE**

05/13/26



The information and recommendations provided are based on the images presented by the referring veterinarian/sonographer. No evaluation can be communicated regarding pathology that was not visible in the image/video clips provided.

Thank you for this referral. If the clinical or image interpretation does not parallel your findings or if I can be of any further assistance, please contact me.

R. McKenzie Daniel, DVM, DABVP (Canine / Feline Practice)

[info@SonoPath.com](mailto:info@SonoPath.com)