

PATIENT PRESENTING CLINICAL SIGNS

Romeo Oldham History: Vomiting and Diarrhea for ~1 month, weight loss, inappetence

SPECIES Abnormal PE/Chem/CBC/UA Results: CBC wnl Chems: SDMA 23 (0-14) Creat: 1.2 (0.9-2.3) BUN: 38 (16-37) TP: 5.7 (6.3-8.8) Lipase: 81 (0-45) UA: Spec Grav: 1.051 TT4 wnl A: Dehydration with good urine concentration. Suspect GI protein loss Current Medications Vit B-12 injections, Methylprednisolone injections

Feline

BREED

DSH

ULTRASONOGRAPHIC EXAMINATION OF THE ABDOMEN

SEX

Urinary System

MN

The urinary bladder, trigone, cystourethral junction, and visible pelvic urethra to a depth of 2 cm exhibited normal thickness and tone. Anechoic urine was present in the lumen with no uroliths or sediment. The ureteral papillae were normal. The ureters were not visible which is normal. No evidence of inflammatory or neoplastic changes were noted.

AGE

16 yr

Normal renal size with asymmetrical margination was present in both kidneys. The renal cortex presented uniformly increased in echogenicity with uniform echotexture. The renal cortex appeared to be hypertrophied resulting in an altered cortex: medulla ratio. Mild loss of corticomedullary distinction was also present. The renal medullary volume was subjectively reduced. The left kidney measured 4.6 cm in length. The right kidney measured 4.0 cm in length.

WEIGHT

10 lb

INTERPRETED BY

R. McKenzie Daniel,
DVM, DABVP
(Canine and Feline)

The area of the aortic trifurcation was free of pathology.

Adrenal Glands

The left adrenal gland was uniform in size and contour with a uniformly hypoechoic parenchyma. The left adrenal gland measured 0.41 cm width. The right adrenal gland was uniform in size and contour with a uniformly hypoechoic parenchyma. The right adrenal gland measured 0.28 cm width.

IMAGING PERFORMED BY

Sara Hansen

Spleen

The spleen exhibited a finely textured and homogenous parenchyma which was hyperechoic to the liver and renal cortical parenchyma. The capsule was smooth and regular without apparent expansion. The splenic vasculature at the hilus was normal in volume with no evidence of congestion or thrombosis. Acute to chronic inflammatory, neoplastic, or benign parenchyma changes were not noted. The spleen measured 0.89 cm in width.

HOSPITAL NAME

Willakenzie Animal
Clinic

REFERRING VET

Dr. Kairis

Liver

The liver was subjectively normal in size, structure, and contour. The liver parenchyma was uniform and hypoechoic to the spleen with a mild coarse echotexture. The hepatic and portal vasculature were normal in appearance without signs of congestion. The gallbladder was non-distended in size with thin walls and primarily anechoic luminal content. The cystic and common bile ducts were normal.

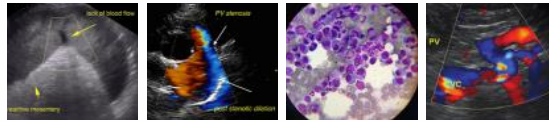
INVOICE

10606ag

Gastrointestinal

DATE

05/13/2022



PATIENT	The stomach presented intact wall layering with a normal wall layer ratio. The lumen of the stomach was empty with no signs of ileus, obstruction or foreign material. The gastric body wall measured 0.25 cm in width.
Romeo Oldham	
SPECIES	The small intestine exhibited generalized thickened wall layering owing to propensity for mildly prominent muscularis layer. The segmental duodenum and jejunum exhibited moderate hypoechoic mural hypertrophy with loss of discernable wall layering. The duodenum wall measured up to 0.48 cm in width. The segmental jejunum measured up to 0.46 cm in width in the area of hypertrophy. By comparison, intact jejunal wall layering measured 0.3 cm width.
Feline	
BREED	Normal visible colon wall layers were present with apparent formed feces in lumen.
DSH	
SEX	Pancreas
MN	The left limb, right limb, and base of the pancreas presented hypoechoic to heterogeneous echogenicity compared to adjacent omental fat. Mild asymmetrical capsule margination was present with mild variable parenchymal swelling and mild peripancreatic reactivity / inflammation. No overt evidence of neoplasia.
AGE	Free Abdomen
16 yr	Multiple prominent hypoechoic to swollen mesenteric lymph nodes were present in the cranial and mid abdominal mesentery. An example of cranial omental node measured 1.9 cm x 1.7 cm. An example of mid abdominal node measured 3.1 cm x 1.1 cm. A cranial node was noted caudal to the pylorus and appeared to potentially overlay the area of the pancreas base and right pancreatic limb. The possibility of pancreatic nodular lesion to small mass is possible yet thought less likely.
WEIGHT	
10 lb	
INTERPRETED BY	Transdiaphragmatic view of the caudal thorax revealed potential for small volume pleural effusion although not definitive.
R. McKenzie Daniel, DVM, DABVP (Canine and Feline)	
IMAGING PERFORMED BY	ULTRASONOGRAPHIC FINDINGS
Sara Hansen	<ul style="list-style-type: none">• Infiltrative enteropathy pattern with emerging duodenal and jejunal mural masses• Associated mesenteric lymphadenopathy• Pancreatitis• Mild chronic renal changes
HOSPITAL NAME	INTERPRETATION OF THE FINDINGS & FURTHER RECOMMENDATIONS
Willakenzie Animal Clinic	Primary consideration for the intestinal presentation may include inflammatory enteropathy/IBD or neoplastic infiltrative enteropathy with round cells such as lymphoma with dry form FIP considered a less likely differential diagnosis. The lymph nodes may indicate associated lymphoid hyperplasia, reactive lymphadenitis or neoplastic lymphadenopathy. Given the appearance of the mesentery lymph nodes as well as the emerging duodenal and jejunal mural masses, higher probability of neoplastic enteropathy i.e. lymphoma is favored. An ultrasound guided FNA of an enlarged mesenteric lymph node could be considered for screening cytology. Full thickness intestinal biopsy may be required for a definitive diagnosis. Empirically, continued IBD/pancreatitis protocol would be reasonable.
REFERRING VET	Assessment of GI panel and three view chest radiographs to rule out occult thoracic pathology as a contributing factor to the patient's weight loss is recommended. A guarded prognosis is indicated.
Dr. Kairis	
INVOICE	
10606ag	
DATE	
05/13/2022	



PATIENT

Romeo Oldham

SPECIES

Feline

BREED

DSH

SEX

MN

AGE

16 yr

WEIGHT

10 lb

INTERPRETED BY

R. McKenzie Daniel,
DVM, DABVP
(Canine and Feline)

IMAGING PERFORMED BY

Sara Hansen

HOSPITAL NAME

Willakenzie Animal
Clinic

REFERRING VET

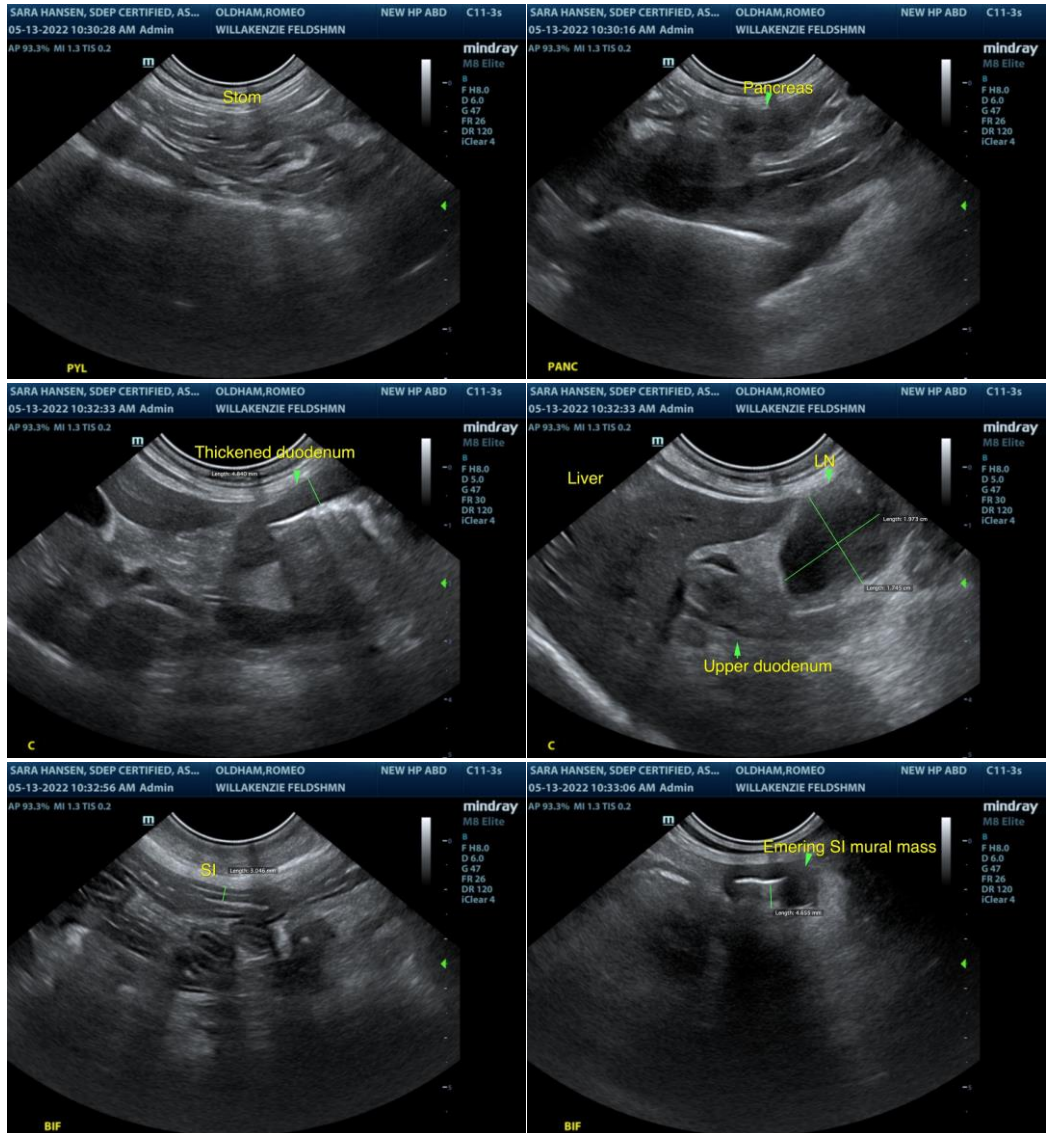
Dr. Kairis

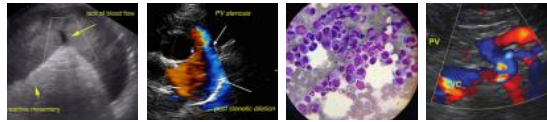
INVOICE

10606ag

DATE

05/13/2022





PATIENT

Romeo Oldham

SPECIES

Feline

BREED

DSH

SEX

MN

AGE

16 yr

WEIGHT

10 lb

INTERPRETED BY

R. McKenzie Daniel,
DVM, DABVP
(Canine and Feline)

IMAGING PERFORMED BY

Sara Hansen

HOSPITAL NAME

Willakenzie Animal
Clinic

REFERRING VET

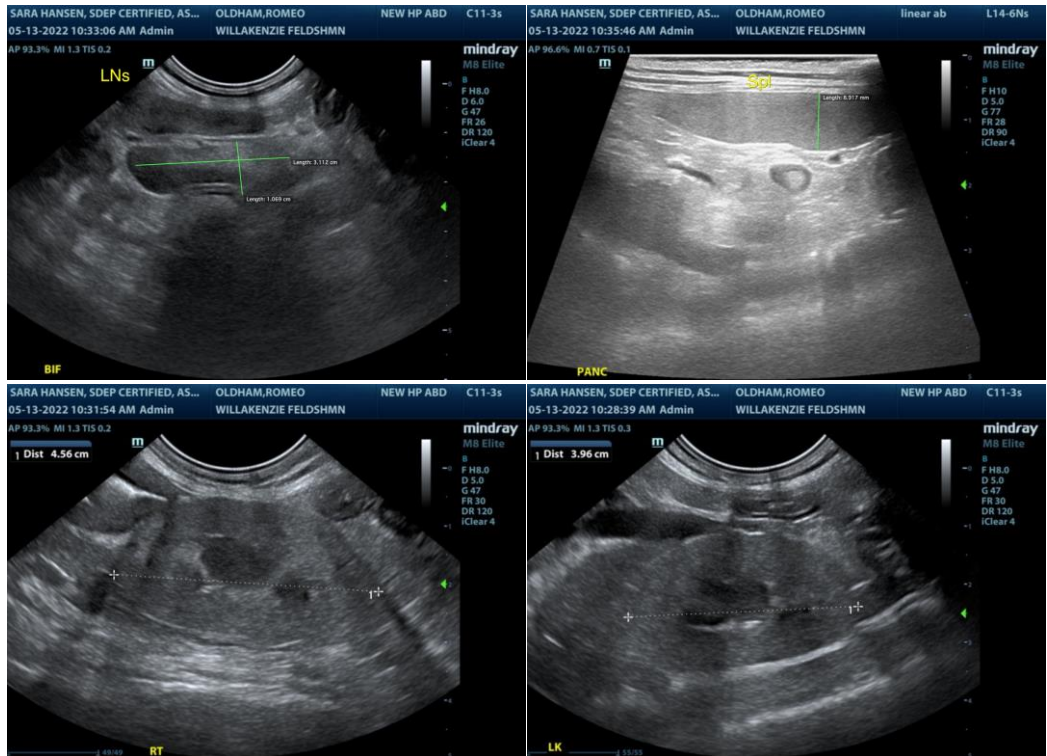
Dr. Kairis

INVOICE

10606ag

DATE

05/13/2022



The information and recommendations provided are based on the images presented by the referring veterinarian/sonographer. No evaluation can be communicated regarding pathology that was not visible in the image/video clips provided.

Thank you for this referral. If the clinical or image interpretation does not parallel your findings or if I can be of any further assistance please contact me.

R. McKenzie Daniel, DVM, DABVP (Canine / Feline Practice)

info@SonoPath.com