



**PATIENT PRESENTING CLINICAL SIGNS**

**Brynn Rudy** History: Enlarge popliteal LNs, suspected MCT on cytology . Staging screening before Onco appointment . Borderline non regenerative anemia

**SPECIES** Abnormal PE/Chem/CBC/UA Results: RBC 5.3 5.4 - 8.7 x10<sup>12</sup>/L Hematocrit 0.35 0.38 - 0.57 L/L Hemoglobin. 122 134 - 207 g/L IDEXX SDMA. 15 0 - 14 µg/dL Creatinine 118 44 - 159 µmol/L Urea (BUN) 10.8 2.5 - 9.6 mmol/L ALT 234 10 - 125 U/L ALP 317 23 - 212 U/L Globulin 48 25 - 45 g/L Cholesterol 12.36. 2.84 - 8.26 mmol/L Total T4. < 6 13 - 51 nmol/L cTSH. 3.35 0.05 - 0.60 ng/mL

**BREED ULTRASONOGRAPHIC EXAMINATION OF THE ABDOMEN**

Shetland Sheepdog

**Urinary System**

**SEX** The urinary bladder, trigone, cystourethral junction, and visible pelvic urethra to a depth of 3 cm exhibited normal thickness and tone. Anechoic urine was present in the lumen with no uroliths or sediment. The ureteral papillae were normal. The ureters were not visible which is normal. No evidence of inflammatory or neoplastic changes were noted.

**AGE** Normal size and margination were present in the kidneys. A normal 1:3 cortex / medulla ratio and normal corticomedullary definition were maintained. The echogenicity of the cortex was similar to or slightly less than normal liver parenchyma while the medulla echogenicity was hypoechoic to the cortex with no evidence of pelvic dilation. The left kidney measured 6.0 cm in length. The right kidney measured 5.8 cm in length.

7

**WEIGHT** The area of the aortic trifurcation was free of pathology.

24 kg

No overt pathology in the area of the residual prostate.

**INTERPRETED BY Adrenal Glands**

R. McKenzie Daniel, DVM, DABVP (Canine and Feline) The left adrenal gland was uniform in size and contour with a uniformly hypoechoic parenchyma. The left adrenal gland measured 0.65 cm width at the caudal pole and 0.52 cm width at the cranial pole. The right adrenal gland was uniform in size and contour with a uniformly hypoechoic parenchyma. The right adrenal gland measured 0.45 cm width at the caudal pole and 0.67 cm width at the cranial pole.

**IMAGING PERFORMED BY Spleen**

Stan Gira The spleen exhibited a finely textured and homogenous parenchyma which was hyperechoic to the liver and renal cortical parenchyma. The capsule was smooth and regular without apparent expansion.

**HOSPITAL NAME** The splenic vasculature at the hilus was normal in volume with no evidence of congestion or thrombosis. Acute to chronic inflammatory, neoplastic, or benign parenchyma changes were not noted.

Resolution Veterinary Ultrasound

**Liver**

**REFERRING VET** The liver was mildly enlarged with normal structure and contour. Nonhomogeneous hepatic parenchyma with multifocal nonexpansive subtly hypoechoic parenchymal nodules were present. The gallbladder was non-distended in size with thin walls and primarily anechoic luminal content with moderate nondependent to subtly organized luminal debris. Intermittent hypoechoic areas noted between the nondependent debris and inner luminal wall suggestive of mucus were present. The cystic and common bile ducts were normal.

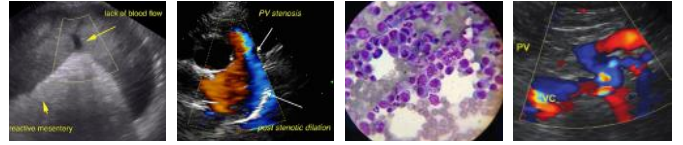
Dr. Stan Gira

**INVOICE**

10609ag

**DATE**

05/13/2022



**PATIENT** *Gastrointestinal*

Brynn Rudy The stomach presented intact wall layering with a normal wall layer ratio. The lumen of the stomach was empty with no signs of ileus, obstruction or foreign material.

**SPECIES** The small intestine presented intact wall layering with 1:3 muscularis/mucosa ratio. The lumen of the small intestine was empty with no signs of ileus, obstruction or foreign material.

Canine Normal visible colon wall layers were present with apparent formed feces in lumen.

**BREED** *Pancreas*

Shetland Sheepdog The parenchyma of the left limb, body and right limb of the pancreas presented isoechoic to the adjacent omental fat. A normal curvilinear capsule contour of the pancreas was present. The visible pancreatic duct was normal. No signs of active inflammation or neoplastic disease was evident.

**SEX** *Free Abdomen*

MN No omental masses, overt lymphadenopathy or peritoneal effusion was present.

**AGE** **ULTRASONOGRAPHIC FINDINGS**

7

- WEIGHT**
- Hepatopathy exhibiting non homogeneous to nodular parenchyma
  - Moderate nondependent gallbladder debris and suspect concurrent mucus-early to emerging gallbladder mucocele, subjectively non inflamed

24 kg

**INTERPRETATION OF THE FINDINGS & FURTHER RECOMMENDATIONS**

**INTERPRETED BY**

R. McKenzie Daniel,  
DVM, DABVP  
(Canine and Feline)

The appearance of the liver was nonspecific yet suggestive of potential chronic hepatopathy. Multiple etiologies possible including vacuolar hepatopathy, inflammatory/immune mediated disease with parenchymal remodeling, regenerative hyperplasia, hematopoiesis or fibrosis while the possibility of neoplastic criteria although thought less likely cannot be definitively excluded. Assuming normal clotting status given the patient's history of suspect/confirmed MCT, an ultrasound guided FNA of the liver is warranted for screening cytology. Empirical hepatosupportive medications including Denamarin and Ursodiol may prove beneficial. Sonographic monitoring of the gallbladder if evidence of discomfort on cranial abdominal or subxiphoid palpation or evidence of increasing cholestasis is recommended.

**IMAGING PERFORMED BY**

Stan Gira

**HOSPITAL NAME**

A CBC pathology review could be considered.

Resolution Veterinary  
Ultrasound

**REFERRING VET**

Dr. Stan Gira

**INVOICE**

10609ag

**DATE**

05/13/2022



**PATIENT**

Brynn Rudy

**SPECIES**

Canine

**BREED**

Shetland Sheepdog

**SEX**

MN

**AGE**

7

**WEIGHT**

24 kg

**INTERPRETED BY**

R. McKenzie Daniel,  
DVM, DABVP  
(Canine and Feline)

**IMAGING PERFORMED BY**

Stan Gira

**HOSPITAL NAME**

Resolution Veterinary  
Ultrasound

**REFERRING VET**

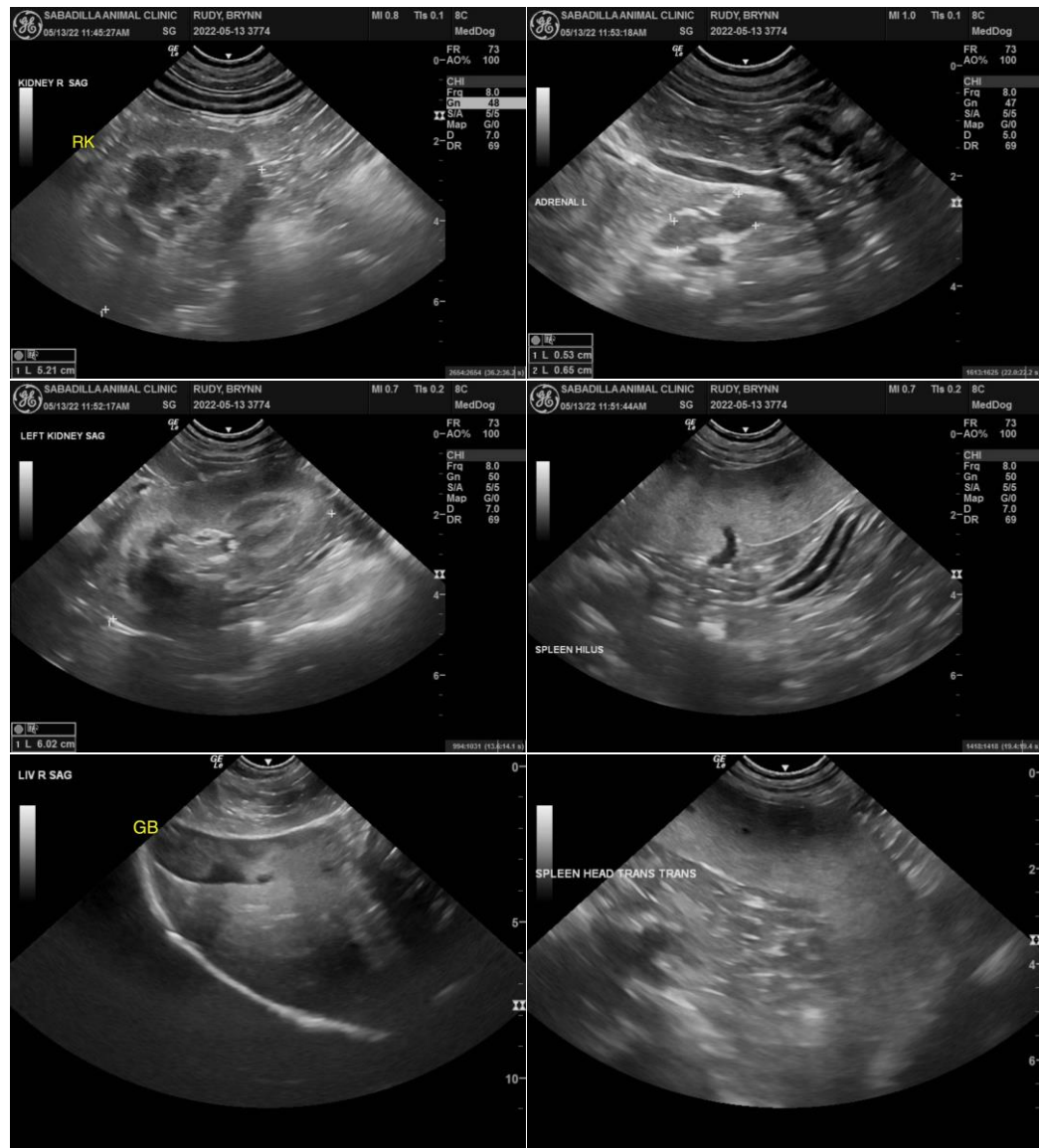
Dr. Stan Gira

**INVOICE**

10609ag

**DATE**

05/13/2022





**PATIENT**

Brynn Rudy

**SPECIES**

Canine

**BREED**

Shetland Sheepdog

**SEX**

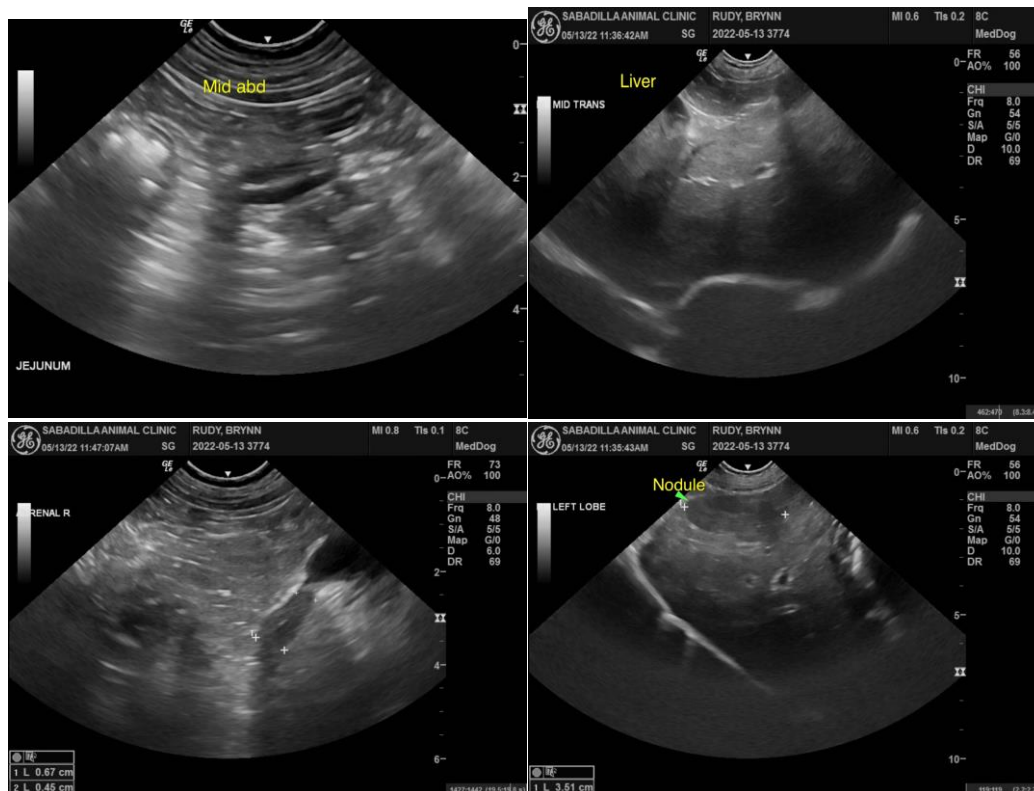
MN

**AGE**

7

**WEIGHT**

24 kg



**INTERPRETED BY**

R. McKenzie Daniel,  
DVM, DABVP  
(Canine and Feline)

**IMAGING  
PERFORMED BY**

Stan Gira

**HOSPITAL NAME**

Resolution Veterinary  
Ultrasound

**REFERRING VET**

Dr. Stan Gira

**INVOICE**

10609ag

**DATE**

05/13/2022

Begin forwarded message:

The information and recommendations provided are based on the images presented by the referring veterinarian/sonographer. No evaluation can be communicated regarding pathology that was not visible in the image/video clips provided.

Thank you for this referral. If the clinical or image interpretation does not parallel your findings or if I can be of any further assistance please contact me.

R. McKenzie Daniel, DVM, DABVP (Canine / Feline Practice)

info@SonoPath.com