



**PATIENT PRESENTING CLINICAL SIGNS**

Max Thompson History: harsh breathing, exercise intolerance, HR 72, no change after exercise, elevated liver enzymes

**SPECIES** Abnormal PE/Chem/CBC/UA Results: ALP 564, ALT 905, glob 46 (25-45) GGT and bili WNL

Canine **ULTRASONOGRAPHIC EXAMINATION OF THE ABDOMEN**

**BREED** *Urinary System*

Lab The urinary bladder, trigone, cystourethral junction, and visible pelvic urethra to a depth of 3 cm exhibited normal thickness and tone. Anechoic urine was present in the lumen with no uroliths or sediment. The ureteral papillae were normal. The ureters were not visible which is normal. No evidence of inflammatory or neoplastic changes were noted.

**SEX** Normal size and margination was present in the kidneys. A normal 1:3 cortex / medulla ratio was maintained. The medulla and cortices were uniform in texture with some increased echogenicity and mild loss of corticomedullary symmetry and definition expected for the age of the patient. No evidence of pelvic dilation was present. The left kidney measured 5.9 cm in length. The right kidney measured 5.5 cm in length.

11 yr The area of the aortic trifurcation was free of pathology.

**WEIGHT** No overt pathology in the area of the residual prostate although indistinctly visualized.

37 kg *Adrenal Glands*

The left adrenal gland was normal in size. Mild parenchyma heterogeneity and mild capsule asymmetry was present without suspicion for overt neoplasia. The left adrenal gland measured 2.8 length and 0.93 cm width in the caudal pole. The right adrenal gland was indistinctly visualized without evidence of overt pathology.

**INTERPRETED BY**

R. McKenzie Daniel,  
DVM, DABVP  
(Canine and Feline)

*Spleen*

**IMAGING PERFORMED BY**

Kelly Reschny

The spleen exhibited a finely textured and homogenous parenchyma which was hyperechoic to the liver and renal cortical parenchyma. The capsule was smooth and regular without apparent expansion. The splenic vasculature at the hilus was normal in volume with no evidence of congestion or thrombosis. Acute to chronic inflammatory, neoplastic, or benign parenchyma changes were not noted.

**HOSPITAL NAME**

New Hamburg VC

*Liver*

**REFERRING VET**

Dr. Findlater

The liver was subjectively normal in size with minor areas of capsule asymmetry and generalized heterogeneous to subtly nodular parenchyma exhibiting moderate coarse echotexture. An example of a nodule measured 1.4 cm in diameter. The gallbladder was non-distended in size with thin walls and primarily anechoic luminal content with minor hyperechoic debris. The cystic and common bile ducts were normal.

**INVOICE** *Gastrointestinal*

10605ag The stomach presented intact wall layering with a normal wall layer ratio. The lumen of the stomach was empty with no signs of ileus, obstruction or foreign material.

**DATE** The small intestine presented intact wall layering with 1:3 muscularis/mucosa ratio. The lumen of the small intestine was empty with no signs of ileus, obstruction or foreign material.



**PATIENT** Normal visible colon wall layers were present with apparent formed feces in lumen.

Max Thompson

**Pancreas**

**SPECIES**

Canine

The parenchyma of the left limb, body and right limb of the pancreas presented isoechoic to the adjacent omental fat. A normal curvilinear capsule contour of the pancreas was present. The visible pancreatic duct was normal. No signs of active inflammation or neoplastic disease was evident.

**Free Abdomen**

**BREED**

Lab

No overt lymphadenopathy or peritoneal effusion was present.

**ULTRASONOGRAPHIC FINDINGS**

**SEX**

MN

- Irregular to heterogeneous nodular liver
- Mild chronic renal changes
- Minor gallbladder debris (non-mucocele)

**INTERPRETATION OF THE FINDINGS & FURTHER RECOMMENDATIONS**

**AGE**

11 yr

**WEIGHT**

37 kg

The hepatic presentation is nonspecific with consideration for chronic inflammatory/immune mediated disease i.e. chronic active hepatitis given the elevated ALT, vacuolar hepatopathy with hepatic parenchymal remodeling, nodular to regenerative hyperplasia, hematopoiesis, fibrosis, chronic toxic hepatopathy i.e. copper with infiltrative neoplasia possible yet thought less likely. Further assessment may include hepatic FNA for screening cytology however surgical core biopsy is likely required for a definitive diagnosis. Hepatosupportive medications including Denamarin and Ursodiol may prove beneficial.

**INTERPRETED BY**

R. McKenzie Daniel,  
DVM, DABVP  
(Canine and Feline)

**IMAGING  
PERFORMED BY**

Kelly Reschny

**HOSPITAL NAME**

New Hamburg VC

**REFERRING VET**

Dr. Findlater

**INVOICE**

10605ag

**DATE**

05/13/2022



**PATIENT**

Max Thompson

**SPECIES**

Canine

**BREED**

Lab

**SEX**

MN

**AGE**

11 yr

**WEIGHT**

37 kg

**INTERPRETED BY**

R. McKenzie Daniel,  
DVM, DABVP  
(Canine and Feline)

**IMAGING  
PERFORMED BY**

Kelly Reschny

**HOSPITAL NAME**

New Hamburg VC

**REFERRING VET**

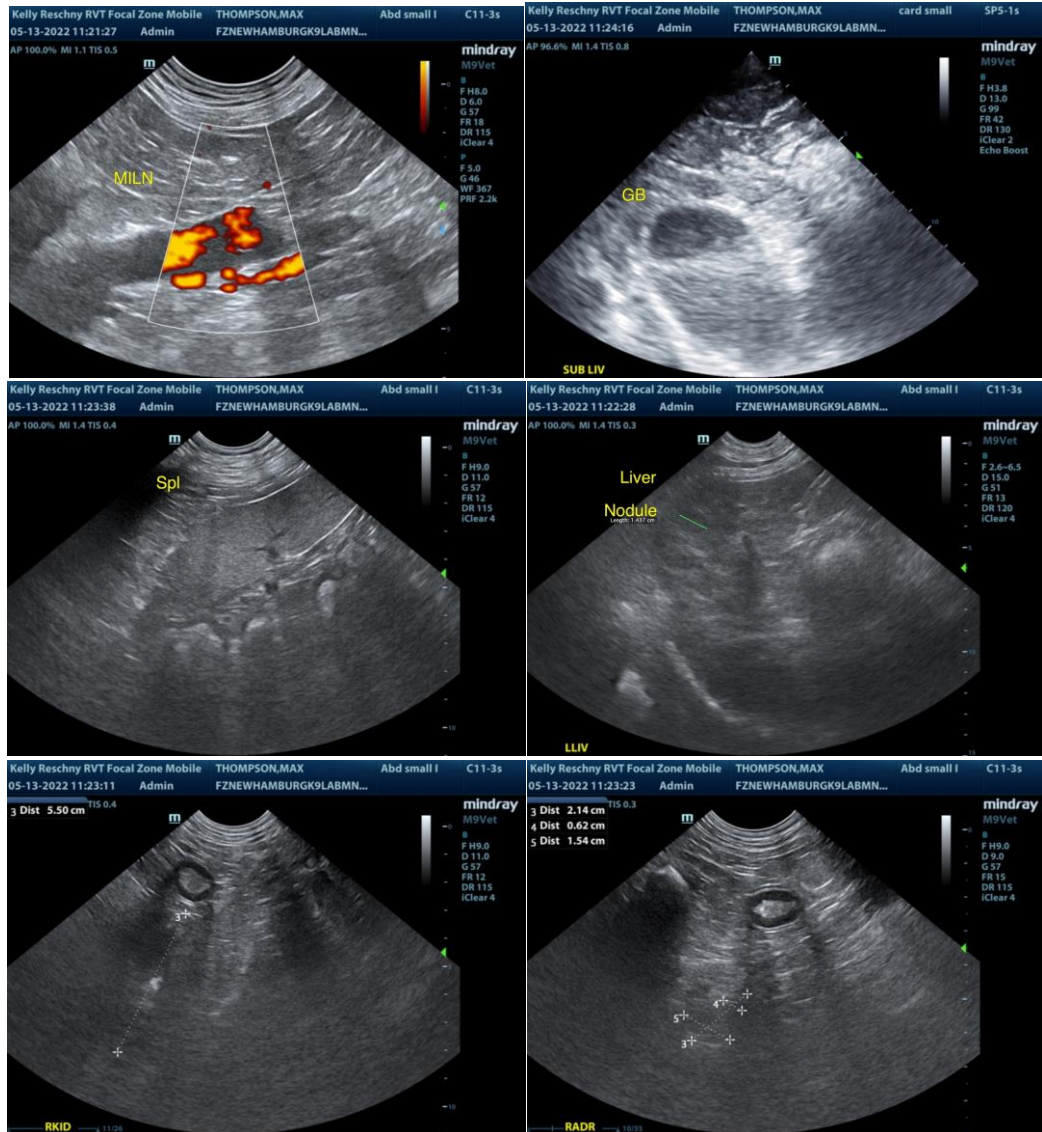
Dr. Findlater

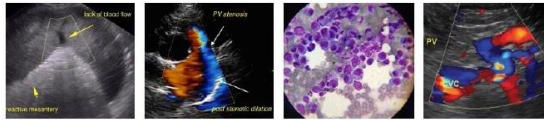
**INVOICE**

10605ag

**DATE**

05/13/2022





**PATIENT**

Max Thompson

**SPECIES**

Canine

**BREED**

Lab

**SEX**

MN

**AGE**

11 yr

**WEIGHT**

37 kg

**INTERPRETED BY**

R. McKenzie Daniel,  
DVM, DABVP  
(Canine and Feline)

**IMAGING PERFORMED BY**

Kelly Reschny

**HOSPITAL NAME**

New Hamburg VC

**REFERRING VET**

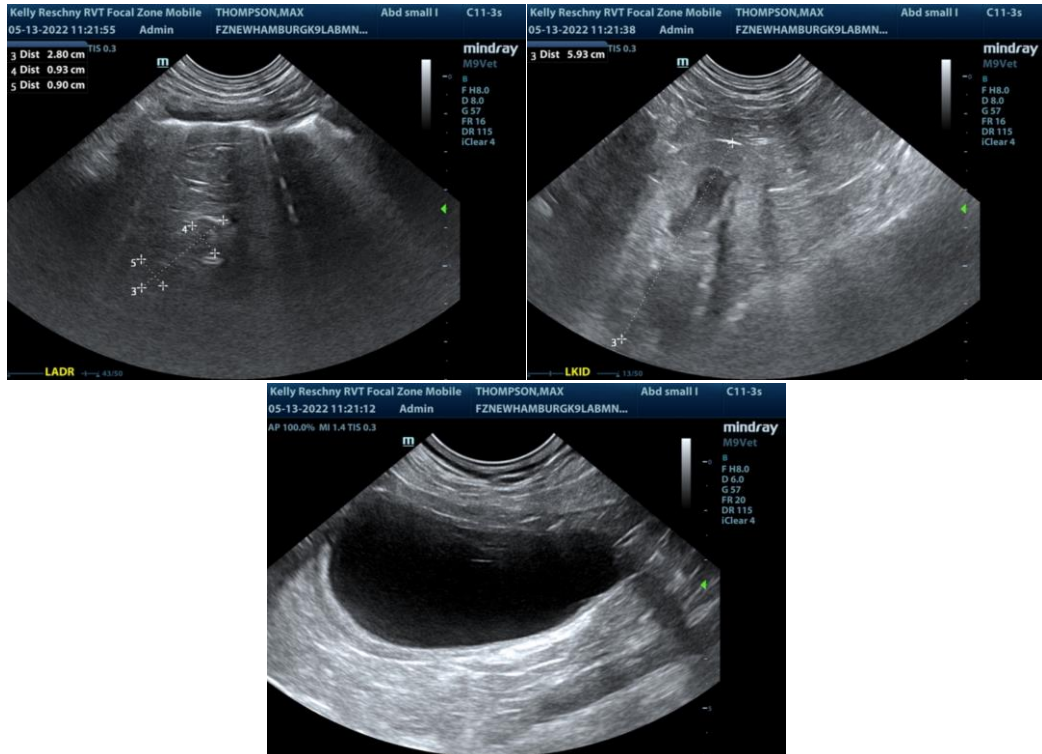
Dr. Findlater

**INVOICE**

10605ag

**DATE**

05/13/2022



The information and recommendations provided are based on the images presented by the referring veterinarian/sonographer. No evaluation can be communicated regarding pathology that was not visible in the image/video clips provided.

Thank you for this referral. If the clinical or image interpretation does not parallel your findings or if I can be of any further assistance please contact me.

R. McKenzie Daniel, DVM, DABVP (Canine / Feline Practice)

info@SonoPath.com