

PATIENT

Nicky Weinstein

SPECIES

Feline

BREED

DSH

SEX

Spayed Female

AGE

5 Years 9 Months

WEIGHT

9.88

INTERPRETED BY

R. McKenzie Daniel,
DVM, DABVP (Canine
/ Feline Practice)

IMAGING PERFORMED BY

Heather

HOSPITAL NAME

Animal Care Clinic of
Flanders

REFERRING VET

Dr. Turner

INVOICE

16122

DATE

05/12/26

PRESENTING CLINICAL SIGNS

Enlarged heart on x-ray, 2/6 systolic ejection murmur L parasternal needs steroids but want to make sure it is safe to use before prescribing

Abnormal PE/Chem/CBC/UA Results: proBNP - 93 t4 10.0, ALT high, methimazole inconsistent

ULTRASONOGRAPHIC EXAMINATION OF THE HEART

FELINE CARDIAC PARAMETERS	BODY WEIGHT	HR (BPM)	IVSd (cm)	LVIDd (cm)	LVWd (cm)	FS (%)	EF (%)
NORMAL PARAMETER	-----	150-240	0.3-0.6	1.0-2.1	0.25-0.6	35-67	80-100
PATIENT	9.88	NM	0.51	1.35	0.51	45	78
FELINE CARDIAC PARAMETERS	LA/AO (M-mode)	LA/AO HEART BASE (Sisson)	LAD LA MAX 4 Chamber	LVOT VEL (m/s)	RVOT VEL (m/s)	IVRT (m/)	
NORMAL PARAMETER	<1.5	1.6	0.7-1.7	<1.6	<1.3	40-60	
PATIENT	NM	1.35	1.5 MAX	NM	1.1	NM	
Adapted from June Boon, Veterinary Echocardiography, 1998 Sisson D et al. JVIM 1991; 5: 232, Jacobs et al. Am J Vet Res 1985; 46:1705							

Cardiac Presentation

The echocardiogram in this patient demonstrated normal **left atrial** size based on 3 separate LA measurements. The cranial and caudal **mitral** valve leaflets presented normal linear structure and kinetics. The **left ventricle** presented normal thicknesses with linear contour and was not dilated nor restricted. The **myocardium** presented normal echogenicity without subjective evidence of significant fibrotic or ischemic disease. **Contractility** of the ventricular walls was adequate and in normal range for this patient evidenced by the fractional shortening measurement and subjective evaluation of the different regions and angles of the myocardium. The **left ventricular outflow** tract demonstrated normal laminar flow and subjective structural integrity. The **right atrium** and auricle revealed normal size, structure and content. No evidence of masses was noted or chamber overload. **Tricuspid** valvular assessment demonstrated adequate linear morphology and kinetics. The **right ventricle** was of normal size (1/3 diameter of LV), chordae structure, myocardial echogenicity and thickness. **Pulmonic** tract assessment revealed normal valve structure, laminar flow, and diameter (approx.1:1 pa/ao ratio). No visible **pericardial** or free pleura fluid was noted or extra cardiac pathology in the visible planes. The cranial **mediastinum and pericardial regions** were free of masses in the visible window.

ULTRASONOGRAPHIC FINDINGS

- Overall normal cardiac structure/function.

INTERPRETATION OF THE FINDINGS & FURTHER RECOMMENDATIONS



PATIENT

Nicky Weinstein

SPECIES

Feline

BREED

DSH

SEX

Spayed Female

AGE

5 Years 9 Months

WEIGHT

9.88

INTERPRETED BY

R. McKenzie Daniel,
DVM, DABVP (Canine
/ Feline Practice)

IMAGING PERFORMED BY

Heather

HOSPITAL NAME

Animal Care Clinic of
Flanders

REFERRING VET

Dr. Turner

INVOICE

16122

DATE

05/12/26

No evidence of clinical issues such as left or right heart chamber enlargement, LV systolic dysfunction, arrhythmia, or definitively visualized significant valvular insufficiencies.

A definitive cause of the murmur was not identified. Assuming no volume changes such as dehydration or anemia, a benign flow murmur is probable. A small nonvisualized flow abnormality is not excluded. Regardless of classification, the hemodynamic effects of the murmur are low. Monitoring of the heart murmur is recommended without indication for cardiac medications. Recheck echocardiogram is recommended in 6-12 months, sooner if murmur intensity increases or clinical signs arise.

No overt contraindications to anesthesia or steroid use with potential complication considered low. Recheck echo is recommended in 6 months if steroid therapy is initiated, sooner if increase in murmur intensity or if clinical signs consistent with heart disease arise. Suggested anesthetic protocol may include opioid or Benzodiazepine pre-med, induction with Propofol or Alfaxalone, and appropriate gas anesthesia with avoidance of alpha 2 agonists.



PATIENT

Nicky Weinstein

SPECIES

Feline

BREED

DSH

SEX

Spayed Female

AGE

5 Years 9 Months

WEIGHT

9.88

INTERPRETED BY

R. McKenzie Daniel, DVM, DABVP (Canine / Feline Practice)

IMAGING PERFORMED BY

Heather

HOSPITAL NAME

Animal Care Clinic of Flanders

REFERRING VET

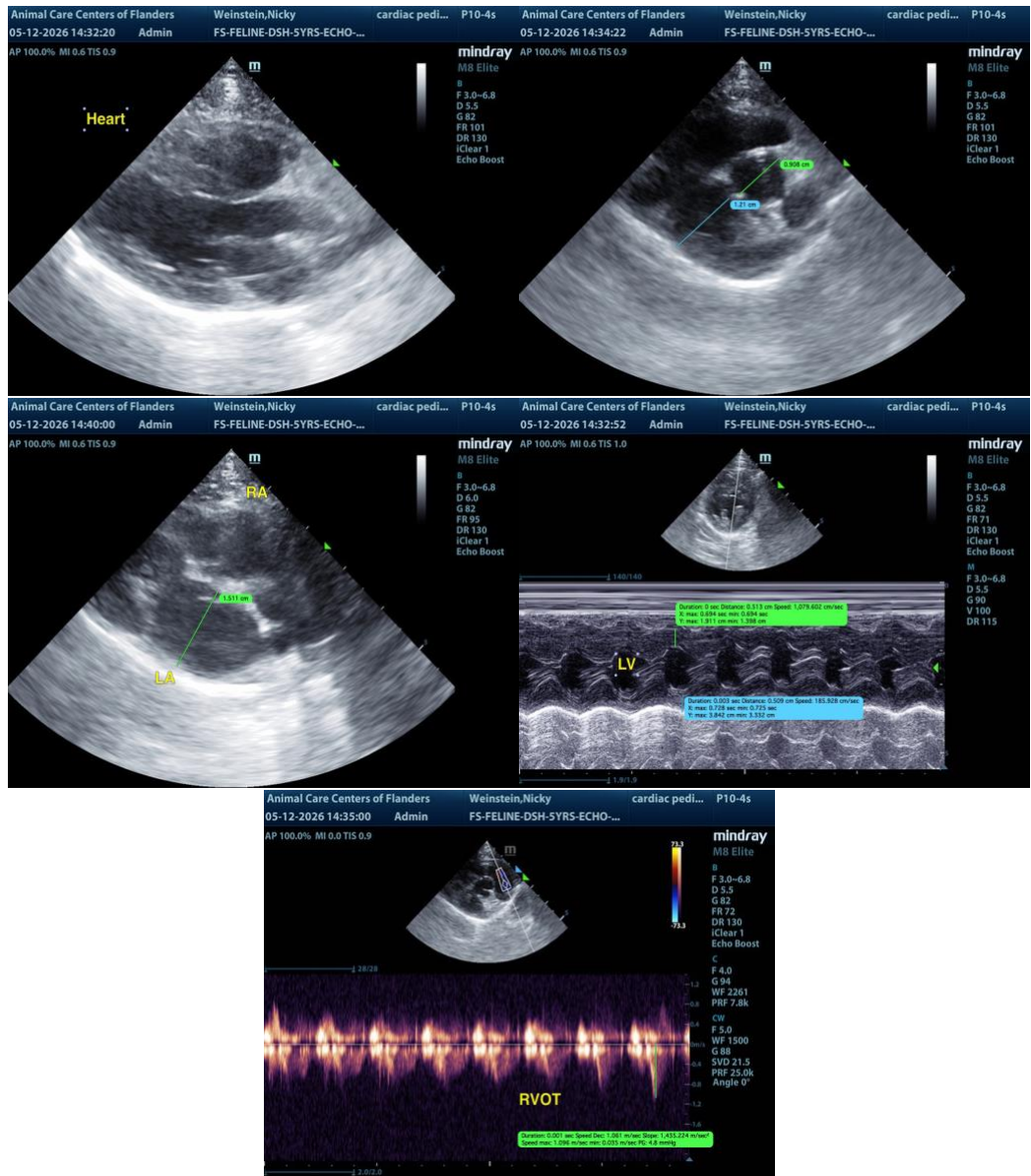
Dr. Turner

INVOICE

16122

DATE

05/12/26



The information and recommendations provided are based on the images presented by the referring veterinarian/sonographer. No evaluation can be communicated regarding pathology that was not visible in the image/video clips provided.

Thank you for this referral. If the clinical or image interpretation does not parallel your findings or if I can be of any further assistance, please contact me.

R. McKenzie Daniel, DVM, DABVP (Canine / Feline Practice)

info@SonoPath.com