

**PATIENT**

Milo Broderick

SPECIES

Canine

BREED

Beagle

SEX

MN

AGE

2 years

WEIGHT

31 lbs.

INTERPRETED BYR. McKenzie Daniel,
DVM, DABVP
(Canine and Feline)**IMAGING
PERFORMED BY**

Sarah Pender, CVT

HOSPITAL NAME

SVS Imaging QC

REFERRING VET

Dr. Elliott

INVOICE

13847

DATE

5/11/22

PRESENTING CLINICAL SIGNS

Hemorrhagic diarrhea periodically for the last several months. Presented again yesterday with the same clinical signs. Started on Metronidazole again. Has a history of indiscriminate eating. Loves to graze. O does her best to prevent these behaviors. Has been treated with panacur and metronidazole multiple times. Fecals always come back NPS. Responsive to Metronidazole, but clinical signs return about a week following the completed course of medication. Defecated formed normal stool prior to scan.

Abnormal PE/Chem/CBC/UA Results: Blood work and abdominal radiographs are unremarkable.

ULTRASONOGRAPHIC EXAMINATION OF THE ABDOMEN**Urinary System**

The urinary bladder, trigone, cystourethral junction, and visible pelvic urethra to a depth of 2.0 cm exhibited normal thickness and tone. Anechoic urine was present in the lumen with no uroliths or sediment. The ureteral papillae were normal. The ureters were not visible which is normal. No evidence of inflammatory or neoplastic changes was noted.

The area of the residual prostate was free of pathology.

The area of the aortic trifurcation was free of pathology.

Normal size and margination were present in the kidneys. A normal 1:3 cortex / medulla ratio and normal corticomedullary definition were maintained. The echogenicity of the cortex was similar to or slightly less than normal liver parenchyma while the medulla echogenicity was hypoechoic to the cortex with no evidence of pelvic dilation. The left kidney measured 5.6 cm in length. The right kidney measured 5.7 cm in length.

Adrenal Glands

The left adrenal gland was uniform in size and contour with a uniformly hypoechoic parenchyma. The left adrenal gland measured 2.0 cm length x 0.53 cm width at the caudal pole. The right adrenal gland was uniform in size and contour with a uniformly hypoechoic parenchyma. The right adrenal gland measured 2.5 cm length x 0.46 cm width at the caudal pole.

Spleen

The spleen exhibited a finely textured and homogenous parenchyma which was hyperechoic to the liver and renal cortical parenchyma. The capsule was smooth and regular without apparent expansion. The splenic vasculature at the hilus was normal in volume with no evidence of congestion or thrombosis. Acute to chronic inflammatory, neoplastic, or benign parenchyma changes were not noted.

Liver/ Gallbladder

The liver was subjectively normal in size, structure, and contour. The liver parenchyma was uniform and hypoechoic to the spleen with a mild coarse echotexture. The hepatic and portal vasculature were normal in appearance without signs of congestion. The gallbladder was non-distended in size with thin walls and primarily anechoic luminal content. The cystic and common bile ducts were normal.

**PATIENT**

Milo Broderick

SPECIES

Canine

BREED

Beagle

SEX

MN

AGE

2 years

WEIGHT

31 lbs.

INTERPRETED BYR. McKenzie Daniel,
DVM, DABVP
(Canine and Feline)**IMAGING
PERFORMED BY**

Sarah Pender, CVT

HOSPITAL NAME

SVS Imaging QC

REFERRING VET

Dr. Elliott

INVOICE

13847

DATE

5/11/22

Gastrointestinal

The stomach presented intact wall layering with a normal wall layer ratio. The lumen of the stomach was empty with no signs of ileus, obstruction, or foreign material. The gastric body wall width measured 0.44 cm.

The small intestine presented intact wall layering with 1:3 muscularis/mucosa ratio. The lumen of the small intestine was empty with no signs of ileus, obstruction, or foreign material. The jejunum wall width measured 0.40 cm.

Normal visible colon wall layers were present with apparent formed feces in lumen.

Pancreas

The parenchyma of the left limb, body, and right limb of the pancreas presented isoechoic to the adjacent omental fat. A normal curvilinear capsule contour of the pancreas was present. The visible pancreatic duct was normal. No signs of active inflammation or neoplastic disease were evident.

Free Abdomen

Intermittent, mildly prominent, midabdominal mesenteric lymph nodes were present. The lymph nodes were essentially isoechoic to adjacent omentum without evidence of peripheral inflammation and maintaining a normal width: length ratio (<0.5). An example of a lymph node measured 0.40 cm width. No effusion was noted.

ULTRASONOGRAPHIC FINDINGS

- Sonographically unremarkable gastrointestinal tract and colon
- Intermittent minor being / reactive mesenteric lymph nodes

INTERPRETATION OF THE FINDINGS & FURTHER RECOMMENDATIONS

Overall, no overt evidence of significant abdominal visceral, specifically gastroenterocolic, pathology.

Given the reported hemorrhagic diarrhea, intermittent colitis is suspected although the possibility of structurally insignificant inflammatory gastroenteropathy could be a contributing factor. In patients with recurrent gastrointestinal signs, dysbiosis, dietary indiscretion / food allergy (potential primary consideration in this patient given the history of dietary indiscretion), structurally insignificant inflammatory bowel / colitis, or occult parasitism could be possible.

Empirically, a limited antigen or hydrolyzed diet trial with potential long term dietary therapy, prophylactic deworming (Panacur 50 mg/kg SID x 5 consecutive days with repeat protocol in 3 weeks even if fecal testing is negative), high colony count probiotic (Provable or Visbiome), antibiotic trial and as needed gastrointestinal support with assessment of clinical response may prove beneficial.

IMAGING PERFORMED BY

svsmobileimaging.com 309-737-3070



Clinical Sonography & Telectyology

EDUCATIONAL TELECONSULTATION SERVICES™

1-800-838-4268 info@sonopath.com SonoPath.com

PATIENT

Milo Broderick

SPECIES

Canine

BREED

Beagle

SEX

MN

AGE

2 years

WEIGHT

31 lbs.

INTERPRETED BY

R. McKenzie Daniel, DVM, DABVP (Canine and Feline)

IMAGING PERFORMED BY

Sarah Pender, CVT

HOSPITAL NAME

SVS Imaging QC

REFERRING VET

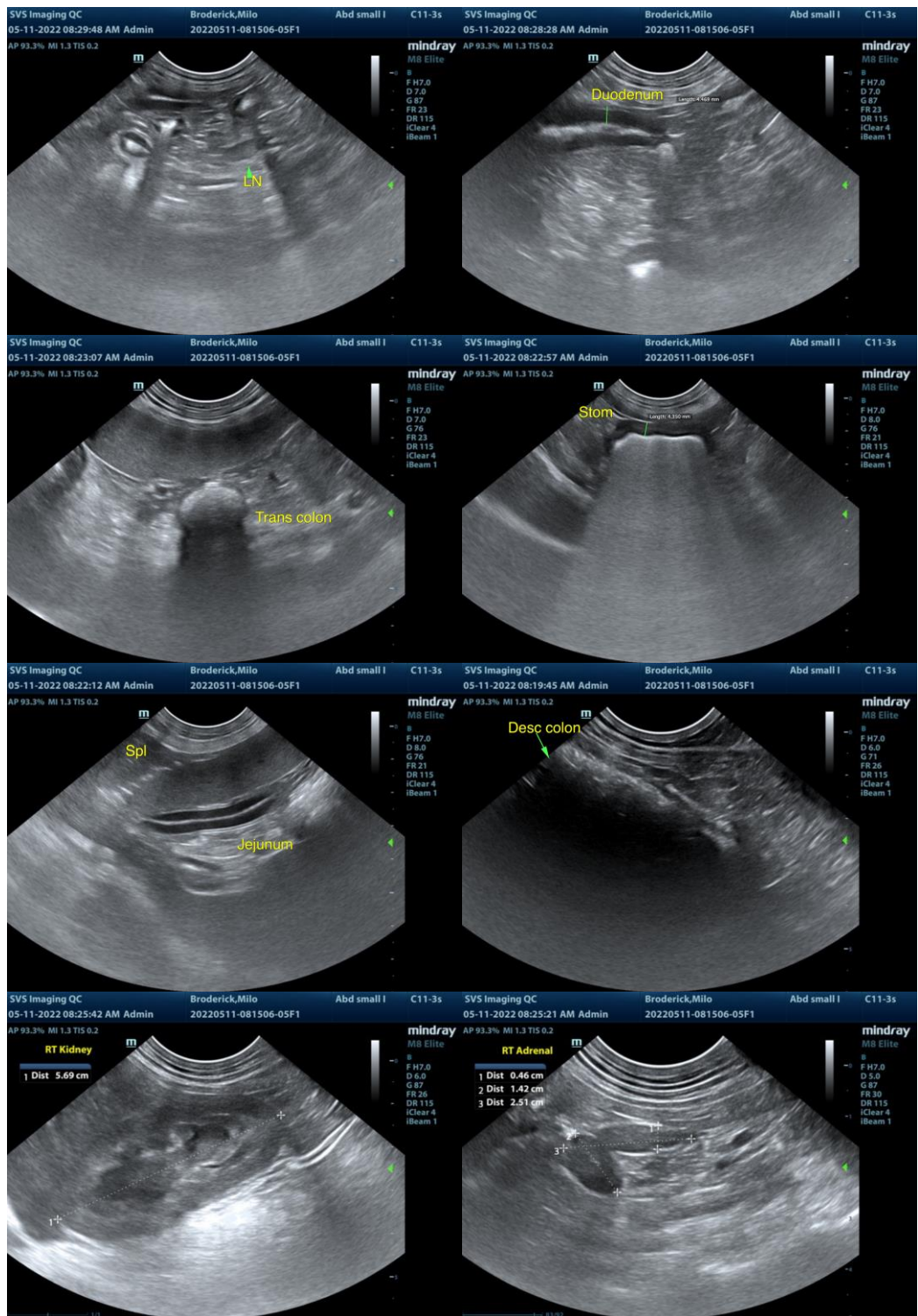
Dr. Elliott

INVOICE

13847

DATE

5/11/22



IMAGING PERFORMED BY

svsmobileimaging.com 309-737-3070



PATIENT

Milo Broderick

SPECIES

Canine

BREED

Beagle

SEX

MN

AGE

2 years

WEIGHT

31 lbs.

INTERPRETED BY

R. McKenzie Daniel,
DVM, DABVP
(Canine and Feline)

IMAGING PERFORMED BY

Sarah Pender, CVT

HOSPITAL NAME

SVS Imaging QC

REFERRING VET

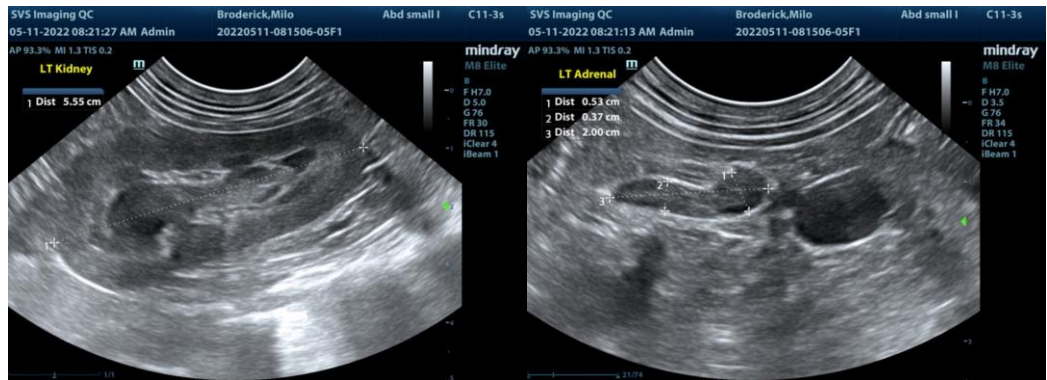
Dr. Elliott

INVOICE

13847

DATE

5/11/22



The information and recommendations provided are based on the images presented by the referring veterinarian/sonographer. No evaluation can be communicated regarding pathology that was not visible in the image/video clips provided.

Thank you for this referral. If the clinical or image interpretation does not parallel your findings or if I can be of any further assistance please contact me.

R. McKenzie Daniel, DVM, DABVP (Canine / Feline Practice)
info@SonoPath.com