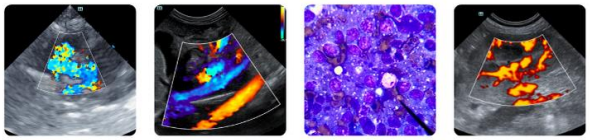

PATIENT
Snowy Chakrabarti

SPECIES
Feline

BREED
Siamese X

SEX
MN

AGE
2.5 yo

WEIGHT
10.62 lbs.

INTERPRETED BY
R. McKenzie Daniel, DVM, DABVP (Canine and Feline)

IMAGING PERFORMED BY
Christa Williams, DVM, DABVP

HOSPITAL NAME
Caravan Vet

REFERRING VET
Christa Williams, DVM, DABVP

INVOICE
10790

DATE
4/9/26

PRESENTING CLINICAL SIGNS

Cat has had persistent hematuria since Sept of 2025. There has been no improvement on a Urinary + Calm food and urine cultures have been negative. Cat is asymptomatic and renal values are normal. Urine sediment is quiet except for >100 RBC's/hpf. Urine is grossly ice-tea colored.

Abnormal PE/Chem/CBC/UA Results: Normal PE and litterbox behaviors. Creatinine 1.4, SDMA 11, USG 1.052, RBC's > 100/hpf, sediment quiet otherwise. Urine culture negative. CBC WNL

ULTRASONOGRAPHIC EXAMINATION OF THE ABDOMEN

Urinary System

The urinary bladder, trigone, cystourethral junction, and visible pelvic urethra to a depth of 2.0 cm exhibited normal thickness and tone. Anechoic urine was present in the lumen with minor dependent lumen hyperechoic sediment / sand. The ureteral papillae were normal. The ureters were not visible which is normal. No evidence of inflammatory or neoplastic changes were noted.

No evidence of pathology in the area of the aortic trifurcation.

Normal size and margination were present in the kidneys. A normal 1:3 cortex / medulla ratio and normal corticomedullary definition were maintained. The echogenicity of the cortex was similar to or slightly less than normal liver parenchyma while the medulla echogenicity was hypoechoic to the cortex with no evidence of pelvic dilation. No evidence of pyelectasia was noted in either kidney. The left kidney measured 3.9 cm in length. The right kidney measured 3.7 cm in length.

Adrenal Glands

The left and right adrenal glands were overtly normal in size, position, and shape. The left adrenal gland subjectively measured 0.30 cm width and the right adrenal gland subjectively measured 0.34 cm width.

Spleen

The spleen exhibited a finely textured and homogenous parenchyma which was hyperechoic to the liver and renal cortical parenchyma. The capsule was smooth and regular without apparent expansion. The splenic vasculature at the hilus was normal in volume with no evidence of congestion or thrombosis. Acute to chronic inflammatory, neoplastic, or benign parenchyma changes were not noted.

Liver/ Gallbladder

The liver was subjectively normal in size, structure, and contour. Normal hepatic vascular volume was present. The liver parenchyma was uniform and hypoechoic to the spleen with a mild coarse echotexture. The hepatic and portal vasculature were normal in appearance without signs of congestion. The gallbladder was non-distended in size with thin walls and primarily anechoic luminal content. The cystic and common bile ducts were normal.

Gastrointestinal

The stomach presented intact wall layering with a normal wall layer ratio. The lumen of the stomach was empty without evidence of retained ingesta, fluid, or foreign material.

PATIENT
Snowy Chakrabarti

SPECIES
Feline

BREED
Siamese X

SEX
MN

AGE
2.5 yo

WEIGHT
10.62 lbs.

INTERPRETED BY
R. McKenzie Daniel, DVM, DABVP (Canine and Feline)

IMAGING PERFORMED BY
Christa Williams, DVM, DABVP

HOSPITAL NAME
Caravan Vet

REFERRING VET
Christa Williams, DVM, DABVP

INVOICE
10790

DATE
4/9/26

The small intestine presented intact wall layering with 1:3 muscularis/mucosa ratio. The lumen of the small intestine was empty with no signs of ileus, obstruction, or foreign material.

Normal visible colon wall layers were present with formed feces in lumen.

Pancreas

The parenchyma of the left limb, body and right limb of the pancreas presented isoechoic to the adjacent omental fat. A normal curvilinear capsule contour of the pancreas was present. The visible pancreatic duct was normal. No signs of active inflammation or neoplastic disease was evident.

Free Abdomen

No overt lymphadenopathy or peritoneal effusion was present.

ULTRASONOGRAPHIC FINDINGS

- Sonographically normal urinary bladder and visible proximal urethra with minor lumen sediment / sand
- Sonographically normal bilateral kidneys

INTERPRETATION OF THE FINDINGS & FURTHER RECOMMENDATIONS

There is no sonographic evidence of upper or lower urinary tract pathology. A definitive cause of the hematuria was not obvious. Low-grade idiopathic cystitis may essentially present as sonographically normal. Assessment of systemic BP for evidence of hypertension is recommended.

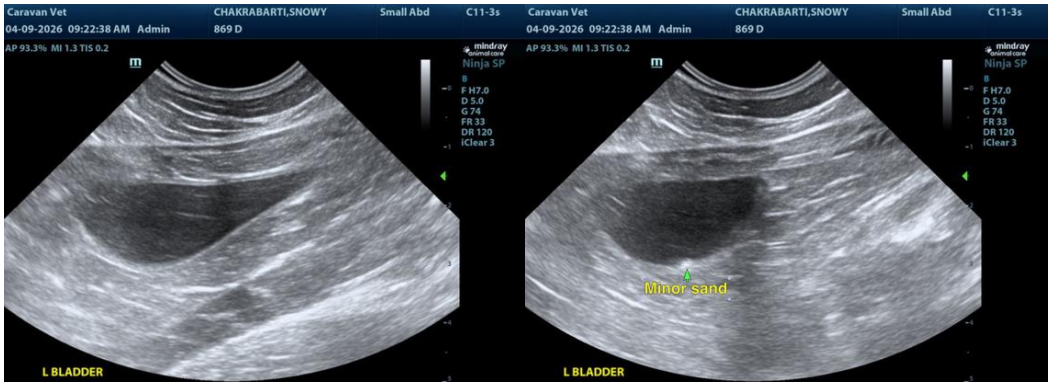

PATIENT

Snowy Chakrabarti

SPECIES

Feline

BREED

Siamese X

SEX

MN

AGE

2.5 yo

WEIGHT

10.62 lbs.

INTERPRETED BY

R. McKenzie Daniel, DVM, DABVP (Canine and Feline)

IMAGING PERFORMED BY

Christa Williams, DVM, DABVP

HOSPITAL NAME

Caravan Vet

REFERRING VET

Christa Williams, DVM, DABVP

INVOICE

10790

DATE

4/9/26

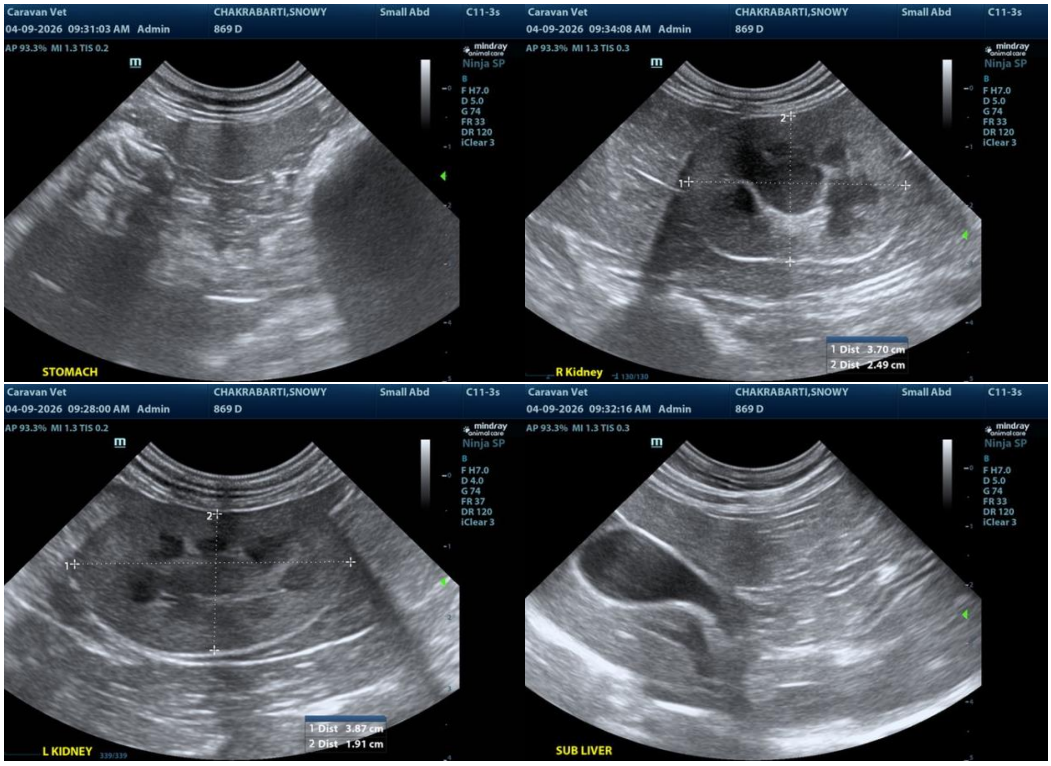

The information and recommendations provided are based on the images presented by the referring veterinarian/sonographer. No evaluation can be communicated regarding pathology that was not visible in the image/video clips provided.

Thank you for this referral. If the clinical or image interpretation does not parallel your findings or if I can be of any further assistance, please contact me.

R. McKenzie Daniel, DVM, DABVP (Canine/Feline Practice)
info@sonopath.com