

**PATIENT**

Mochi Lou

SPECIES

Feline

BREED

Scottish Fold

SEX

MN

AGE

1yr

WEIGHT

10.2lb

INTERPRETED BY

R. McKenzie Daniel,
DVM, DABVP
(Canine and Feline)

**IMAGING
PERFORMED BY**

Dr. Parthenia

HOSPITAL NAME

Kew Gardens Animal
Hospital

REFERRING VET

Dr. Parthenia

INVOICE

24432

DATE

04/09/2026

PRESENTING CLINICAL SIGNS

History of urinary blockage, Came today for straining to urinate.

Abnormal PE/Chem/CBC/UA Results: CBC/CHEM --- WNL

ULTRASONOGRAPHIC EXAMINATION OF THE ABDOMEN**Urinary System**

The urinary bladder was non-distended in size with normal tone. The trigone, cystourethral junction, and visible pelvic urethra to a depth of 2 cm exhibited normal thickness and tone. Anechoic urine was present in the lumen with no evidence of urine/lumen sediment, mineral, or calculi. The ureteral papillae were normal. The ureters were not visible, which is normal. No evidence of inflammatory or neoplastic changes was noted.

Normal size and margination were present in the kidneys. A normal 1:3 cortex / medulla ratio and normal corticomedullary definition were maintained. The echogenicity of the cortex was similar to or slightly less than normal liver parenchyma while the medulla echogenicity was hypoechoic to the cortex with no evidence of pelvic dilation. The left kidney measured 3.7 cm in length. The right kidney measured 3.7 cm in length.

The area of the aortic trifurcation was free of pathology.

Adrenal Glands

The left and right adrenal glands were not definitively visualized. No obvious pathology was present in the area of the bilateral adrenal glands.

Spleen

The spleen exhibited a finely textured and homogenous parenchyma which was hyperechoic to the liver and renal cortical parenchyma. The capsule was smooth and regular without apparent expansion. The splenic vasculature at the hilus was normal in volume with no evidence of congestion or thrombosis. Acute to chronic inflammatory, neoplastic, or benign parenchyma changes were not noted.

Liver/Gallbladder

The liver was subjectively normal in size, structure, and contour. The liver parenchyma was uniform and hypoechoic to the spleen with a mild coarse echotexture. Normal vascular volume. The hepatic and portal vasculature were normal in appearance without signs of congestion. The gallbladder was non-distended in size with thin walls and primarily anechoic luminal content. The cystic and common bile ducts were normal.

Gastrointestinal

The stomach presented intact wall layering with a normal wall layer ratio. The lumen of the stomach contained mild non-shadowing ingesta sonographically suggestive of food echogenicity with no signs of obstruction or foreign material.

The small intestine presented intact wall layering with 1:3 muscularis/mucosa ratio. The lumen of the small intestine was empty with no signs of mechanical/metabolic ileus, obstruction or foreign material.



PATIENT

Normal visible colon wall layers were present with apparent formed feces in lumen.

Mochi Lou

Pancreas

The parenchyma of the left limb, body and right limb of the pancreas presented isoechoic to the adjacent omental fat. A normal curvilinear capsule contour of the pancreas was present. The visible pancreatic duct was normal. No signs of active inflammation or neoplastic disease was evident.

SPECIES

Feline

Free Abdomen

BREED

No omental masses, overt lymphadenopathy or peritoneal effusion was present.

Scottish Fold

ULTRASONOGRAPHIC FINDINGS

Primary

SEX

- Normal non-distended urinary bladder, normal visible proximal urethra
- Normal bilateral kidneys

MN

AGE

INTERPRETATION OF THE FINDINGS & FURTHER RECOMMENDATIONS

1yr

No evidence of upper or lower urinary tract pathology. Urine C/S on a sterile urine sample to rule out underlying UTI may be considered. Empirical therapy for probable mild idiopathic cystitis is recommended.

WEIGHT

10.2lb

INTERPRETED BY

R. McKenzie Daniel,
DVM, DABVP
(Canine and Feline)

IMAGING PERFORMED BY

Dr. Parthenia

HOSPITAL NAME

Kew Gardens Animal
Hospital

REFERRING VET

Dr. Parthenia

INVOICE

24432

DATE

04/09/2026



PATIENT

Mochi Lou

SPECIES

Feline

BREED

Scottish Fold

SEX

MN

AGE

1yr

WEIGHT

10.2lb

INTERPRETED BY

R. McKenzie Daniel,
DVM, DABVP
(Canine and Feline)

IMAGING PERFORMED BY

Dr. Parthenia

HOSPITAL NAME

Kew Gardens Animal
Hospital

REFERRING VET

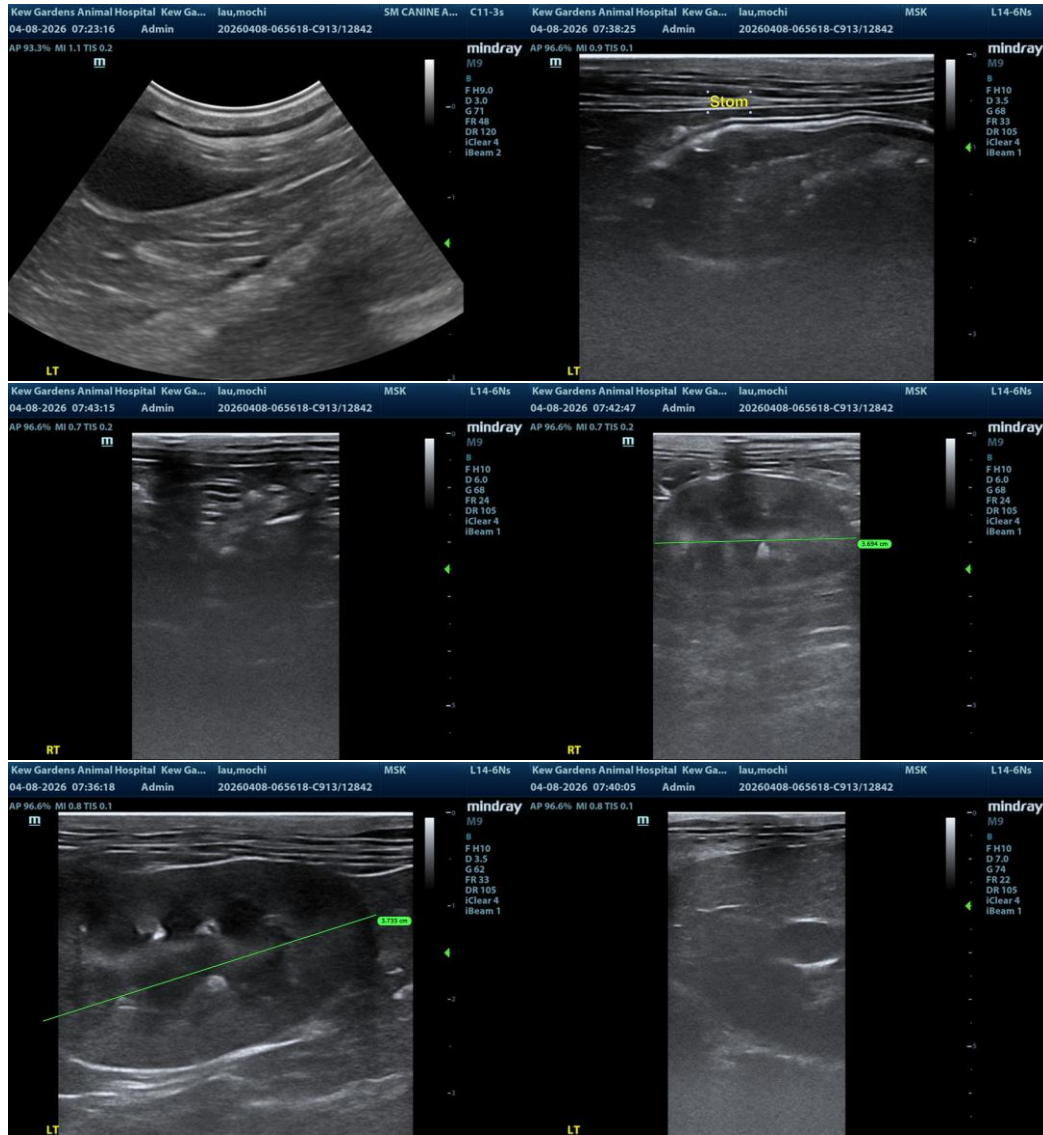
Dr. Parthenia

INVOICE

24432

DATE

04/09/2026



The information and recommendations provided are based on the images presented by the referring veterinarian/sonographer. No evaluation can be communicated regarding pathology that was not visible in the image/video clips provided.

Thank you for this referral. If the clinical or image interpretation does not parallel your findings or if I can be of any further assistance, please contact me.

R. McKenzie Daniel, DVM, DABVP (Canine/Feline Practice)
info@sonopath.com