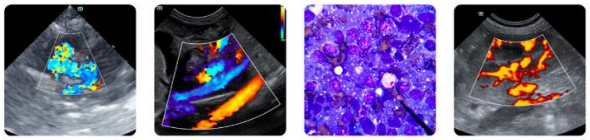

PATIENT
Beau Varner

SPECIES
Canine

BREED
Border Collie Mix

SEX
MN

AGE
1y, 9m

WEIGHT
59.6 lbs.

INTERPRETED BY
R. McKenzie Daniel, DVM, DABVP (Canine and Feline)

IMAGING PERFORMED BY
Meghan Myers VMD

HOSPITAL NAME
Hershire AH

REFERRING VET
Susan Zhang DVM

INVOICE
10789

DATE
4/9/26

PRESENTING CLINICAL SIGNS

Hx of intermittent vomiting since Dec. with occasional diarrhea. Seen 3/18 cbc/chem wnl, PSL wnl, 4dx neg. Instructed to continue i/d, pepcid and start proviable. Still have some intermitent vomiting so was recommended to try novel protein with salmon-no interestin this or i/d so was put on GI biome. When P vomiting on biome started purina HA--looks like was trying to do slow transition from i/d to HA 1 week ago. Started reglan 10mg BID before feedings. Still vomiting intermittently.

ULTRASONOGRAPHIC EXAMINATION OF THE ABDOMEN

Urinary System

The urinary bladder, trigone, and cystourethral junction exhibited normal thickness and tone. Anechoic urine was present in the lumen with no uroliths or sediment. The ureteral papillae were normal. The ureters were not visible which is normal. No evidence of inflammatory or neoplastic changes were noted.

The area of the residual prostate appeared normal and free of pathology

No evidence of pathology in the area of the aortic trifurcation.

Normal size and margination were present in the kidneys. A normal 1:3 cortex / medulla ratio and normal corticomedullary definition were maintained. The echogenicity of the cortex was similar to or slightly less than normal liver parenchyma while the medulla echogenicity was hypoechoic to the cortex with no evidence of pelvic dilation. The left kidney measured 6.7 cm in length. The right kidney measured 6.3 cm in length.

Adrenal Glands

The left adrenal gland was subnormal in size with a uniformly hypoechoic parenchyma. The left adrenal gland measured 0.30 cm width at the caudal pole. The right adrenal gland was indistinctly visualized exhibiting concurrent subjective subnormal size. The right adrenal gland measured 0.38 cm width at the caudal pole.

Spleen

The spleen exhibited a finely textured and homogenous parenchyma which was hyperechoic to the liver and renal cortical parenchyma. The capsule was smooth and regular without apparent expansion. The splenic vasculature at the hilus was normal in volume with no evidence of congestion or thrombosis. Acute to chronic inflammatory, neoplastic, or benign parenchyma changes were not noted.

Liver/ Gallbladder

The liver was subjectively normal in size, structure, and contour. Normal hepatic vascular volume was present. The liver parenchyma was uniform and hypoechoic to the spleen with a mild coarse echotexture. The hepatic and portal vasculature were normal in appearance without signs of congestion. The gallbladder was non-distended in size with thin walls and primarily anechoic luminal content. The cystic and common bile ducts were normal.

Gastrointestinal

The stomach presented intact mildly thickened wall. The gastric lumen was empty with mild gas. There was no evidence of obstruction to pyloric outflow. The stomach wall width measured 0.8 cm.

PATIENT
Beau Varner

SPECIES
Canine

BREED
Border Collie Mix

SEX
MN

AGE
1y, 9m

WEIGHT
59.6 lbs.

INTERPRETED BY
R. McKenzie Daniel, DVM, DABVP (Canine and Feline)

IMAGING PERFORMED BY
Meghan Myers VMD

HOSPITAL NAME
Hershire AH

REFERRING VET
Susan Zhang DVM

INVOICE
10789

DATE
4/9/26

The small intestine presented intact wall layering with 1:3 muscularis/mucosa ratio. The lumen of the small intestine was empty with no signs of ileus, obstruction, or foreign material.

Normal visible colon wall layers were present with formed feces in lumen.

Pancreas

The area of the pancreas was sonographically normal.

Free Abdomen

No overt lymphadenopathy or peritoneal effusion was present.

ULTRASONOGRAPHIC FINDINGS

- Mildly thickened empty stomach
- Normal small intestine
- Bilateral subnormal adrenal glands

INTERPRETATION OF THE FINDINGS & FURTHER RECOMMENDATIONS

The stomach is suggestive of gastritis criteria. There is no evidence of mechanical gastrointestinal obstruction or sonographically active pancreatitis. A GI panel to include PLI/TLI/Cobalamin/Folate and cortisol level is recommended.

Continued hydrolyzed diet trial with potential smaller, more frequent feedings, and consideration for Omeprazole, 1.0 mg/kg PO SID as-needed, may prove beneficial. If persistent to continued intermittent vomiting, and pending additional diagnostics, upper gastrointestinal endoscopy with potential biopsies is recommended.

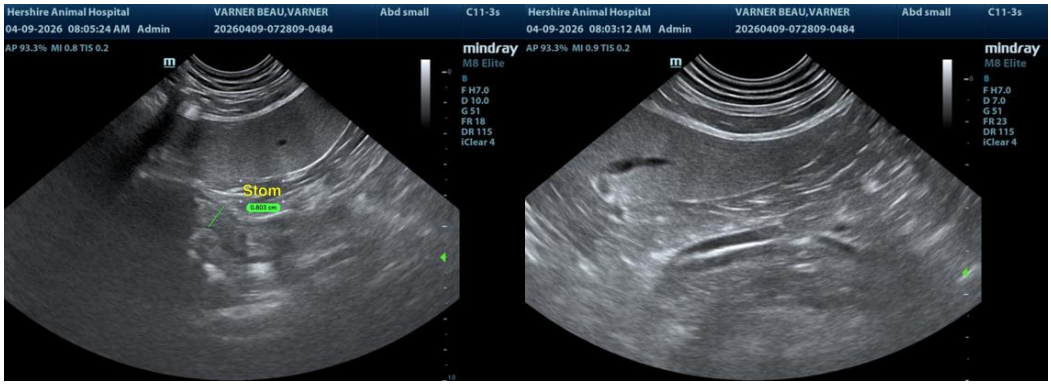

SonoPath
FOSTERING THE ART OF VETERINARY MEDICINE™

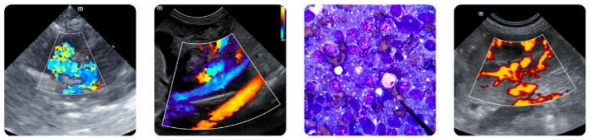

Clinical Sonography & Telecytology
Educational Teleconsultation Services™

SonoPath.com *info@sonopath.com* *1.800.838.4268*

PATIENT

Beau Varner

SPECIES

Canine

BREED

Border Collie Mix

SEX

MN

AGE

1y, 9m

WEIGHT

59.6 lbs.

INTERPRETED BY

R. McKenzie Daniel, DVM, DABVP (Canine and Feline)

IMAGING PERFORMED BY

Meghan Myers VMD

HOSPITAL NAME

Hershire AH

REFERRING VET

Susan Zhang DVM

INVOICE

10789

DATE

4/9/26

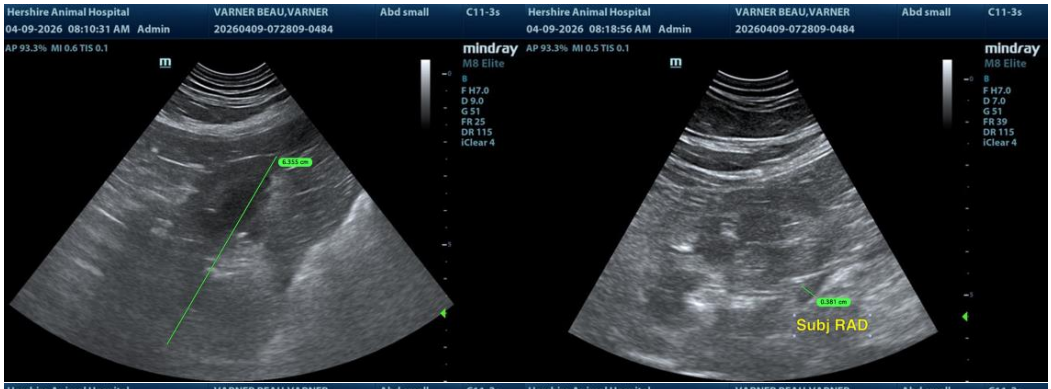

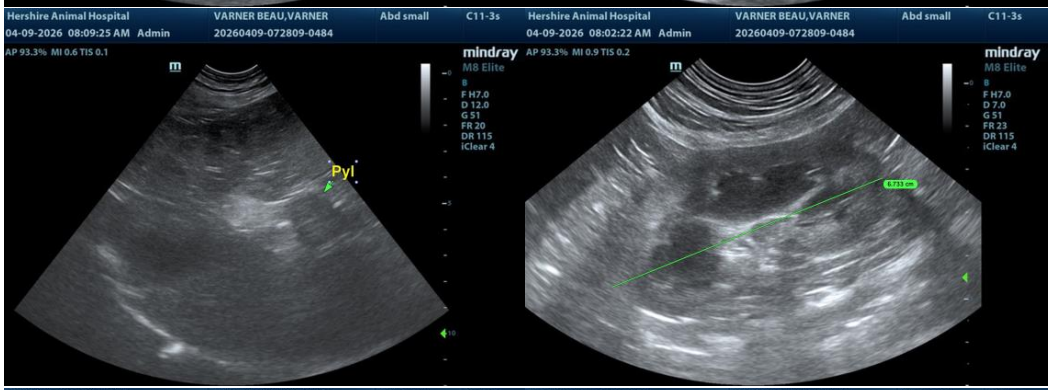

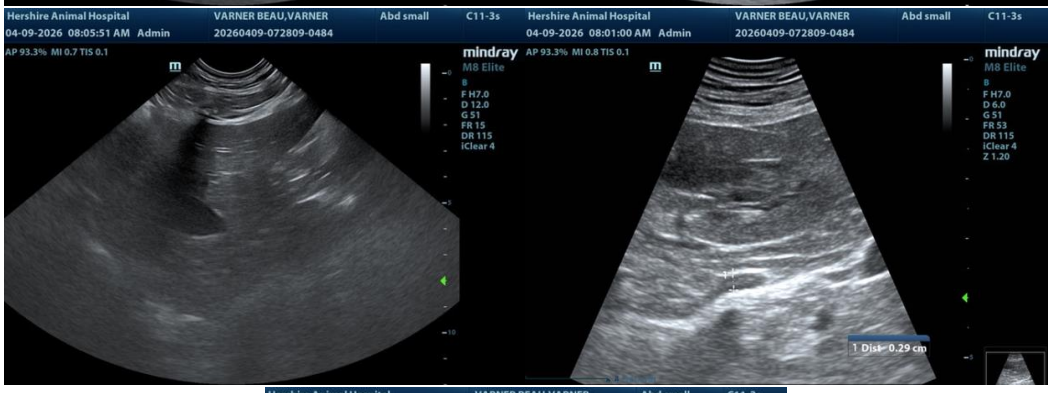

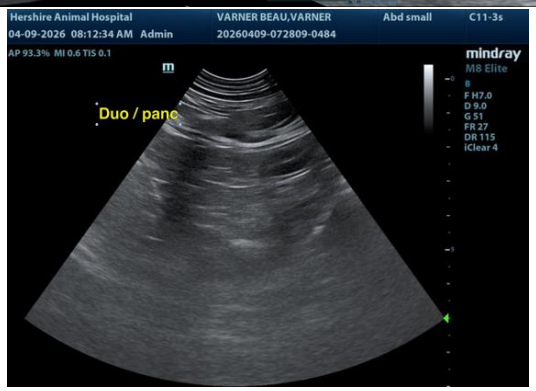

SonoPath
FOSTERING THE ART OF VETERINARY MEDICINE™

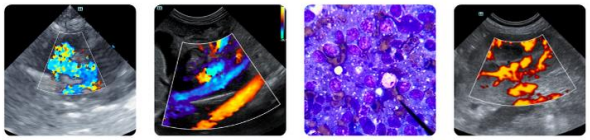

Clinical Sonography & Telecytology
Educational Teleconsultation Services™

SonoPath.com info@sonopath.com 1.800.838.4268

PATIENT

Beau Varner

SPECIES

Canine

BREED

Border Collie Mix

SEX

MN

AGE

1y, 9m

WEIGHT

59.6 lbs.

INTERPRETED BY

R. McKenzie Daniel, DVM, DABVP (Canine and Feline)

IMAGING PERFORMED BY

Meghan Myers VMD

HOSPITAL NAME

Hershire AH

REFERRING VET

Susan Zhang DVM

INVOICE

10789

DATE

4/9/26

The information and recommendations provided are based on the images presented by the referring veterinarian/sonographer. No evaluation can be communicated regarding pathology that was not visible in the image/video clips provided.

Thank you for this referral. If the clinical or image interpretation does not parallel your findings or if I can be of any further assistance, please contact me.

R. McKenzie Daniel, DVM, DABVP (Canine/Feline Practice)
info@sonopath.com