

**PATIENT**

Lucy Rosen

**SPECIES**

Canine

**BREED**

Norwich Terrier

**SEX**

Female (spayed)

**AGE**

12 years

**WEIGHT**

9.3 lbs.

**INTERPRETED BY**

R. McKenzie Daniel,  
DVM, DABVP  
(Canine and Feline)

**IMAGING PERFORMED BY**

Meghan Morse, LVT,  
CVT

**HOSPITAL NAME**

Oakland AH

**REFERRING VET**

Dr. Pellicano

**INVOICE**

10765

**DATE**

4/7/26

**PRESENTING CLINICAL SIGNS**

History:

- Decreased appetite/ inappetance, lethargic, intermittent v+
- Some response to Cerenia/ SQF but temporary
- No current meds

Abnormal PE/Chem/CBC/UA Results: RBC 3.4, HCT 24.4, HGB 8.2, WBC 18.4, Neuts 15.99, BUN 81

**ULTRASONOGRAPHIC EXAMINATION OF THE ABDOMEN**

***Urinary System***

The urinary bladder was normal in size and tone, containing anechoic urine without mineral or calculi. Minor, indistinctly visualized, hyperechoic sediment to possible mineral was noted. Mild, nonhomogeneous to small mass lesion was noted in the area of the cystourethral junction and proximal urethral lumen, measuring ~1.4 cm x 0.74 cm. The lesion did not appear to be obstructive to urine outflow.

No evidence of medial Iliac or sublumbar lymphadenopathy/masses.

The discernible left kidney exhibited loss of corticomedullary architecture and border demarcation. Moderate hydronephrosis was present. An irregular, expansive, nonhomogeneous mass was noted in the area of the left kidney, appearing to derive from the left kidney parenchyma, measured ~6.0-7.0 cm in diameter. There was no overt left retroperitoneal effusion.

Normal size and margination were present in the right kidney. A normal 1:3 cortex / medulla ratio was maintained. The medulla and cortices were uniform in texture with some increased echogenicity and mild loss of corticomedullary symmetry and definition expected for the age of the patient. No evidence of pelvic dilation was present. The right kidney measured 4.2 cm in length.

***Adrenal Glands***

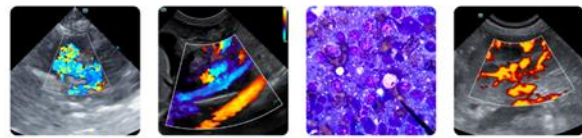
The left adrenal gland was not definitively visualized. The right adrenal gland was normal in size. Mild parenchyma heterogeneity and mild capsule asymmetry were present without suspicion for overt neoplasia. The right adrenal gland measured 0.64 cm width in the caudal pole.

***Spleen***

The spleen exhibited a finely textured and homogenous parenchyma which was hyperechoic to the liver and renal cortical parenchyma. The capsule was smooth and regular without apparent expansion. The splenic vasculature at the hilus was normal in volume with no evidence of congestion or thrombosis. Acute to chronic inflammatory, neoplastic, or benign parenchyma changes were not noted.

***Liver/ Gallbladder***

The liver presented subjective hepatomegaly with symmetrical to rounded hepatic capsule contour and mild nonhomogeneous, remodeled hepatic parenchyma. Multiple, discreet, hypoechoic to nonhomogeneous, intraparenchymal nodules were present, with an example measuring 1.2 cm.



**PATIENT**

Lucy Rosen

**SPECIES**

Canine

**BREED**

Norwich Terrier

**SEX**

Female (spayed)

**AGE**

12 years

**WEIGHT**

9.3 lbs.

**INTERPRETED BY**

R. McKenzie Daniel,  
DVM, DABVP  
(Canine and Feline)

**IMAGING PERFORMED BY**

Meghan Morse, LVT,  
CVT

**HOSPITAL NAME**

Oakland AH

**REFERRING VET**

Dr. Pellicano

**INVOICE**

10765

**DATE**

4/7/26

The gallbladder was non-distended in size containing primarily anechoic content with minor nonorganized gallbladder debris. The cystic and common bile ducts were normal.

***Gastrointestinal***

The stomach presented intact wall layering with a normal wall layer ratio. The lumen of the stomach was empty without evidence of retained ingesta, fluid, or foreign material.

The small intestine presented intact wall layering with 1:3 muscularis/mucosa ratio. The lumen of the small intestine was empty with no signs of ileus, obstruction, or foreign material.

Normal visible colon wall layers were present with formed feces in lumen.

***Pancreas***

The pancreas was normal in size and contour with isoechoic to heterogeneous parenchyma compared to adjacent omentum. No signs of active inflammation or neoplasia.

***Free Abdomen***

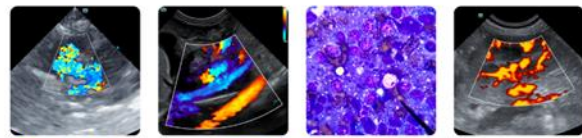
No overt lymphadenopathy or peritoneal effusion was present.

**ULTRASONOGRAPHIC FINDINGS**

- Mass area of the left kidney with moderate left kidney pyelectasia
- Intact mild age-related right kidney
- Nonhomogeneous liver exhibiting discreet intraparenchymal nodules
- Mild nonorganized gallbladder debris (non mucocele)
- Small nonobstructive cystourethral junction / proximal urethral mass lesion
- Sonographically unremarkable gastrointestinal tract
- Mild heterogenous remodeled pancreas

**INTERPRETATION OF THE FINDINGS & FURTHER RECOMMENDATIONS**

The mass lesion in the area of the left kidney is most consistent with renal origin and neoplastic criteria. Given the non-visualized left adrenal gland, adrenal involvement or origin is not definitively excluded. The discreet liver nodules may indicate hyperplasia, hematopoiesis, granulomas, or other benign etiology with metastasis possible. Further assessment may include, assuming normal clotting status, mass and hepatic FNA cytology. Screening BRAF assay is warranted. A spec cPL to assess for evidence of mild to chronic pancreatitis with concurrent gastrointestinal support is recommended.



**PATIENT**

Lucy Rosen

**SPECIES**

Canine

**BREED**

Norwich Terrier

**SEX**

Female (spayed)

**AGE**

12 years

**WEIGHT**

9.3 lbs.

**INTERPRETED BY**

R. McKenzie Daniel,  
DVM, DABVP  
(Canine and Feline)

**IMAGING PERFORMED BY**

Meghan Morse, LVT,  
CVT

**HOSPITAL NAME**

Oakland AH

**REFERRING VET**

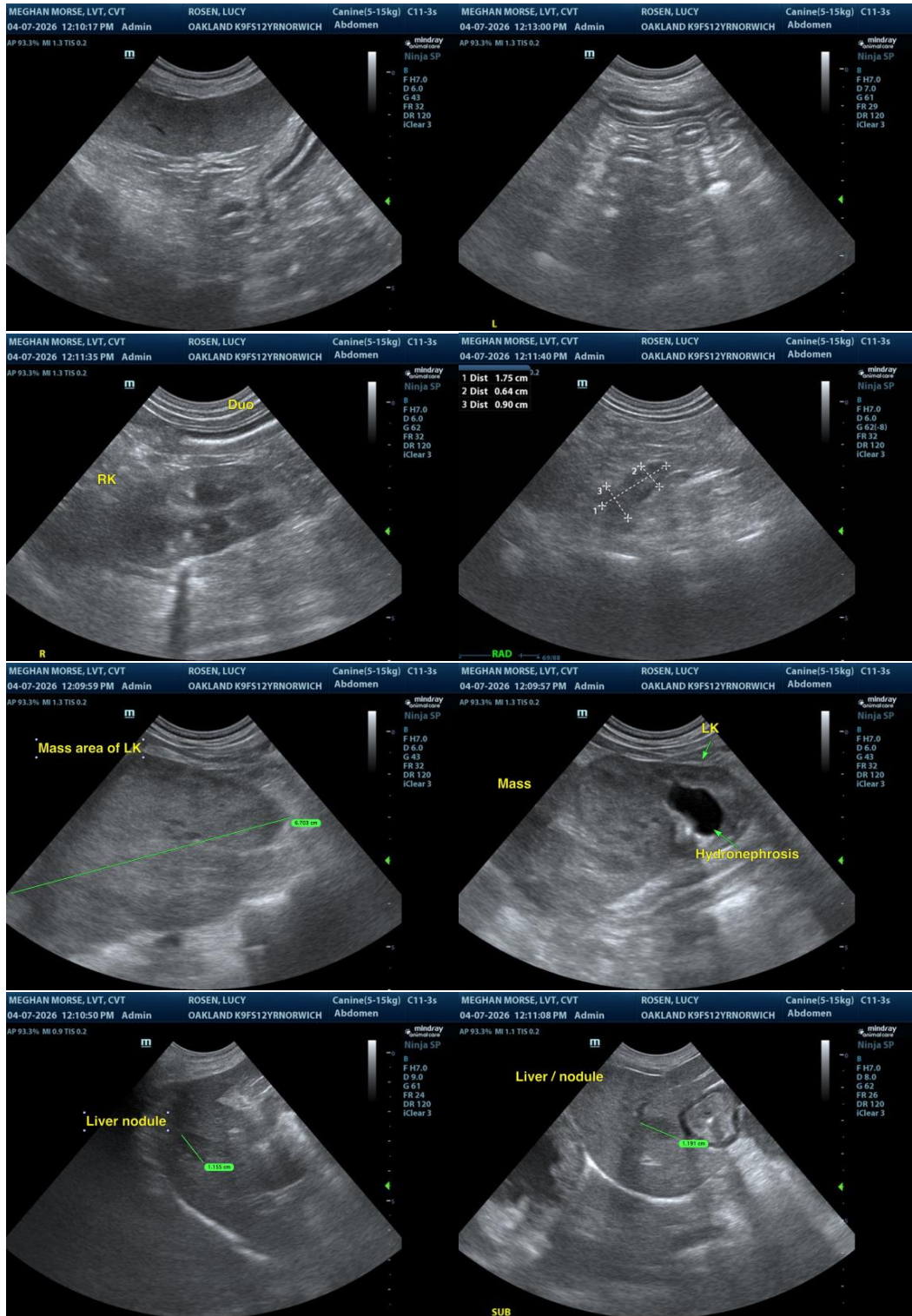
Dr. Pellicano

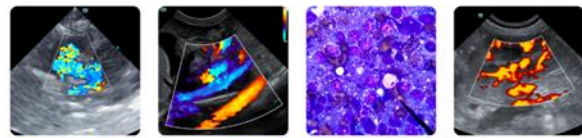
**INVOICE**

10765

**DATE**

4/7/26





**PATIENT**

Lucy Rosen

**SPECIES**

Canine

**BREED**

Norwich Terrier

**SEX**

Female (spayed)

**AGE**

12 years

**WEIGHT**

9.3 lbs.

**INTERPRETED BY**

R. McKenzie Daniel,  
 DVM, DABVP  
 (Canine and Feline)

**IMAGING PERFORMED BY**

Meghan Morse, LVT,  
 CVT

**HOSPITAL NAME**

Oakland AH

**REFERRING VET**

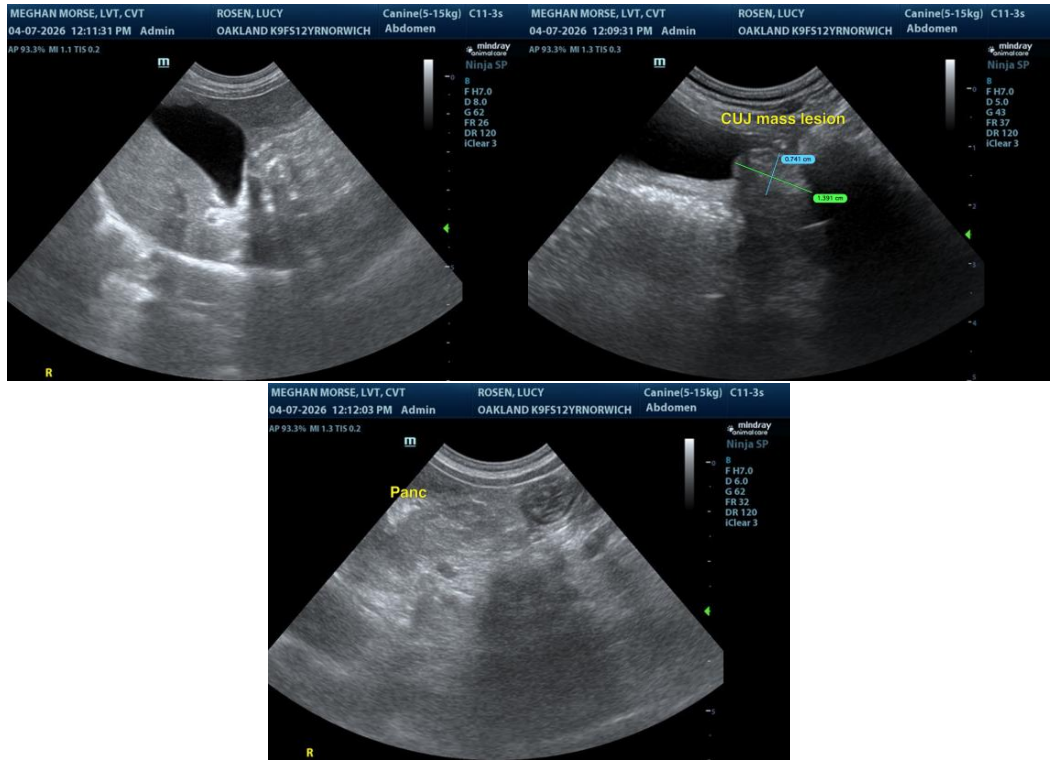
Dr. Pellicano

**INVOICE**

10765

**DATE**

4/7/26



The information and recommendations provided are based on the images presented by the referring veterinarian/sonographer. No evaluation can be communicated regarding pathology that was not visible in the image/video clips provided.

Thank you for this referral. If the clinical or image interpretation does not parallel your findings or if I can be of any further assistance, please contact me.

R. McKenzie Daniel, DVM, DABVP (Canine/Feline Practice)  
[info@sonopath.com](mailto:info@sonopath.com)