



PATIENT

Samantha Granitzki

SPECIES

Feline

BREED

DSH

SEX

FS

AGE

15 years

WEIGHT

8.4 lbs.

INTERPRETED BY

R. McKenzie Daniel,
DVM, DABVP
(Canine and Feline)

IMAGING PERFORMED BY

Shari Reffi, CVT

HOSPITAL NAME

Tranquility VC

REFERRING VET

Dr. Christensen

INVOICE

13628

DATE

4/7/22

PRESENTING CLINICAL SIGNS

Pre-anesthetic CUS. Grade II/VI systolic murmur. No current meds.

ULTRASONOGRAPHIC EXAMINATION OF THE HEART

FELINE CARDIAC PARAMETERS	BODY WEIGHT (kg)	HR (BPM)	IVSd (cm)	LVIDd (cm)	LVWd (cm)	FS (%)	EF (%)
NORMAL PARAMETER	-----	150-240	0.3-0.6	1.0-2.1	0.25-0.6	35-67	80-100
PATIENT		205	0.56	1.23	0.58	54.6	88.5
FELINE CARDIAC PARAMETERS	LA/AO (Boon)	LA/AO HEART BASE (Sisson)	LA 2D 4-chamber long axis AS to FW (Sisson) (cm)	LVOT VEL. (m/s)	RVOT VEL. (m/s)	IVRT (m/)	
NORMAL PARAMETER	<1.5	0.88-1.79	0.7-1.7	<1.6	<1.3	40-60	
PATIENT	1.38	1.31	1.25	1.0	0.8	NM	
Adapted from June Boon, Veterinary Echocardiography, 1998							
Sisson D et al. JVIM 1991; 5: 232, Jacobs et al. Am J Vet Res 1985; 46:1705							

Cardiac Presentation

The echocardiogram in this patient demonstrated normal **left atrial** size based on 3 separate LA measurements. The cranial and caudal **mitral** valve leaflets presented normal linear structure and kinetics. No overt MR. The **left ventricle** presented overtly normal thicknesses with mildly myocardial asymmetry in the area of the basilar IVS and without evidence of LV dilation or restriction. The **myocardium** presented normal echogenicity without subjective evidence of significant fibrotic or ischemic disease. Subtly prominent papillary muscles were noted. **Contractility** of the ventricular walls was adequate and in normal range for this patient evidenced by the fractional shortening measurement and subjective evaluation of the different regions and angles of the myocardium. The **left ventricular outflow** tract demonstrated mildly turbulent to dynamic systolic flow, yet normal structural integrity. The **right atrium** and auricle revealed normal size, structure and content. No evidence of masses was noted or chamber overload. **Tricuspid** valvular assessment demonstrated adequate linear morphology and kinetics. The **right ventricle** was of normal size (1/3 diameter of LV), chordae structure, myocardial echogenicity and thickness. **Pulmonic** tract assessment revealed normal valve structure, laminar flow, and diameter (approx. 1:1 pa/ao ratio). No visible **pericardial** or free pleura fluid was noted or extra cardiac pathology in the visible planes. The cranial **mediastinum** and **pericardial regions** were free of masses in the visible window.

ULTRASONOGRAPHIC FINDINGS

- Overtly normal cardiac structure and function



PATIENT

Samantha Granitzki

SPECIES

Feline

BREED

DSH

SEX

FS

AGE

15 years

WEIGHT

8.4 lbs.

INTERPRETED BY

R. McKenzie Daniel,
DVM, DABVP
(Canine and Feline)

IMAGING PERFORMED BY

Shari Reffi, CVT

HOSPITAL NAME

Tranquility VC

REFERRING VET

Dr. Christensen

INVOICE

13628

DATE

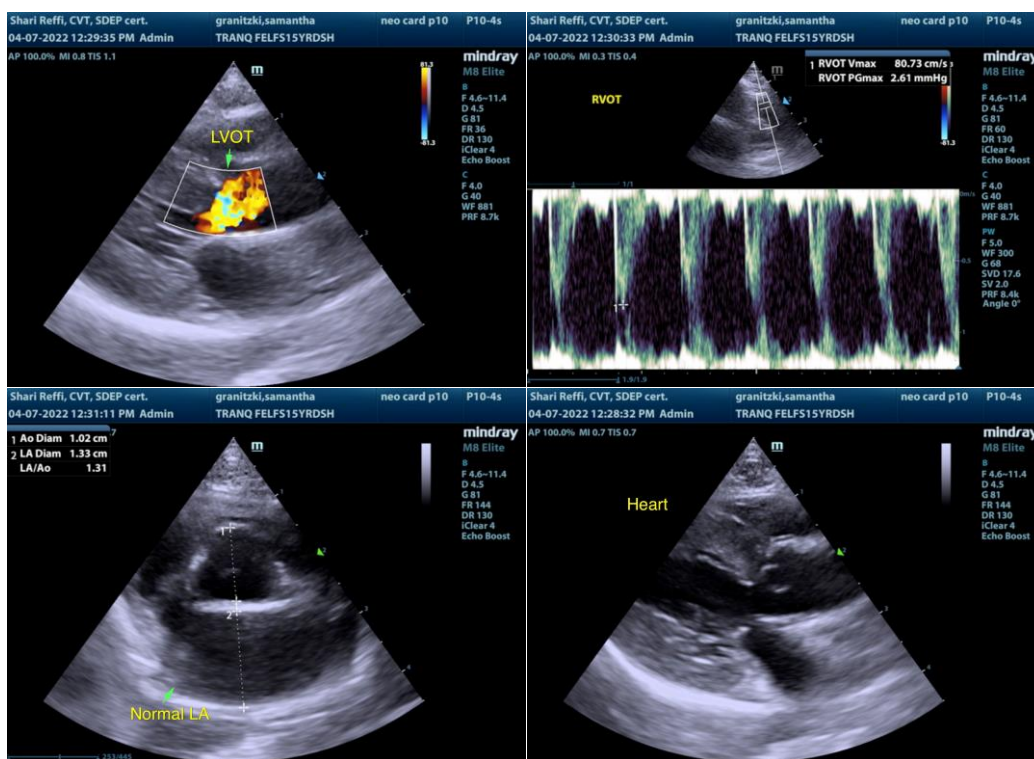
4/7/22

INTERPRETATION OF THE FINDINGS & FURTHER RECOMMENDATIONS

No evidence of Structural or functional cardiomyopathy was evident. The only source of the murmur noted is potential mild dynamic to turbulent LV outflow tract flow, which is essentially a physiologic or flow murmur. No evidence of systolic anterior motion (SAM) of the mitral valve or significant fixed LVOT obstruction noted. The lack of left or right heart chamber enlargement, as well as lack of additional clinical issues such as systolic dysfunction, indicate that the hemodynamic effects of the low-grade murmur are minimal. No indication for cardiac medications. No anesthetic contraindications based on this study and assuming normal blood pressure.

Conservative monitoring of the murmur at this stage would be appropriate with recheck echocardiogram suggested in 6 months, sooner if clinical signs arise or if murmur intensity progresses. A thyroid panel is suggested if not done.

Suggested anesthetic protocol may include opioid or Benzodiazepine pre-med, induction with Propofol or Alfaxalone, and appropriate gas anesthesia with avoidance of alpha 2 agonists.



The information and recommendations provided are based on the images presented by the referring veterinarian/sonographer. No evaluation can be communicated regarding pathology that was not visible in the image/video clips provided.

Thank you for this referral. If the clinical or image interpretation does not parallel your findings or if I



PATIENT

can be of any further assistance please contact me.

Samantha Granitzki

SPECIES

R. McKenzie Daniel, DVM, DABVP (Canine / Feline Practice)
info@SonoPath.com

Feline

BREED

DSH

SEX

FS

AGE

15 years

WEIGHT

8.4 lbs.

INTERPRETED BY

R. McKenzie Daniel,
DVM, DABVP
(Canine and Feline)

**IMAGING
PERFORMED BY**

Shari Reffi, CVT

HOSPITAL NAME

Tranquility VC

REFERRING VET

Dr. Christensen

INVOICE

13628

DATE

4/7/22