



**PATIENT PRESENTING CLINICAL SIGNS**

Maggie Carrozino Large amount of transitional epithelial cells in urinalysis, suspect urinary bladder mass

**SPECIES ULTRASONOGRAPHIC EXAMINATION OF THE ABDOMEN**

Canine **Urinary System**

**BREED** A sessile based mass deriving from the ventral urinary bladder wall extending into the mid urinary bladder with asymmetrical margination was present and measured approximately 1.9 cm x 1.6 cm. The parenchyma of the mass was heterogeneous. Pinpoint areas of mineralization were noted. Doppler evaluation of the mass confirmed vascularity within the mass. Anechoic urine was present in the lumen with no uroliths or sediment. The ureteral papillae were normal. The ureters were not visible which is normal. The urethra was overtly normal in structure and tone to a depth of 2.0 cm.

Terrier Mix

**SEX** FS The area of the aortic trifurcation was free of pathology and without evidence of medial iliac or sublumbar lymphadenopathy.

**AGE** 2010 Normal size and margination were present in the kidneys. A normal 1:3 cortex / medulla ratio was maintained. The medulla and cortices were uniform in texture with some increased echogenicity and mild loss of corticomedullary symmetry and definition expected for the age of the patient. Multiple small cortical cysts were present in both kidneys. No evidence of pelvic dilation was present. The left kidney measured 4.6 cm in length. The right kidney measured 5.9 cm in length.

**WEIGHT** 29

**Adrenal Glands**

**INTERPRETED BY** The bilateral adrenal glands were normal in size. The adrenal glands exhibited nonhomogeneous to indistinctly nodular parenchyma and mild capsule asymmetry was present without suspicion for overt neoplasia. The left adrenal gland measured 2.1 cm length x 0.75 cm width at the caudal pole. The right adrenal gland measured 2.5 cm length x 0.62 cm width at the caudal pole.

R. McKenzie Daniel,  
 DVM, DABVP  
 (Canine and Feline)

**Spleen**

**IMAGING PERFORMED BY** The spleen exhibited a finely textured and homogenous parenchyma which was hyperechoic to the liver and renal cortical parenchyma. The capsule was smooth and regular without apparent expansion. The splenic vasculature at the hilus was normal in volume with no evidence of congestion or thrombosis. Acute to chronic inflammatory, neoplastic, or benign parenchyma changes were not noted.

Rebekah Jakum, CVT  
 ARDMS/RVT

**HOSPITAL NAME**  
 Mill Pond VC

**Liver/ Gallbladder**

**REFERRING VET** The liver was subjectively normal in size and contour. The liver parenchyma was nonuniform exhibiting intermittent variably sized primarily discrete hypoechoic Intraparenchymal nodules. An example of the nodules measured 1.6 cm in diameter. The gallbladder was non-distended in size with mild nondependent and mobile gallbladder debris primarily in the caudal lumen and gallbladder neck. The gallbladder was otherwise normal. The cystic and common bile ducts were normal.

**INVOICE**  
 13633

**Gastrointestinal**

**DATE** 4/7/22 The stomach presented intact wall layering with a normal wall layer ratio. The lumen of the stomach was empty with no signs of ileus, obstruction, or foreign material.



**PATIENT** Maggie Carrozino  
 The small intestine presented intact wall layering with 1:3 muscularis/mucosa ratio. The lumen of the small intestine was empty with no signs of ileus, obstruction, or foreign material.  
 Normal visible colon wall layers were present with apparent formed feces in lumen.

**SPECIES** *Pancreas*

Canine The pancreas was normal in size and contour with isoechoic to heterogeneous parenchyma compared to adjacent omentum. No signs of active inflammation or neoplasia.

**BREED** *Free Abdomen*

Terrier Mix No overt lymphadenopathy or peritoneal effusion was present.

**SEX** **ULTRASONOGRAPHIC FINDINGS**

- FS
- Sessile based ventral urinary bladder mass - consistent with transitional cell carcinoma
  - Bilateral chronic renal changes with multiple small cortical cysts
  - Nonuniform to discretely nodular liver
  - Mild gallbladder debris (non-mucocele)
  - Nonhomogeneous to indistinctly nodular bilateral adrenal glands - suspect adenomatous change

**AGE**

2010

**WEIGHT**

29

**INTERPRETATION OF THE FINDINGS & FURTHER RECOMMENDATIONS**

**INTERPRETED BY** Based on the size and location of the confirmed urinary bladder mass, potential surgical resection may be an option for this patient. Overt evidence of regional lymphatic metastasis was not noted. The hepatic parenchymal changes are nonspecific yet suggestive of vacuolar hepatic changes with areas of nodular / regenerative hyperplasia, hematopoiesis, or lipogranulomas. Chronic inflammatory hepatopathy with less potential for neoplasia are also possible. Correlation with current lab work and hepatic enzyme elevation is recommended.

R. McKenzie Daniel,  
 DVM, DABVP  
 (Canine and Feline)

**IMAGING PERFORMED BY**

Rebekah Jakum, CVT  
 ARDMS/RVT

Technically, adrenal hyperplasia or emerging neoplastic disease, i.e., pheochromocytoma or adenocarcinoma cannot be definitively excluded. Screening blood pressure and sonographic monitoring of the bilateral adrenal glands +/- adrenal testing if clinically indicated could be considered.

**HOSPITAL NAME**

Mill Pond VC

**REFERRING VET**

Dr. Thayer

Although hepatic neoplastic or metastatic disease is considered less likely, screening ultrasound-guided hepatic FNA for cytology would be warranted.

**INVOICE**

13633

**DATE**

4/7/22



**PATIENT**

Maggie Carrozino

**SPECIES**

Canine

**BREED**

Terrier Mix

**SEX**

FS

**AGE**

2010

**WEIGHT**

29

**INTERPRETED BY**

R. McKenzie Daniel,  
DVM, DABVP  
(Canine and Feline)

**IMAGING PERFORMED BY**

Rebekah Jakum, CVT  
ARDMS/RVT

**HOSPITAL NAME**

Mill Pond VC

**REFERRING VET**

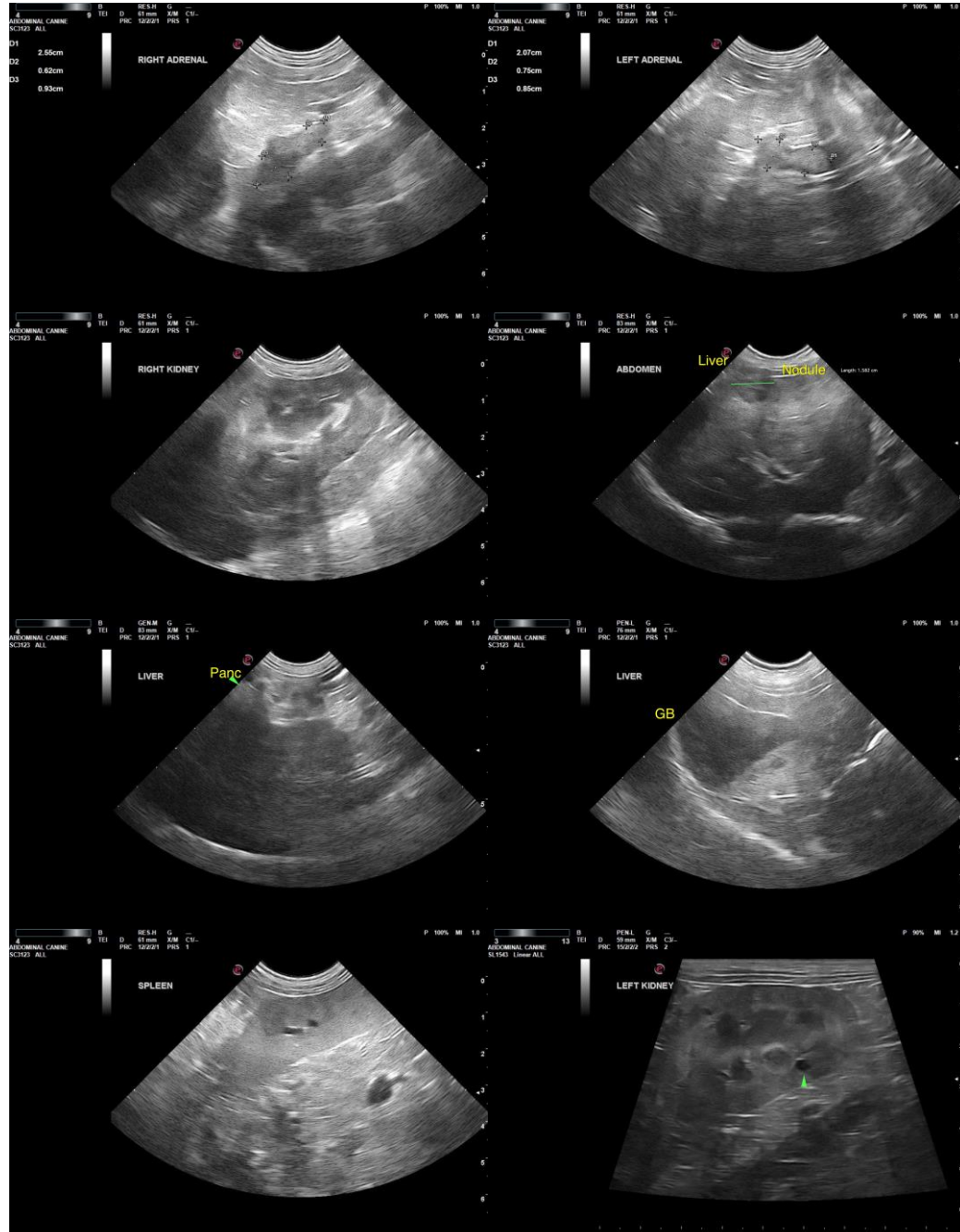
Dr. Thayer

**INVOICE**

13633

**DATE**

4/7/22





**PATIENT**

Maggie Carrozino

**SPECIES**

Canine

**BREED**

Terrier Mix

**SEX**

FS

**AGE**

2010

**WEIGHT**

29

**INTERPRETED BY**

R. McKenzie Daniel,  
DVM, DABVP  
(Canine and Feline)

**IMAGING**

**PERFORMED BY**  
Rebekah Jakum, CVT  
ARDMS/RVT

**HOSPITAL NAME**

Mill Pond VC

**REFERRING VET**

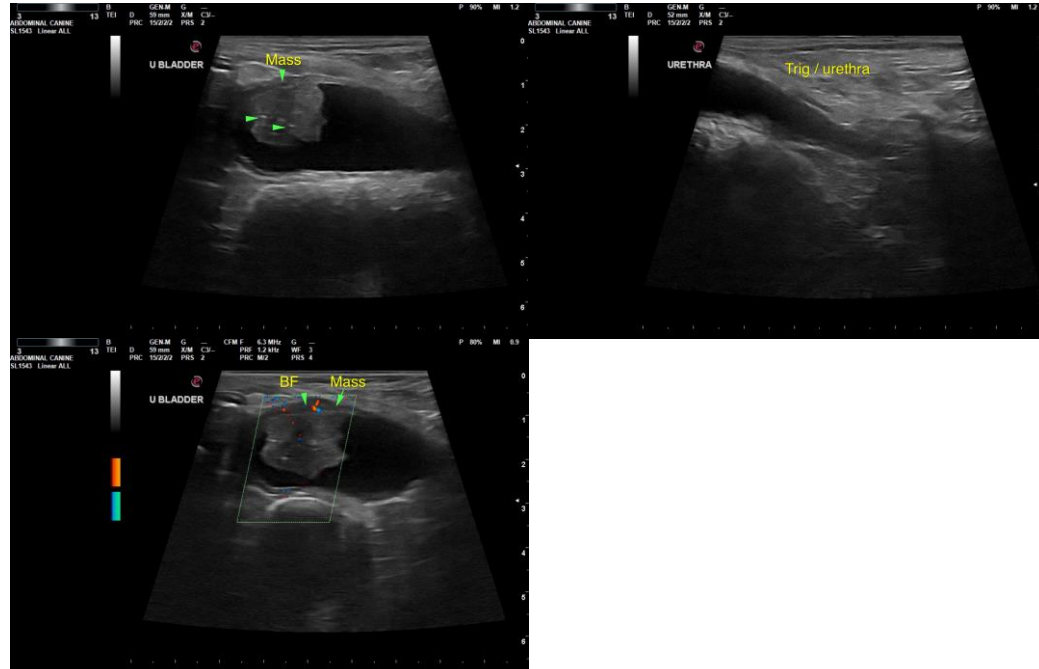
Dr. Thayer

**INVOICE**

13633

**DATE**

4/7/22



**The information and recommendations provided are based on the images presented by the referring veterinarian/sonographer. No evaluation can be communicated regarding pathology that was not visible in the image/video clips provided.**

Thank you for this referral. If the clinical or image interpretation does not parallel your findings or if I can be of any further assistance, please contact me.

**R. McKenzie Daniel, DVM, DABVP (Canine/Feline Practice)**  
[mac.daniel@sonopath.com](mailto:mac.daniel@sonopath.com)