

**PATIENT**

Josie Fulte

SPECIES

Canine

BREED

Labrador

SEX

FS

AGE

5 years 4 months

WEIGHT

92 lbs.

INTERPRETED BYR. McKenzie Daniel,
DVM, DABVP (Canine
and Feline)**IMAGING
PERFORMED BY**

Rachel Runnells, RVT

HOSPITAL NAME

SVS Imaging KC

REFERRING VET

Dr. Johathan Renfro

INVOICE

13636

DATE

4/7/22

PRESENTING CLINICAL SIGNS

Not eating, increased drinking. Has lost some weight. Elevated ALT. Urine Sp. Gr. 1.018.

ULTRASONOGRAPHIC EXAMINATION OF THE ABDOMEN***Urinary System***

The urinary bladder, trigone, cystourethral junction, and visible pelvic urethra to a depth of 3.0 cm exhibited normal thickness and tone. Anechoic urine was present in the lumen with no uroliths or sediment. The ureteral papillae were normal. The ureters were not visible which is normal. No evidence of inflammatory or neoplastic changes was noted.

The area of the aortic trifurcation was free of pathology.

Normal size and margination were present in the kidneys. A normal 1:3 cortex / medulla ratio and normal corticomedullary definition were maintained. The echogenicity of the cortex was similar to or slightly less than normal liver parenchyma while the medulla echogenicity was hypoechoic to the cortex with no evidence of pyelectasia. The left kidney measured 7.3 cm in length. The right kidney measured 7.7 cm in length.

Adrenal Glands

The left adrenal gland was uniform in size and contour with a uniformly hypoechoic parenchyma. The left adrenal gland measured 0.54 cm width at the caudal pole and 0.50 cm width at the cranial pole. The right adrenal gland was uniform in size and contour with a uniformly hypoechoic parenchyma. The right adrenal gland measured 0.78 cm width at the caudal pole and 0.81 cm width at the cranial pole.

Spleen

The spleen exhibited a finely textured and homogenous parenchyma which was hyperechoic to the liver and renal cortical parenchyma. The capsule was smooth and regular without apparent expansion. The splenic vasculature at the hilus was normal in volume with no evidence of congestion or thrombosis. Acute to chronic inflammatory, neoplastic, or benign parenchyma changes were not noted.

Liver/ Gallbladder

The liver was subjectively normal in size and contour with normal hepatic parenchyma echogenicity exhibiting mild to moderate coarse echotexture. Subtle increased prominence of the portal vascular borders was present. No masses or nodules were noted. The gallbladder was non-distended in size with thin walls and primarily anechoic luminal content. The cystic and common bile ducts were normal.

Gastrointestinal

The stomach presented intact wall layering with a normal wall layer ratio. Very minor retained ingesta / chyme and lumina gas was present in the stomach. The gastric body wall width measured 0.42 cm.

**PATIENT**

Josie Fulte

The small intestine presented intact wall layering with 1:3 muscularis/mucosa ratio. The lumen of the small intestine was empty with no signs of ileus, obstruction, or foreign material. The jejunum wall width measured 0.44 cm. The duodenum wall width measured 0.45 cm.

SPECIES

Canine

Normal visible colon wall layers were present with apparent formed feces in lumen.

Pancreas

The pancreas was normal in size exhibiting subjective areas of minor pancreatic capsule asymmetry with subtle hypoechoic parenchyma compared to adjacent nonreactive peripancreatic omentum.

BREED

Labrador

Free Abdomen

No overt lymphadenopathy or peritoneal effusion was present.

SEX

FS

ULTRASONOGRAPHIC FINDINGS**AGE**

5 years 4 months

- Hepatopathy - subjectively mild to low-grade
- Overtly normal gastrointestinal tract
- Normal bilateral kidneys
- Possible low-grade pancreatitis

WEIGHT

92 lbs.

INTERPRETATION OF THE FINDINGS & FURTHER RECOMMENDATIONS

Overall, no overt evidence of significant abdominal visceral pathology was evident.

INTERPRETED BY

R. McKenzie Daniel,
DVM, DABVP (Canine
and Feline)

Although nonspecific, the hepatic presentation may indicate low-grade inflammatory hepatopathy given the ALT elevation. Some degree of reactive hepatopathy is also possible potentially owing to structurally insignificant gastroenteropathy or low-grade pancreatitis.

Potential for low-grade pancreatitis would be suspected if evidence of cranial abdominal or subxiphoid discomfort on palpation. Correlation with a Spec cPL is recommended.

IMAGING PERFORMED BY

Rachel Runnells, RVT

Leptospirosis titers and or blood / urine PCR is warranted given the ALT elevation, as well as reported polydipsia.

HOSPITAL NAME

SVS Imaging KC

A GI panel to include PLI/TLI/Cobalamin/Folate as well as three view chest radiographs and neurological / musculoskeletal examination are recommended to assess for or rule out occult disease which may cause weight loss.

REFERRING VET

Dr. Johathan Renfro

INVOICE

13636

DATE

4/7/22

IMAGING PERFORMED BY

SVS Mobile Imaging KC 816-401-5010
svsimagingkc@gmail.com



EDUCATIONAL TELECONSULTATION SERVICES™
1-800-838-4268 info@sonopath.com SonoPath.com

PATIENT

Josie Fulte

SPECIES

Canine

BREED

Labrador

SEX

FS

AGE

5 years 4 months

WEIGHT

92 lbs.

INTERPRETED BY

R. McKenzie Daniel, DVM, DABVP (Canine and Feline)

IMAGING PERFORMED BY

Rachel Runnells, RVT

HOSPITAL NAME

SVS Imaging KC

REFERRING VET

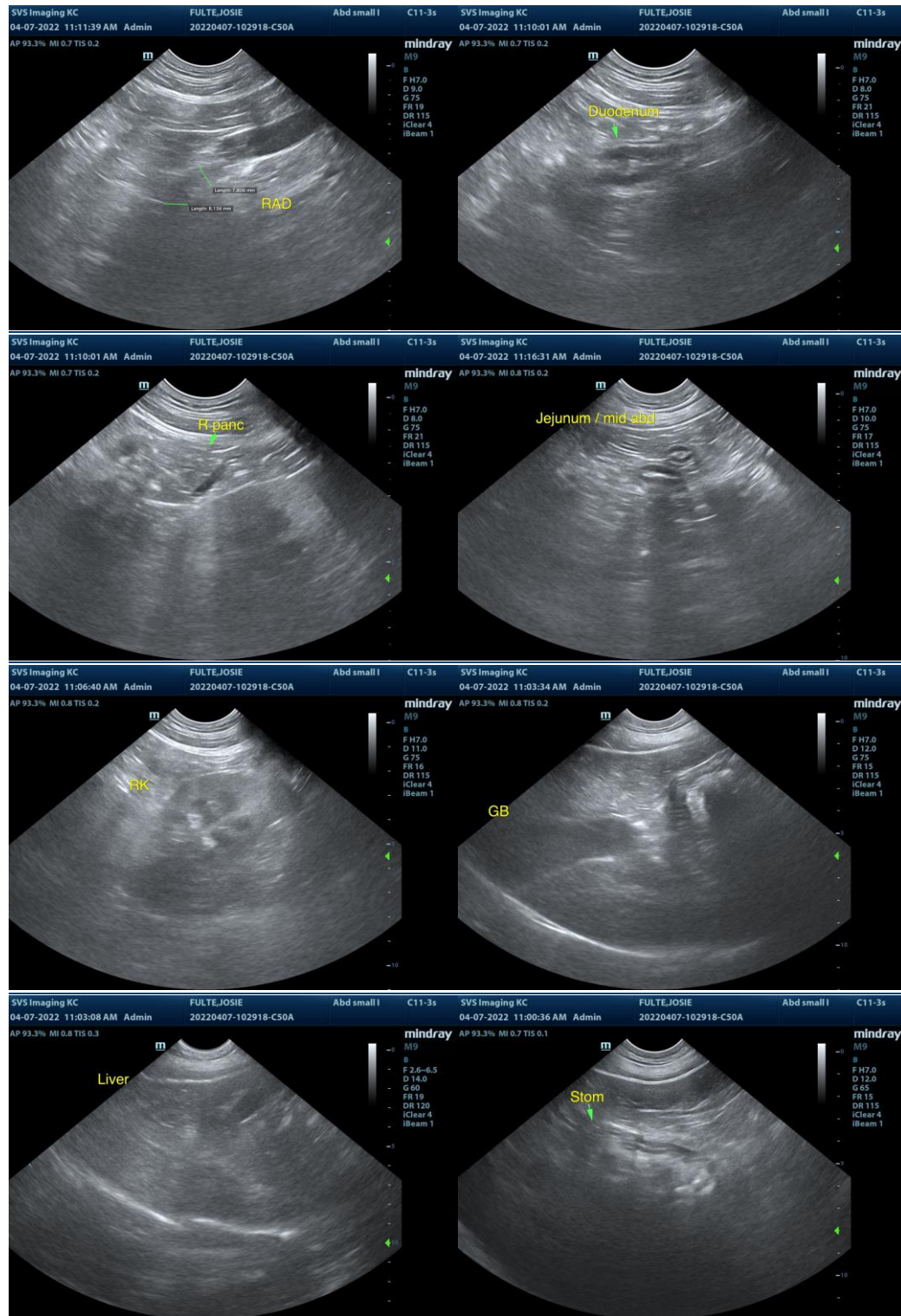
Dr. Johathan Renfro

INVOICE

13636

DATE

4/7/22





PATIENT

Josie Fulte

SPECIES

Canine

BREED

Labrador

SEX

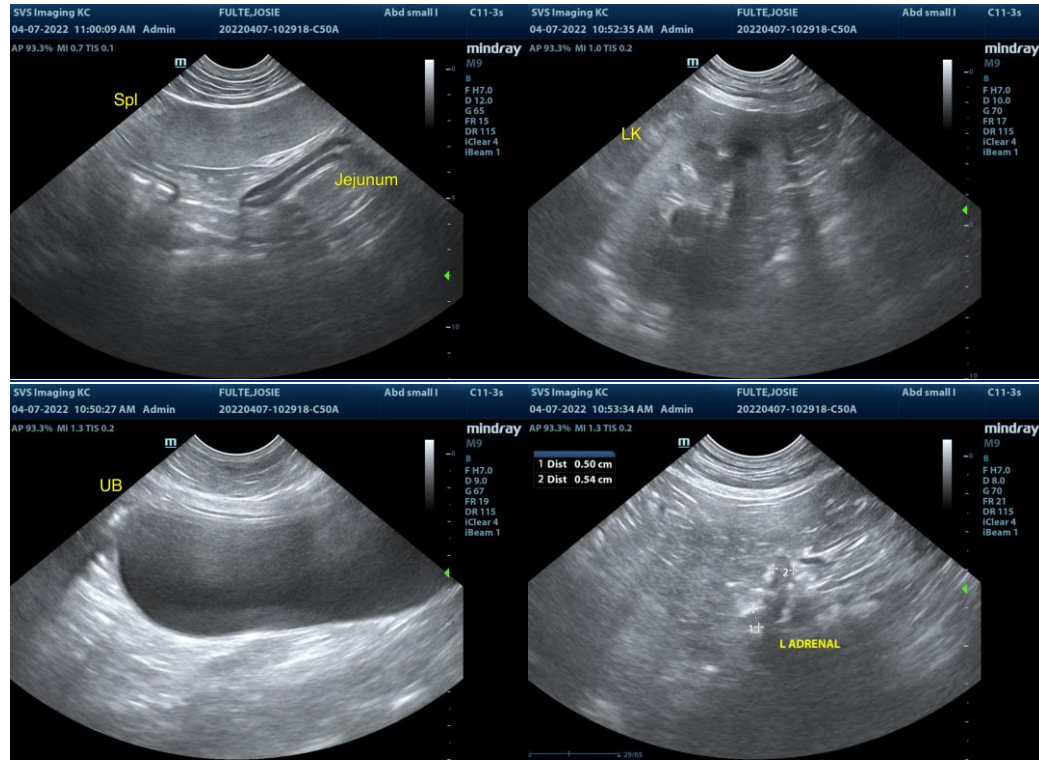
FS

AGE

5 years 4 months

WEIGHT

92 lbs.



INTERPRETED BY

R. McKenzie Daniel, DVM, DABVP (Canine and Feline)

IMAGING PERFORMED BY

Rachel Runnells, RVT

HOSPITAL NAME

SVS Imaging KC

REFERRING VET

Dr. Johathan Renfro

INVOICE

13636

DATE

4/7/22

The information and recommendations provided are based on the images presented by the referring veterinarian/sonographer. No evaluation can be communicated regarding pathology that was not visible in the image/video clips provided.

Thank you for this referral. If the clinical or image interpretation does not parallel your findings or if I can be of any further assistance please contact me.

R. McKenzie Daniel, DVM, DABVP (Canine / Feline Practice)
info@SonoPath.com