



**PATIENT**

Quinn Stuart

**SPECIES**

Canine

**BREED**

Portugese Water  
Dog

**SEX**

MN

**AGE**

6 years

**WEIGHT**

36.7 kg.

**INTERPRETED BY**

R. McKenzie Daniel,  
DVM, DABVP  
(Canine and Feline)

**IMAGING  
PERFORMED BY**

Dr Sarah Barthelemy

**HOSPITAL NAME**

Britannia Kingsland  
VC

**REFERRING VET**

Dr. Rondot

**INVOICE**

16540

**DATE**

4/6/23

**PRESENTING CLINICAL SIGNS**

Azotoemia identified on lab work. Concern for CKD vs other.

Abnormal PE/Chem/CBC/UA Results: SDMA 20, mild creat elevation 143, BUN mild elevation. USG 1.011.

**ULTRASONOGRAPHIC EXAMINATION OF THE ABDOMEN**

**Urinary System**

The urinary bladder, trigone, cystourethral junction, and visible pelvic urethra exhibited normal thickness and tone. Anechoic urine was present in the lumen with no uroliths, sediment, or calculi. The ureteral papillae were normal. The ureters were not visible which is normal. No evidence of inflammatory or neoplastic changes was noted.

The area of the aortic trifurcation was free of pathology.

Normal size and margination were present in the kidneys. A normal 1:3 cortex / medulla ratio was maintained. Mildly indistinct corticomedullary border demarcation was noted with discrete areas of pinpoint medullary mineral. There was no evidence of pyelectasia. The left kidney measured 6.1 cm in length. The right kidney measured 6.1 cm in length. No evidence of left or right retroperitoneal inflammation was noted.

**Adrenal Glands**

The left adrenal gland was uniform in size and contour with a uniformly hypoechoic parenchyma. The left adrenal gland measured 0.55 cm width at the caudal pole. The right adrenal gland was uniform in size and contour with a uniformly hypoechoic parenchyma. The right adrenal gland measured 0.58 cm width at the caudal pole and 0.48 cm width at the cranial pole.

**Spleen**

The spleen exhibited a finely textured and homogenous parenchyma which was hyperechoic to the liver and renal cortical parenchyma. The capsule was smooth and regular without apparent expansion. The splenic vasculature at the hilus was normal in volume with no evidence of congestion or thrombosis. Acute to chronic inflammatory, neoplastic, or benign parenchyma changes were not noted.

**Liver/ Gallbladder**

The liver was subjectively normal in size, structure, and contour. The liver parenchyma was uniform and hypoechoic to the spleen with a mild coarse echotexture. The hepatic and portal vasculature were normal in appearance without signs of congestion. The gallbladder was non-distended in size containing primarily anechoic content with minor, incidental, nonorganized, echogenic gallbladder debris. The cystic and common bile ducts were normal.

**Gastrointestinal**

The stomach presented intact wall layering with a normal wall layer ratio. The lumen of the stomach was empty with no signs of ileus, obstruction, or foreign material.



**PATIENT**

Quinn Stuart

**SPECIES**

Canine

**BREED**

Portugese Water Dog

**SEX**

MN

**AGE**

6 years

**WEIGHT**

36.7 kg.

**INTERPRETED BY**

R. McKenzie Daniel,  
DVM, DABVP  
(Canine and Feline)

**IMAGING PERFORMED BY**

Dr Sarah Barthelemy

**HOSPITAL NAME**

Britannia Kingsland  
VC

**REFERRING VET**

Dr. Rondot

**INVOICE**

16540

**DATE**

4/6/23

The small intestine presented intact wall layering with 1:3 muscularis/mucosa ratio. The lumen of the small intestine was empty with no signs of ileus, obstruction, or foreign material.

Normal visible colon wall layers were present with apparent formed feces in lumen.

***Pancreas***

The parenchyma of the left limb, body, and right limb of the pancreas presented isoechoic to the adjacent omental fat. A normal curvilinear capsule contour of the pancreas was present. The visible pancreatic duct was normal. No signs of active inflammation or neoplastic disease were evident.

***Free Abdomen***

No overt lymphadenopathy or peritoneal effusion was present.

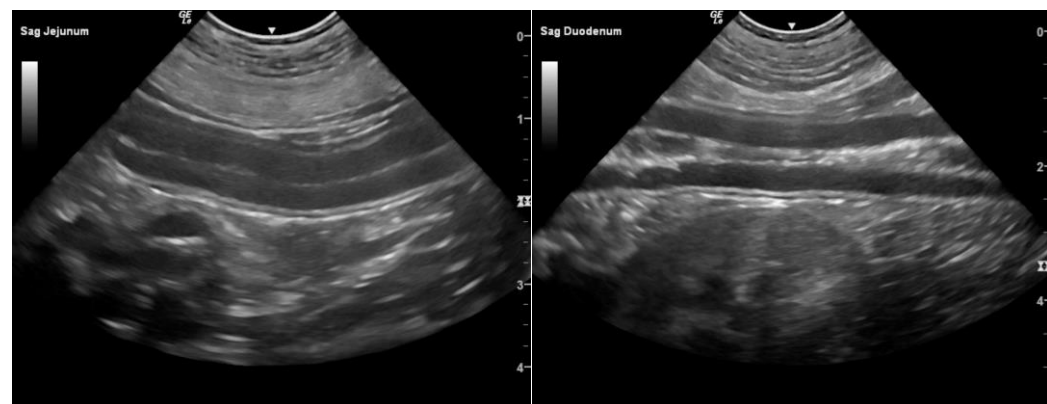
**ULTRASONOGRAPHIC FINDINGS**

- Sonographically unremarkable kidneys exhibiting discrete pinpoint medullary mineral
- Otherwise, sonographically unremarkable abdomen

**INTERPRETATION OF THE FINDINGS & FURTHER RECOMMENDATIONS**

There is no sonographic evidence of visceral, specifically renal pathology. The low-grade azotemia combined with decreased urine specific gravity, assuming no evidence of acute kidney injury, toxin exposure, etc., may suggest possible very early chronic kidney disease.

Baseline renal staging to include screening C/S and baseline UPC level could be considered. Early CKD therapy with continued monitoring of renal parameters going forward is suggested. Recheck sonogram is recommended if evidence of progressive azotemia.





**PATIENT**

Quinn Stuart

**SPECIES**

Canine

**BREED**

Portugese Water Dog

**SEX**

MN

**AGE**

6 years

**WEIGHT**

36.7 kg.

**INTERPRETED BY**

R. McKenzie Daniel,  
DVM, DABVP  
(Canine and Feline)

**IMAGING PERFORMED BY**

Dr Sarah Barthelemy

**HOSPITAL NAME**

Britannia Kingsland  
VC

**REFERRING VET**

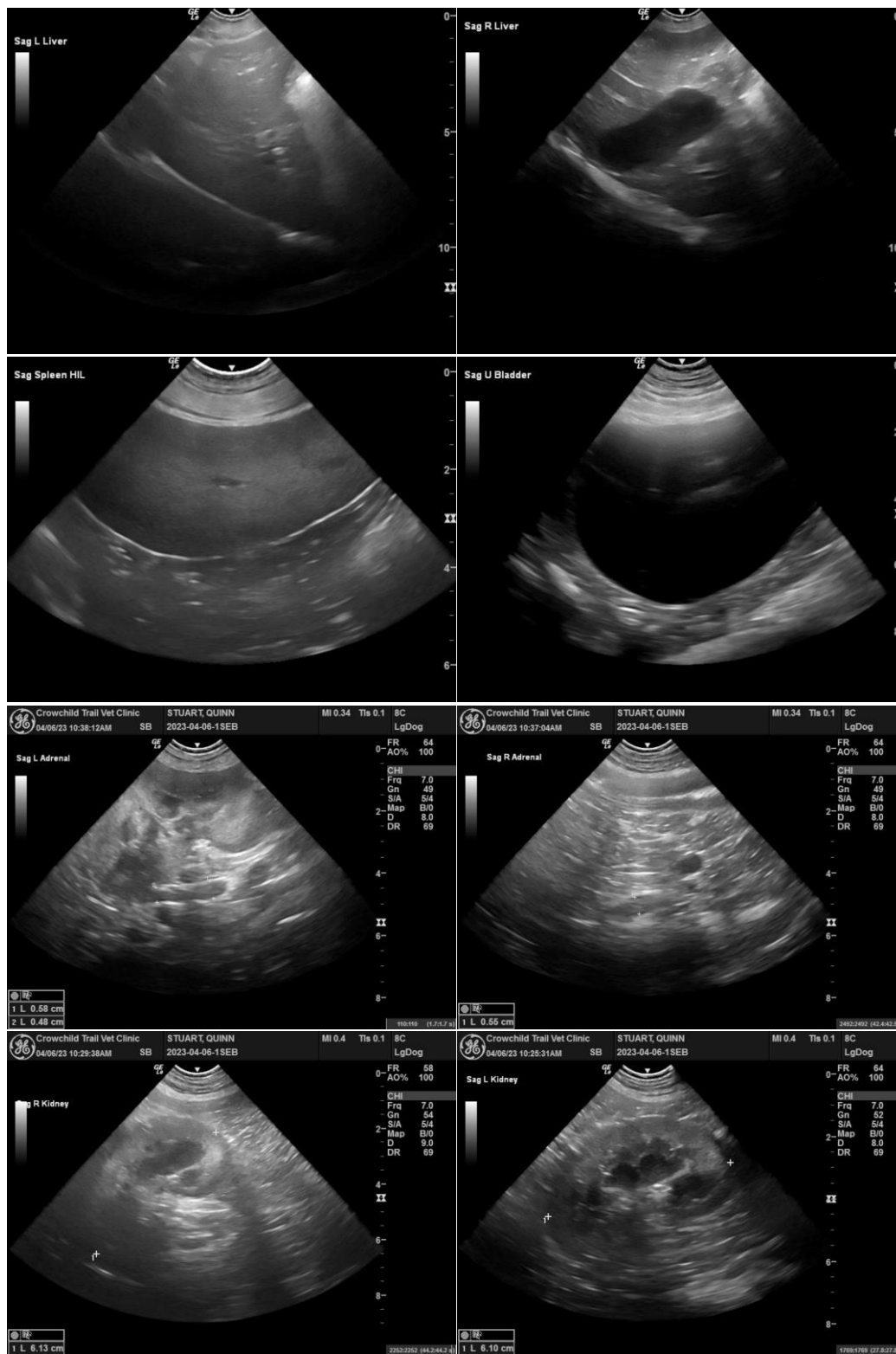
Dr. Rondot

**INVOICE**

16540

**DATE**

4/6/23





**PATIENT**

Quinn Stuart

**SPECIES**

Canine

**BREED**

Portugese Water  
Dog

**SEX**

MN

**AGE**

6 years

**WEIGHT**

36.7 kg.

**INTERPRETED BY**

R. McKenzie Daniel,  
DVM, DABVP  
(Canine and Feline)

**IMAGING  
PERFORMED BY**

Dr Sarah Barthelemy

**HOSPITAL NAME**

Britannia Kingsland  
VC

**REFERRING VET**

Dr. Rondot

**INVOICE**

16540

**DATE**

4/6/23

**The information and recommendations provided are based on the images presented by the referring veterinarian/sonographer. No evaluation can be communicated regarding pathology that was not visible in the image/video clips provided.**

Thank you for this referral. If the clinical or image interpretation does not parallel your findings or if I can be of any further assistance please contact me.

**R. McKenzie Daniel, DVM, DABVP (Canine / Feline Practice)**  
**info@SonoPath.com**