



**PATIENT PRESENTING CLINICAL SIGNS**

**PATIENT** Prada Salmon Was in heat and possibly mated early February. Would like to confirm pregnancy and viability if pregnant. No meds. No other concerns.

**SPECIES** Abnormal PE/Chem/CBC/UA Results: N/A

**Canine ULTRASONOGRAPHIC EXAMINATION OF THE URINARY SYSTEM AND UTERUS**

The urinary bladder, trigone, cystourethral junction, and visible pelvic urethra to a depth of 2.0 cm exhibited normal thickness and tone. Anechoic urine was present in the lumen with no uroliths or sediment. The ureteral papillae were normal. The ureters were not visible which is normal. No evidence of inflammatory or neoplastic changes was noted.

**BREED**  
American Bulldog

**SEX** The uterine body and left and right uterine horn walls were sonographically unremarkable. Mild segmental uterine body and left and right uterine horn luminal fluid was noted. The left uterine horn diameter measured 0.78 cm. No evidence of peri uterine inflammation was noted. No evidence of viable fetuses was visualized.

**AGE** The left and right ovaries were sonographically normal. The left ovary measured 1.7 cm in diameter. The right ovary measured 1.4 cm in diameter.

**WEIGHT ULTRASONOGRAPHIC FINDINGS**

- Sonographically unremarkable uterus with mild body and left and right uterine horn luminal fluid
- Normal bilateral ovaries

**INTERPRETED BY**

R. McKenzie Daniel,  
DVM, DABVP

**INTERPRETATION OF THE FINDINGS & FURTHER RECOMMENDATIONS**

No evidence of viable pregnancy was visualized. Assuming no current evidence of estrus or false pregnancy criteria, the mild uterine horn luminal fluid is likely incidental. Possible very early to emerging hydrometra, mucometra, or pyometra is thought less likely. However, monitoring for evidence of clinical signs consistent with uterine disease going forward and potential sonographic reassessment is suggested.

**IMAGING PERFORMED BY**

Crystal Hill

**HOSPITAL NAME**

Beatties East Hamilton  
PH

**REFERRING VET**

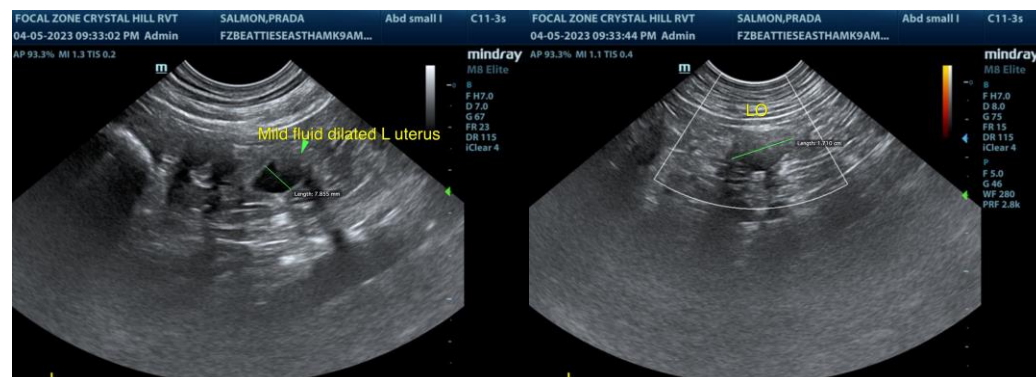
Puja

**INVOICE**

16503

**DATE**

4/5/23





**PATIENT**

Prada Salmon

**SPECIES**

Canine

**BREED**

American Bulldog

**SEX**

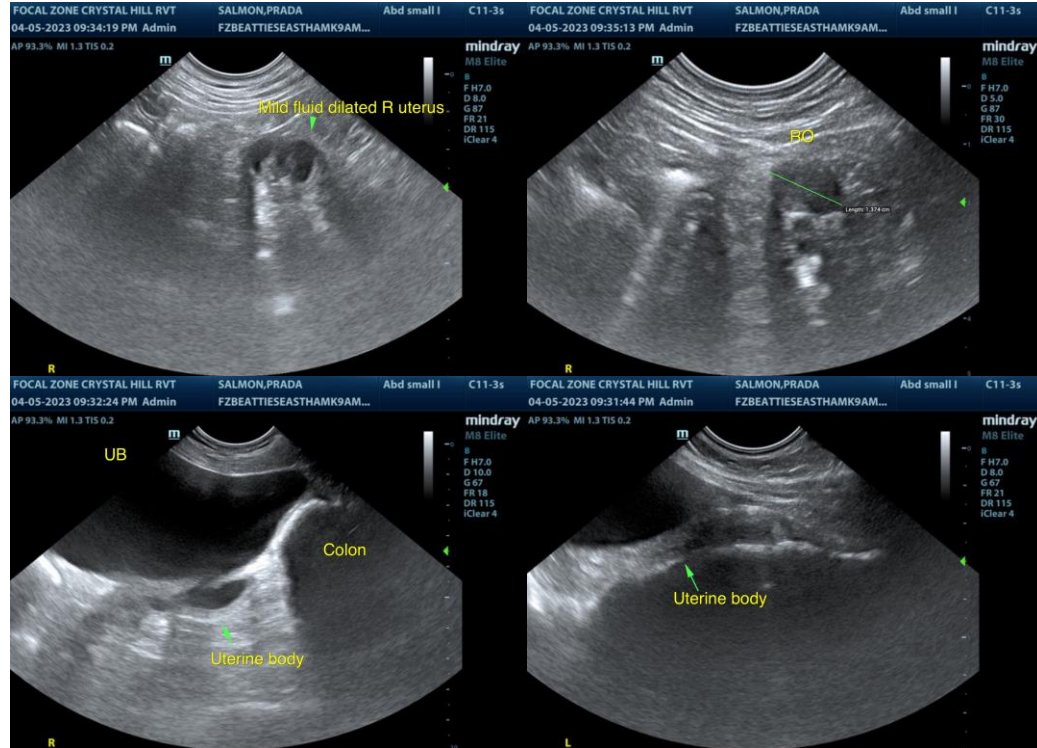
FI

**AGE**

2 years

**WEIGHT**

26.8 kg



**INTERPRETED BY**

R. McKenzie Daniel,  
DVM, DABVP

**IMAGING PERFORMED BY**

Crystal Hill

**HOSPITAL NAME**

Beatties East Hamilton  
PH

**REFERRING VET**

Puja

**INVOICE**

16503

**DATE**

4/5/23

The information and recommendations provided are based on the images presented by the referring veterinarian/sonographer. No evaluation can be communicated regarding pathology that was not visible in the image/video clips provided.

Thank you for this referral. If the clinical or image interpretation does not parallel your findings or if I can be of any further assistance please contact me.

**R. McKenzie Daniel, DVM, DABVP (Canine / Feline Practice)**  
info@SonoPath.com