



PATIENT

Misty Smith

SPECIES

Canine

BREED

Longhair Chihuahua

SEX

Female

AGE

13 Years

WEIGHT

11.6

INTERPRETED BY

R. McKenzie Daniel,
DVM, DABVP (Canine
/ Feline Practice)

IMAGING PERFORMED BY

Dr. Carlos Abdul-Chani

HOSPITAL NAME

Byram Animal Hospital

REFERRING VET

Dr. Maria Cruz

INVOICE

15601

DATE

04/30/26

PRESENTING CLINICAL SIGNS

Chronic cough / R/O Cardiac disease. Current Meds: Pred. 2.5 mgs: 1 tab SID / Hycodan 5 mgs: 1/2 tab Every 8-12 hrs

Abnormal PE/Chem/CBC/UA Results: 2/2026: CBC : Neutros = 12,104 / T4 = 0.6 Superchem: Alk Phos = 643 / Lipase = 170 ; All else WNL ; HW4DX = Neg. X 4 Abnormal UA: Not Done

ULTRASONOGRAPHIC EXAMINATION OF THE HEART

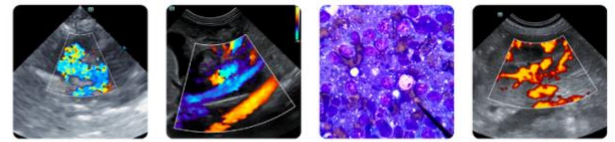
CANINE CARDIAC PARAMETERS	MR VMAX (m/s)	TR VMAX (m/s)	LA/AO (M-Mode)	LA/AO (Heart Base; Swe)	FS (%)	EF (%)	EPSS (cm)
NORMAL PARAMETER	4.5-5.5	<2.7	1.3	Up to 1.6	28-40	40-100	<0.6
PATIENT	--	--	NM	1.4	48	81	0.3
CANINE CARDIAC PARAMETERS	HR (BPM)	AV VMAX (m/s)	PV MAX (m/s)	BODY WEIGHT	LAD LA MAX 4 Chamber	LVIDd Avg; 2D and m-mode short axis (cm)	LVIDs Avg; 2D and m-mode short axis (cm)
NORMAL PARAMETER	50-100	0.7-1.7	0.7-1.6				
PATIENT	NM	1.5	1.0	11.6	2.0	2.0	--

Cardiac Presentation

The echocardiogram in this patient demonstrated normal **left atrial** size based on 3 different LA measurement methods. The cranial and caudal **mitral** valve leaflets presented mild thickening consistent with mild endocardiosis. Doppler revealed mild eccentric MR. The **left ventricle** presented thicknesses with linear contour and was not dilated nor restricted. The **myocardium** presented normal echogenicity without subjective evidence of significant fibrotic or ischemic disease. **Contractility** of the ventricular walls was adequate and in normal range for this patient evidenced by the fractional shortening measurement and subjective evaluation of the different regions of the myocardium. The **left ventricular outflow** tract demonstrated normal laminar flow and subjective structural integrity. The **right atrium** and auricle revealed normal size, structure and content. No evidence of masses was noted or chamber overload. **Tricuspid** valvular assessment demonstrated adequate linear morphology. The **right ventricle** was of normal size (1/3 diameter of LV), chordae structure, myocardial echogenicity and thickness. **Pulmonic** tract assessment revealed normal valve structure, laminar flow, and diameter (approx.1:1 pa/ao ratio). No visible **pericardial** or free pleura fluid was noted. No echographically detectable evidence of cardiac / pericardial tumors was visible. No evidence of arrhythmia or hepatic congestion.

ULTRASONOGRAPHIC FINDINGS

- Compensated mitral valve disease (B1).



PATIENT

Misty Smith

SPECIES

Canine

BREED

Longhair Chihuahua

SEX

Female

AGE

13 Years

WEIGHT

11.6

INTERPRETED BY

R. McKenzie Daniel,
DVM, DABVP (Canine
/ Feline Practice)

IMAGING PERFORMED BY

Dr. Carlos Abdul-Chani

HOSPITAL NAME

Byram Animal Hospital

REFERRING VET

Dr. Maria Cruz

INVOICE

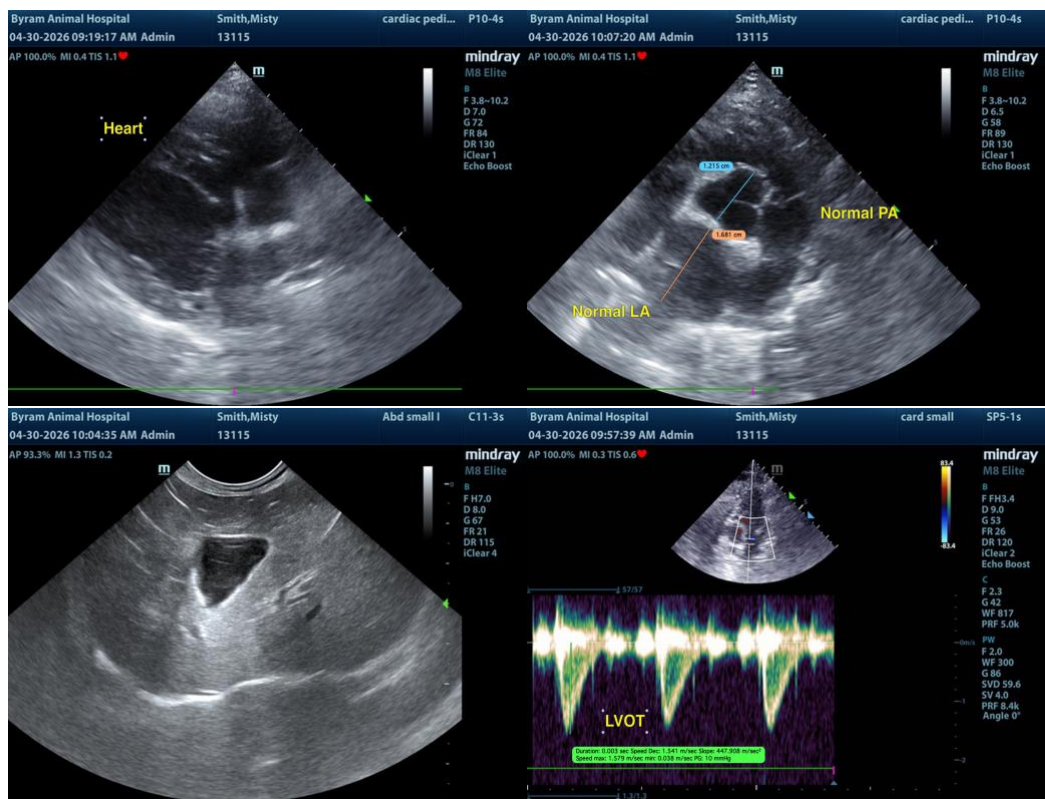
15601

DATE

04/30/26

INTERPRETATION OF THE FINDINGS & FURTHER RECOMMENDATIONS

The cause of the murmur is chronic degenerative valvular changes with secondary eccentric mitral valve insufficiency. The lack of left atrial enlargement implies that the risk of complication secondary to mitral valve insufficiency is low at this time and, without current clinical signs, indicates that medical therapy is not required. The coughing in this patient is noncardiogenic in origin without evidence of clinical pulmonary hypertension. Respiratory support is indicated. Prognosis is considered variable and sonographic monitoring is recommended. Recheck echo cardiogram is suggested in 6-12 months, sooner if clinical signs arise. Anesthetic risk is considered low. If required, the following protocol is suggested. Suggested anesthetic protocol may include opioid or Benzodiazepine pre-med, induction with Propofol or Alfaxalone, and appropriate gas anesthesia with avoidance of alpha 2 agonists.





PATIENT

Misty Smith

SPECIES

Canine

BREED

Longhair Chihuahua

SEX

Female

AGE

13 Years

WEIGHT

11.6

INTERPRETED BY

R. McKenzie Daniel,
DVM, DABVP (Canine
/ Feline Practice)

IMAGING PERFORMED BY

Dr. Carlos Abdul-Chani

HOSPITAL NAME

Byram Animal Hospital

REFERRING VET

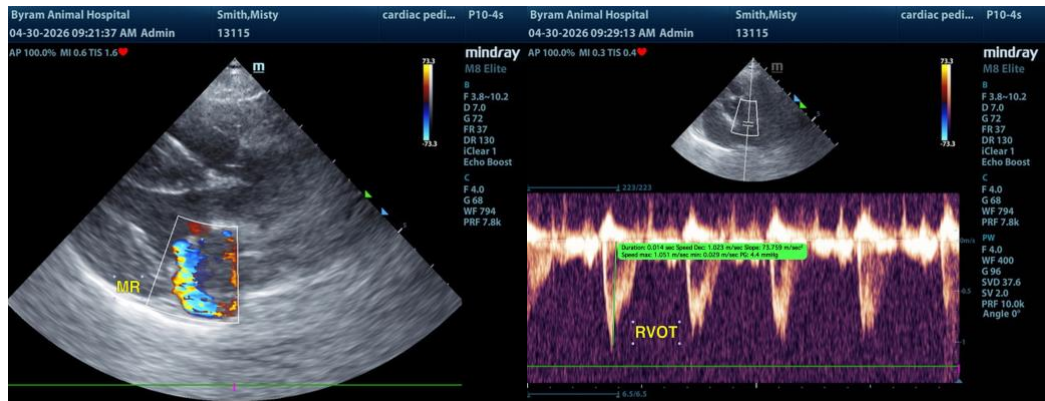
Dr. Maria Cruz

INVOICE

15601

DATE

04/30/26



The information and recommendations provided are based on the images presented by the referring veterinarian/sonographer. No evaluation can be communicated regarding pathology that was not visible in the image/video clips provided.

Thank you for this referral. If the clinical or image interpretation does not parallel your findings or if I can be of any further assistance, please contact me.

R. McKenzie Daniel, DVM, DABVP (Canine / Feline Practice)

info@SonoPath.com