



PATIENT

Maya Werkheiser

SPECIES

Canine

BREED

Chihuahua

SEX

Spayed Female

AGE

11 Years 2 Months

WEIGHT

7.0 lbs

INTERPRETED BY

R. McKenzie Daniel,
DVM, DABVP (Canine
/ Feline Practice)

IMAGING PERFORMED BY

Shari Reffi CVT

HOSPITAL NAME

William Penn
Veterinary Hospital

REFERRING VET

Dr. Mahmoud

INVOICE

15605

DATE

04/30/26

PRESENTING CLINICAL SIGNS

Grade 4 heart murmur

ULTRASONOGRAPHIC EXAMINATION OF THE HEART

CANINE CARDIAC PARAMETERS	MR VMAX (m/s)	TR VMAX (m/s)	LA/AO (M-Mode)	LA/AO (Heart Base; Swe)	FS (%)	EF (%)	EPSS (cm)
NORMAL PARAMETER	4.5-5.5	<2.7	1.3	Up to 1.6	28-40	40-100	<0.6
PATIENT	6.0	3.0	NM	1.2	44	78	0.2
CANINE CARDIAC PARAMETERS	HR (BPM)	AV VMAX (m/s)	PV MAX (m/s)	BODY WEIGHT (lbs)	LAD LA MAX 4 Chamber	LVIDd Avg; 2D and m-mode short axis (cm)	LVIDs Avg; 2D and m-mode short axis (cm)
NORMAL PARAMETER	50-100	0.7-1.7	0.7-1.6				
PATIENT	121	1.4	0.94	7.0	2.4	2.4	--

Cardiac Presentation

The echocardiogram in this patient demonstrated normal **left atrial** size based on 2 different LA measurement methods. The cranial and caudal **mitral** valve leaflets presented mild thickening consistent with endocardiosis. Doppler revealed moderate eccentric MR. The **left ventricle** presented thicknesses with linear contour and was not dilated nor restricted. The **myocardium** presented normal echogenicity without subjective evidence of significant fibrotic or ischemic disease. **Contractility** of the ventricular walls was adequate and in normal range for this patient evidenced by the fractional shortening measurement and subjective evaluation of the different regions of the myocardium. The **left ventricular outflow** tract demonstrated normal laminar flow and subjective structural integrity. The **right atrium** and auricle revealed normal size, structure and content. No evidence of masses was noted or chamber overload. **Tricuspid** valvular assessment demonstrated mild thickening with mild TR on doppler. The **right ventricle** was of normal size (1/3 diameter of LV), chordae structure, myocardial echogenicity and thickness. **Pulmonic** tract assessment revealed normal valve structure, laminar flow, and diameter (approx.1:1 pa/ao ratio). No visible **pericardial** or free pleura fluid was noted. No echographically detectable evidence of cardiac / pericardial tumors was visible.

ULTRASONOGRAPHIC FINDINGS

- Compensated chronic mitral valve disease (B1).
- Tricuspid insufficiency- estimated pulmonary pressure gradient consistent with mild increased pulmonary pressure without evidence of clinical pulmonary hypertension.

INTERPRETATION OF THE FINDINGS & FURTHER RECOMMENDATIONS



PATIENT

Maya Werkheiser

SPECIES

Canine

BREED

Chihuahua

SEX

Spayed Female

AGE

11 Years 2 Months

WEIGHT

7.0 lbs

INTERPRETED BY

R. McKenzie Daniel,
 DVM, DABVP (Canine
 / Feline Practice)

IMAGING PERFORMED BY

Shari Reffi CVT

HOSPITAL NAME

William Penn
 Veterinary Hospital

REFERRING VET

Dr. Mahmoud

INVOICE

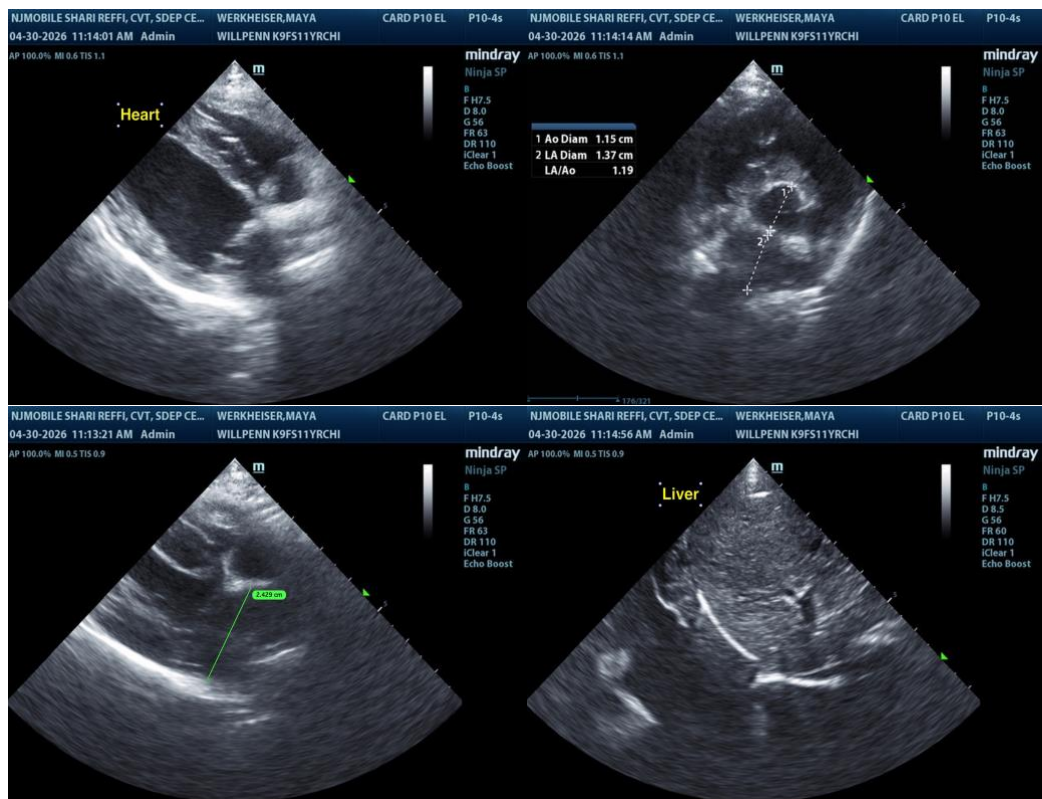
15605

DATE

04/30/26

The cause of the murmur is chronic degenerative valvular changes with secondary eccentric mitral valve insufficiency. The lack of left atrial enlargement implies that the risk of complication secondary to mitral valve insufficiency is low at this time and, without current clinical signs, indicates that medical therapy is not required. Prognosis is considered variable and sonographic monitoring is recommended. Recheck echo cardiogram is suggested in 6-12 months, sooner if clinical signs arise.

Cardiac anesthetic risk is considered mild. If required, the following protocol is suggested. Suggested anesthetic protocol may include opioid or Benzodiazepine pre-med, induction with Propofol or Alfaxalone, and appropriate gas anesthesia with avoidance of alpha 2 agonists.





PATIENT

Maya Werkheiser

SPECIES

Canine

BREED

Chihuahua

SEX

Spayed Female

AGE

11 Years 2 Months

WEIGHT

7.0 lbs

INTERPRETED BY

R. McKenzie Daniel, DVM, DABVP (Canine / Feline Practice)

IMAGING PERFORMED BY

Shari Reffi CVT

HOSPITAL NAME

William Penn Veterinary Hospital

REFERRING VET

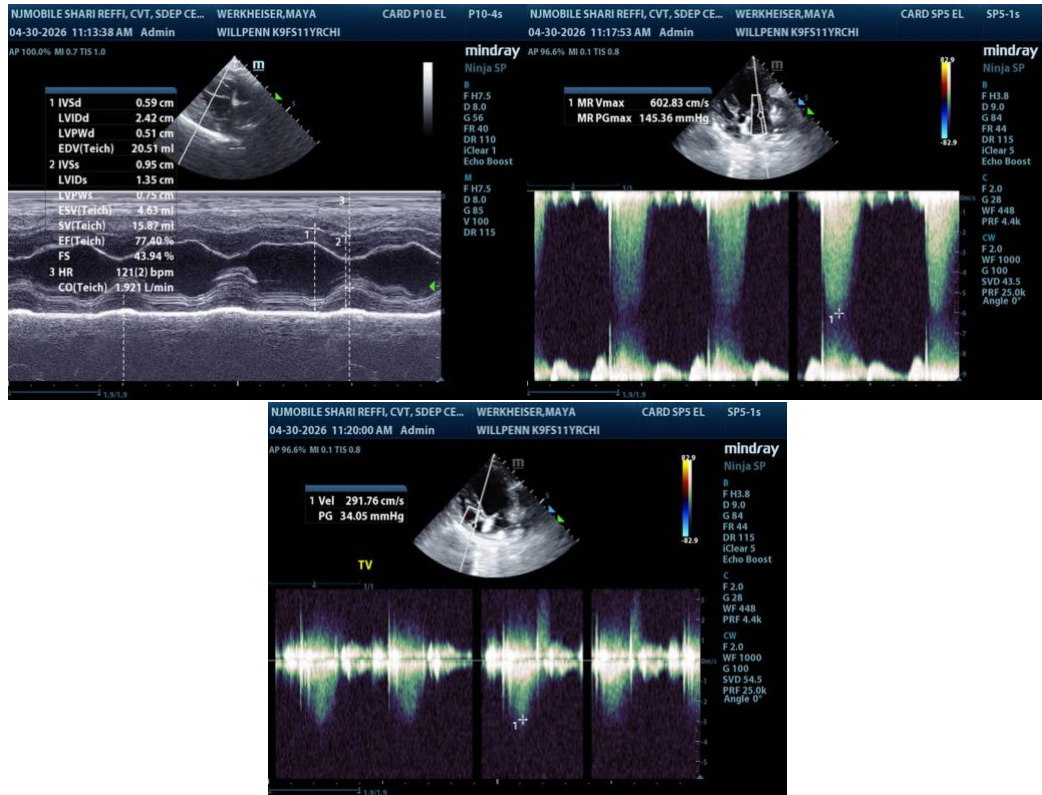
Dr. Mahmoud

INVOICE

15605

DATE

04/30/26



The information and recommendations provided are based on the images presented by the referring veterinarian/sonographer. No evaluation can be communicated regarding pathology that was not visible in the image/video clips provided.

Thank you for this referral. If the clinical or image interpretation does not parallel your findings or if I can be of any further assistance, please contact me.

R. McKenzie Daniel, DVM, DABVP (Canine / Feline Practice)

info@SonoPath.com