



PATIENT

Maya Epple

SPECIES

Canine

BREED

Boxer

SEX

Spayed Female

AGE

9 Years

WEIGHT

65 lbs

INTERPRETED BY

R. McKenzie Daniel,
DVM, DABVP (Canine
/ Feline Practice)

IMAGING PERFORMED BY

Shari Reffi CVT

HOSPITAL NAME

Harmony Animal
Hospital

REFERRING VET

Dr. Epple

INVOICE

15604

DATE

04/30/26

PRESENTING CLINICAL SIGNS

BCS 4/9. Coughing, serosanguinous pleural effusion ~ 1L retrieved. No heart murmur. HR ~148 bpm. Current Medications: Incurin, Meloxicam

ULTRASONOGRAPHIC EXAMINATION OF THE HEART & ABDOMEN

CANINE CARDIAC PARAMETERS	MR VMAX (m/s)	TR VMAX (m/s)	LA/AO (M-Mode)	LA/AO (Heart Base; Swe)	FS (%)	EF (%)	EPSS (cm)
NORMAL PARAMETER	4.5-5.5	<2.7	1.3	Up to 1.6	28-40	40-100	<0.6
PATIENT	--	--	NM	1.25	30	58	0.6
CANINE CARDIAC PARAMETERS	HR (BPM)	AV VMAX (m/s)	PV MAX (m/s)	BODY WEIGHT (lbs)	LAD LA MAX 4 Chamber	LVIDd Avg; 2D and m-mode short axis (cm)	LVIDs Avg; 2D and m-mode short axis (cm)
NORMAL PARAMETER	50-100	0.7-1.7	0.7-1.6				
PATIENT	NM	1.0	0.8	65.0	4.2	4.3	--

Cardiac Presentation

The echocardiogram in this patient demonstrated normal **left atrial** size based on 2 separate methods of LA evaluation. The cranial and caudal **mitral** valve leaflets presented normal linear structure, extension in systole, and union in diastole with normal kinesis. No MR on doppler. The **left ventricle** presented thicknesses with linear contour and was not dilated nor restricted. The **myocardium** presented normal echogenicity without subjective evidence of significant fibrotic or ischemic disease. **Contractility** of the ventricular walls was subnormal as evidenced by the fractional shortening measurement and subjective evaluation of the myocardium. The **left ventricular outflow** tract demonstrated normal laminar flow and subjective structural integrity. The **right atrium** and auricle revealed normal size, structure and content. No evidence of masses was noted. **Tricuspid** valvular assessment demonstrated adequate linear morphology and kinesis. The **right ventricle** was of normal size (1/3 diameter of LV), chordae structure, myocardial echogenicity and thickness. **Pulmonary outflow** tract assessment revealed normal valve structure, laminar flow, and diameter (approx.1:1 pa/ao ratio). No visible **pericardial** or free pleura fluid was noted. No visible pericardial effusion with moderate volume of mildly echogenic pleural effusion. Pericardial to caudal thoracic/peridiaphragmatic nonhomogenous mass lesions were present with an example measuring 5.0 cm x 1.7 cm adjacent to the diaphragm as well as 4.5 cm x 3.3 cm adjacent to the heart.

Urinary System

The urinary bladder, trigone, cystourethral junction, and visible pelvic urethra to a depth of 3.0 cm exhibited normal thickness and tone. Anechoic urine was present in the lumen with no uroliths or



PATIENT

Maya Epple

SPECIES

Canine

BREED

Boxer

SEX

Spayed Female

AGE

9 Years

WEIGHT

65 lbs

INTERPRETED BY

R. McKenzie Daniel,
 DVM, DABVP (Canine
 / Feline Practice)

IMAGING PERFORMED BY

Shari Reffi CVT

HOSPITAL NAME

Harmony Animal
 Hospital

REFERRING VET

Dr. Epple

INVOICE

15604

DATE

04/30/26

sediment. The ureteral papillae were normal. The ureters were not visible which is normal. No evidence of inflammatory or neoplastic change were noted.

Normal size and margination was present in the kidneys. A normal 1:3 cortex / medulla ratio and normal corticomedullary definition were maintained. The echogenicity of the cortex was similar to or slightly less than normal liver parenchyma while the medulla echogenicity was hypoechoic to the cortex with no evidence of pelvic dilation. The left kidney measured 6.4 cm in length. The right kidney measured 7.0 cm in length.

Adrenal Glands

The left adrenal gland was uniform in size and contour with a uniformly hypoechoic parenchyma. The left adrenal gland measured 0.75 cm width at the caudal pole.

The right adrenal gland was uniform in size and contour with a uniformly hypoechoic parenchyma. The right adrenal gland measured 0.50 cm width at the caudal pole.

Spleen

The spleen exhibited a finely textured and homogenous parenchyma which was hyperechoic to the liver and renal cortical parenchyma. The capsule was smooth and regular without apparent expansion. The splenic vasculature at the hilus was normal in volume with no evidence of congestion or thrombosis. Acute to chronic inflammatory, neoplastic, or benign parenchyma changes were not noted.

Liver & Gallbladder

The liver was subjectively normal in size, structure, and contour. The liver parenchyma was uniform and hypoechoic to the spleen with a mild coarse echotexture. The hepatic and portal vasculature were normal in appearance without signs of congestion.

The gallbladder was non-distended in size with thin walls and primarily anechoic luminal content. The cystic and common bile ducts were normal.

Gastrointestinal

The stomach presented intact wall layering with a normal wall layer ratio. The lumen of the stomach was empty with no signs of ileus, obstruction or foreign material.

The small intestine presented intact wall layering with 1:3 muscularis/mucosa ratio. The lumen of the small intestine was empty with no signs of ileus, obstruction or foreign material.

Normal visible colon wall layers were present with apparent formed feces in lumen.

Pancreas

The parenchyma of the left limb, body and right limb of the pancreas presented isoechoic to the adjacent omental fat. A normal curvilinear capsule contour of the pancreas was present. The visible pancreatic duct was normal. No signs of active inflammation or neoplastic disease was evident.

Free Abdomen

No significant visualized omental lymphadenopathy, abdominal masses or peritoneal effusion was present.



PATIENT

Maya Epple

SPECIES

Canine

BREED

Boxer

SEX

Spayed Female

AGE

9 Years

WEIGHT

65 lbs

INTERPRETED BY

R. McKenzie Daniel,
 DVM, DABVP (Canine
 / Feline Practice)

IMAGING PERFORMED BY

Shari Reffi CVT

HOSPITAL NAME

Harmony Animal
 Hospital

REFERRING VET

Dr. Epple

INVOICE

15604

DATE

04/30/26

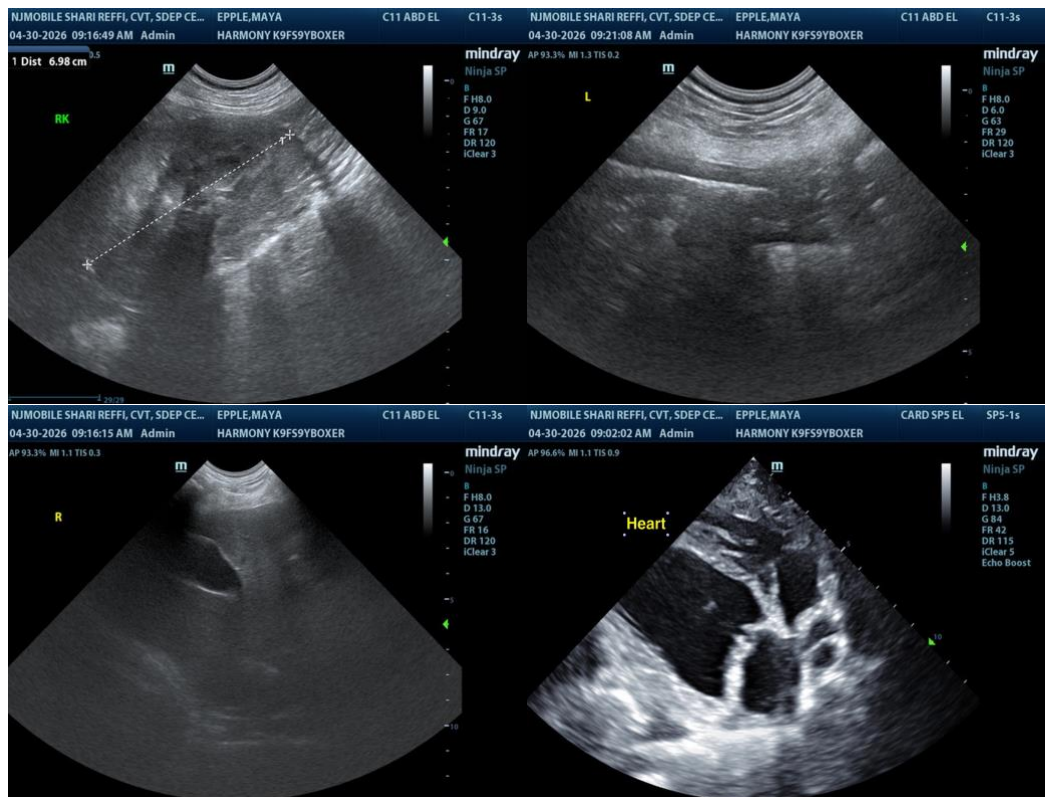
ULTRASONOGRAPHIC FINDINGS

- Normal echocardiogram with borderline LV hypocontractility- systemic disease, age variant, sedation if clinically applicable, possible DCM was not met.
- Pleural effusion with pericardial/transdiaphragmatic mass-like lesions.
- Sonographically normal abdomen.

INTERPRETATION OF THE FINDINGS & FURTHER RECOMMENDATIONS

The pleural effusion is non-cardiogenic in origin. Considerations for intrathoracic pathology may include inflammatory, infectious, granulomatous, or neoplastic etiologies with neoplasia suspected. Correlation with pleural effusion analysis, cytospin cytology +/- culture and sensitivity if evidence of effusion inflammatory component is recommended. No indication for cardiac medications.

No evidence of abdominal pathology as a contributing factor.





PATIENT

Maya Epple

SPECIES

Canine

BREED

Boxer

SEX

Spayed Female

AGE

9 Years

WEIGHT

65 lbs

INTERPRETED BY

R. McKenzie Daniel,
 DVM, DABVP (Canine
 / Feline Practice)

**IMAGING
 PERFORMED BY**

Shari Reffi CVT

HOSPITAL NAME

Harmony Animal
 Hospital

REFERRING VET

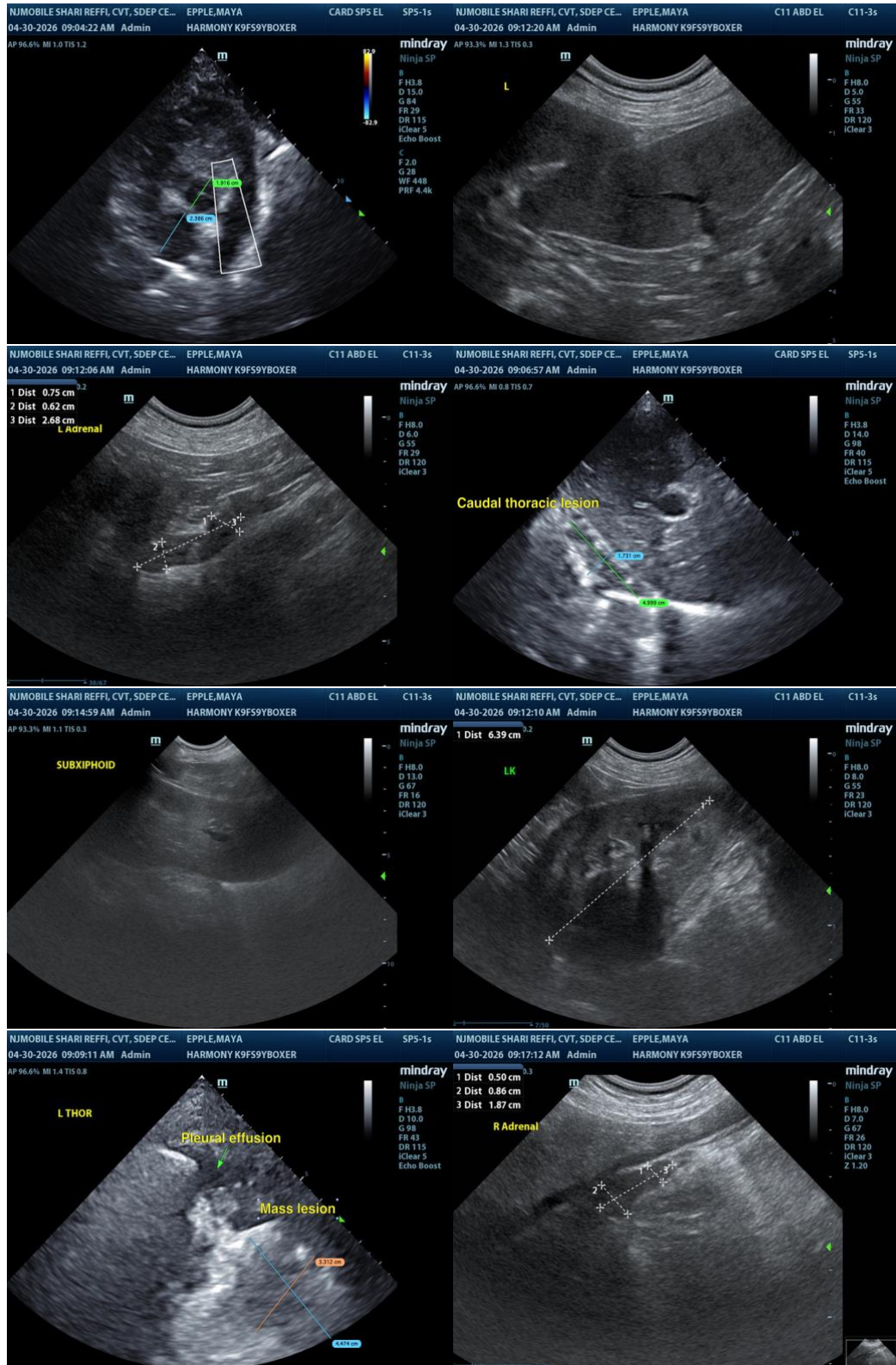
Dr. Epple

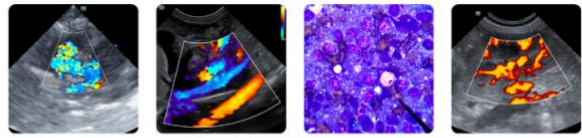
INVOICE

15604

DATE

04/30/26





PATIENT

Maya Epple

The information and recommendations provided are based on the images presented by the referring veterinarian/sonographer. No evaluation can be communicated regarding pathology that was not visible in the image/video clips provided.

SPECIES

Canine

Thank you for this referral. If the clinical or image interpretation does not parallel your findings or if I can be of any further assistance, please contact me.

R. McKenzie Daniel, DVM, DABVP (Canine / Feline Practice)

BREED

Boxer

info@SonoPath.com

SEX

Spayed Female

AGE

9 Years

WEIGHT

65 lbs

INTERPRETED BY

R. McKenzie Daniel,
DVM, DABVP (Canine
/ Feline Practice)

**IMAGING
PERFORMED BY**

Shari Reffi CVT

HOSPITAL NAME

Harmony Animal
Hospital

REFERRING VET

Dr. Epple

INVOICE

15604

DATE

04/30/26