



PATIENT

Maddie Attaway

SPECIES

Canine

BREED

Shepherd Mix

SEX

Spayed Female

AGE

16

WEIGHT

49

INTERPRETED BY

R. McKenzie Daniel,
DVM, DABVP (Canine
/ Feline Practice)

IMAGING PERFORMED BY

Dr. Hannah Fearing

HOSPITAL NAME

Lanier Animal Hospital

REFERRING VET

Dr. Hannah Fearing

INVOICE

15600

DATE

04/30/26

PRESENTING CLINICAL SIGNS

The patient is presenting for a scheduled abdominal ultrasound. The owner reports that a previously aspirated mass on the patient's abdomen has become larger. The owner also states the patient's cough has WORSENERD, noting an episode last night where the patient fell from the couch and began coughing severely upon impact. The patient is currently being treated with unspecified medication for a urinary tract infection. The owner reports no vomiting or diarrhea. The patient was fasted prior to the appointment, with no food or water given this morning.

ULTRASONOGRAPHIC EXAMINATION OF THE ABDOMEN

Urinary System

The urinary bladder, trigone, cystourethral junction, and visible pelvic urethra to a depth of 3.0 cm exhibited normal thickness and tone. Anechoic urine was present in the lumen with no uroliths or sediment. The ureteral papillae were normal. The ureters were not visible which is normal. No evidence of inflammatory or neoplastic change were noted.

Normal size and margination was present in the kidneys. A normal 1:3 cortex / medulla ratio was maintained. The medulla and cortices were uniform in texture with some increased echogenicity and mild loss of corticomedullary symmetry and definition expected for the age of the patient. No evidence of pelvic dilation was present. The left kidney measured 5.5 cm in length. The right kidney measured 5.8 cm in length.

Adrenal Glands

The left adrenal gland was uniform in size and contour with a uniformly hypoechoic parenchyma. The left adrenal gland measured 0.68 cm width at the caudal pole.

The right adrenal gland was uniform in size and contour with a uniformly hypoechoic parenchyma. The right adrenal gland measured 0.66 cm width at the caudal pole.

Spleen

The spleen exhibited a finely textured and homogenous parenchyma which was hyperechoic to the liver and renal cortical parenchyma. The capsule was smooth and regular without apparent expansion. The splenic vasculature at the hilus was normal in volume with no evidence of congestion or thrombosis. Acute to chronic inflammatory, neoplastic, or benign parenchyma changes were not noted.

Liver & Gallbladder

The liver was subjectively normal in size, structure, and contour. The liver parenchyma was uniform and hypoechoic to the spleen with a mild coarse echotexture. The hepatic and portal vasculature were normal in appearance without signs of congestion.

The gallbladder was non-distended in size with thin walls and primarily anechoic luminal content. The cystic and common bile ducts were normal.

Gastrointestinal

The stomach presented intact wall layering with a normal wall layer ratio. The lumen of the stomach was empty with no signs of ileus, obstruction or foreign material.



PATIENT

Maddie Attaway

SPECIES

Canine

BREED

Shepherd Mix

SEX

Spayed Female

AGE

16

WEIGHT

49

INTERPRETED BY

R. McKenzie Daniel,
DVM, DABVP (Canine
/ Feline Practice)

IMAGING PERFORMED BY

Dr. Hannah Fearing

HOSPITAL NAME

Lanier Animal Hospital

REFERRING VET

Dr. Hannah Fearing

INVOICE

15600

DATE

04/30/26

The small intestine presented intact wall layering with 1:3 muscularis/mucosa ratio. The lumen of the small intestine was empty with no signs of ileus, obstruction or foreign material.

Normal visible colon wall layers were present with apparent formed feces in lumen.

Pancreas

The parenchyma of the left limb, body and right limb of the pancreas presented isoechoic to the adjacent omental fat. A normal curvilinear capsule contour of the pancreas was present. The visible pancreatic duct was normal. No signs of active inflammation or neoplastic disease was evident.

Free Abdomen

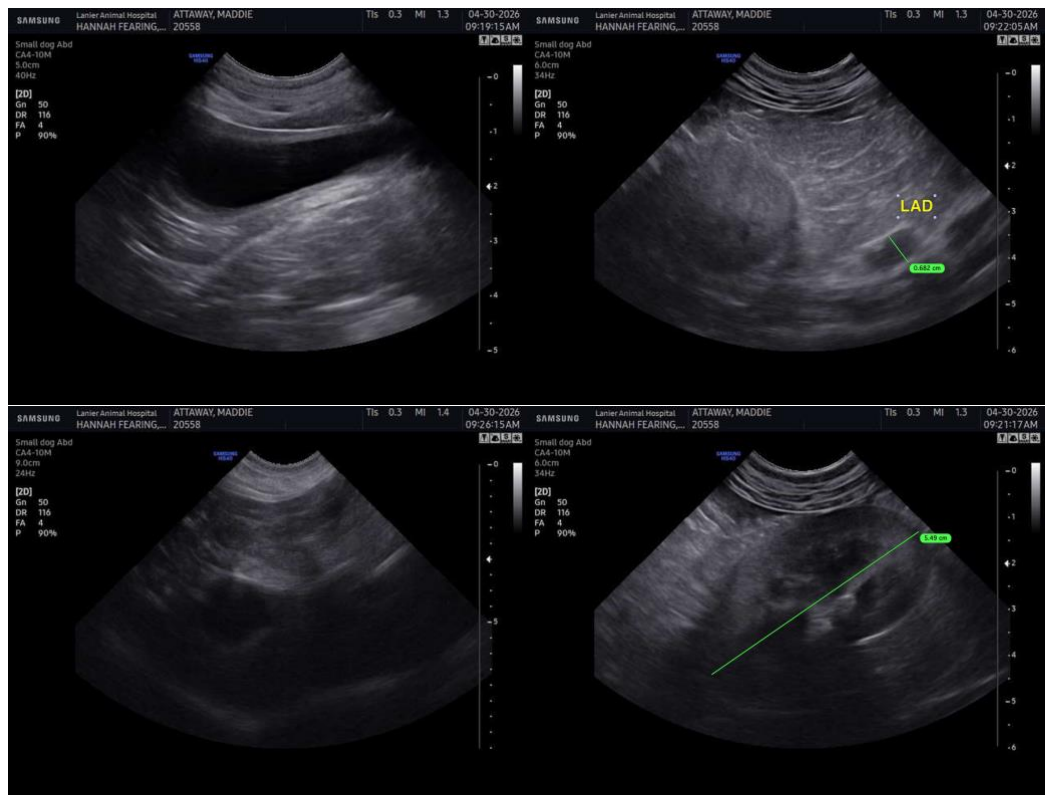
No overt lymphadenopathy or peritoneal effusion was present.

ULTRASONOGRAPHIC FINDINGS

- Sonographically unremarkable abdomen.
- Mild age-related kidneys.
- Normal urinary bladder and visible proximal urethra.

INTERPRETATION OF THE FINDINGS & FURTHER RECOMMENDATIONS

No evidence of visceral pathology.





PATIENT

Maddie Attaway

SPECIES

Canine

BREED

Shepherd Mix

SEX

Spayed Female

AGE

16

WEIGHT

49

INTERPRETED BY

R. McKenzie Daniel,
DVM, DABVP (Canine
/ Feline Practice)

IMAGING PERFORMED BY

Dr. Hannah Fearing

HOSPITAL NAME

Lanier Animal Hospital

REFERRING VET

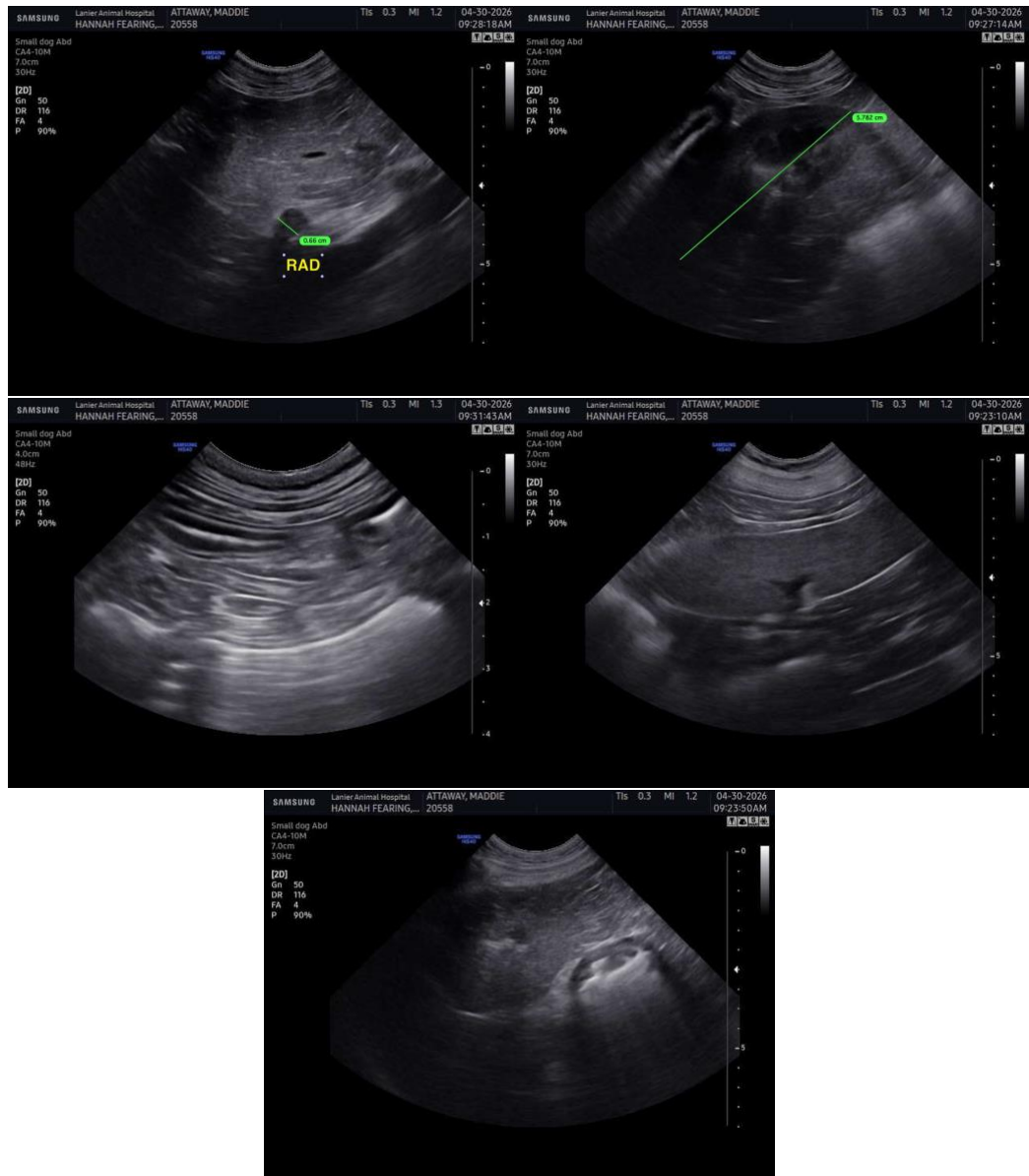
Dr. Hannah Fearing

INVOICE

15600

DATE

04/30/26



The information and recommendations provided are based on the images presented by the referring veterinarian/sonographer. No evaluation can be communicated regarding pathology that was not visible in the image/video clips provided.

Thank you for this referral. If the clinical or image interpretation does not parallel your findings or if I can be of any further assistance, please contact me.

R. McKenzie Daniel, DVM, DABVP (Canine / Feline Practice)

info@SonoPath.com