



PATIENT

Jameson Weaver

SPECIES

Canine

BREED

Pitbull

SEX

Neutered Male

AGE

2018

WEIGHT

82

INTERPRETED BY

R. McKenzie Daniel,
DVM, DABVP (Canine
/ Feline Practice)

IMAGING PERFORMED BY

Rebekah Jakum, CVT,
ARDMS/RVT

HOSPITAL NAME

Hellertown Veterinary
Center

REFERRING VET

Dr. Amber Bauer

INVOICE

15628

DATE

04/30/26

PRESENTING CLINICAL SIGNS

Preventive screening, no symptoms

Medication: Rejensa

ULTRASONOGRAPHIC EXAMINATION OF THE ABDOMEN

Urinary System

The urinary bladder, trigone, cystourethral junction, and visible pelvic urethra to a depth of 3.0 cm exhibited normal thickness and tone. Anechoic urine was present in the lumen with no uroliths or sediment. The ureteral papillae were normal. The ureters were not visible which is normal. No evidence of inflammatory or neoplastic change were noted.

The area of the residual prostate appeared normal and free of pathology.

Normal size and margination was present in the kidneys. A normal 1:3 cortex / medulla ratio and normal corticomedullary definition were maintained. The echogenicity of the cortex was similar to or slightly less than normal liver parenchyma while the medulla echogenicity was hypoechoic to the cortex with no evidence of pelvic dilation. The left kidney measured 7.3 cm in length. The right kidney measured 7.1 cm in length.

Adrenal Glands

The left adrenal gland was uniform in size and contour with a uniformly hypoechoic parenchyma. The left adrenal gland measured 0.75 cm width at the caudal pole.

The right adrenal gland was uniform in size and contour with a uniformly hypoechoic parenchyma. The right adrenal gland measured 0.82 cm width at the caudal pole.

Spleen

The spleen exhibited a finely textured and homogenous parenchyma which was hyperechoic to the liver and renal cortical parenchyma. The capsule was smooth and regular without apparent expansion. The splenic vasculature at the hilus was normal in volume with no evidence of congestion or thrombosis. Acute to chronic inflammatory, neoplastic, or benign parenchyma changes were not noted.

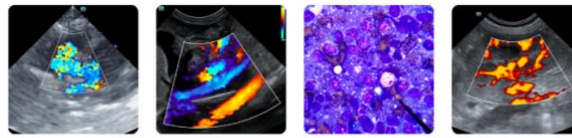
Liver & Gallbladder

The liver was subjectively normal in size, structure, and contour. The liver parenchyma was uniform and hypoechoic to the spleen with a mild coarse echotexture. The hepatic and portal vasculature were normal in appearance without signs of congestion.

The gallbladder was non-distended in size with thin walls and primarily anechoic luminal content. The cystic and common bile ducts were normal.

Gastrointestinal

The stomach presented intact wall layering with a normal wall layer ratio. The lumen of the stomach was empty with no signs of ileus, obstruction or foreign material.



PATIENT

Jameson Weaver

SPECIES

Canine

BREED

Pitbull

SEX

Neutered Male

AGE

2018

WEIGHT

82

INTERPRETED BY

R. McKenzie Daniel,
 DVM, DABVP (Canine
 / Feline Practice)

IMAGING PERFORMED BY

Rebekah Jakum, CVT,
 ARDMS/RVT

HOSPITAL NAME

Hellertown Veterinary
 Center

REFERRING VET

Dr. Amber Bauer

INVOICE

15628

DATE

04/30/26

The small intestine presented intact wall layering with 1:3 muscularis/mucosa ratio. The lumen of the small intestine was empty with no signs of ileus, obstruction or foreign material.

Normal visible colon wall layers were present with apparent formed feces in lumen.

Pancreas

The parenchyma of the left limb, body and right limb of the pancreas presented isoechoic to the adjacent omental fat. A normal curvilinear capsule contour of the pancreas was present. The visible pancreatic duct was normal. No signs of active inflammation or neoplastic disease was evident.

Free Abdomen

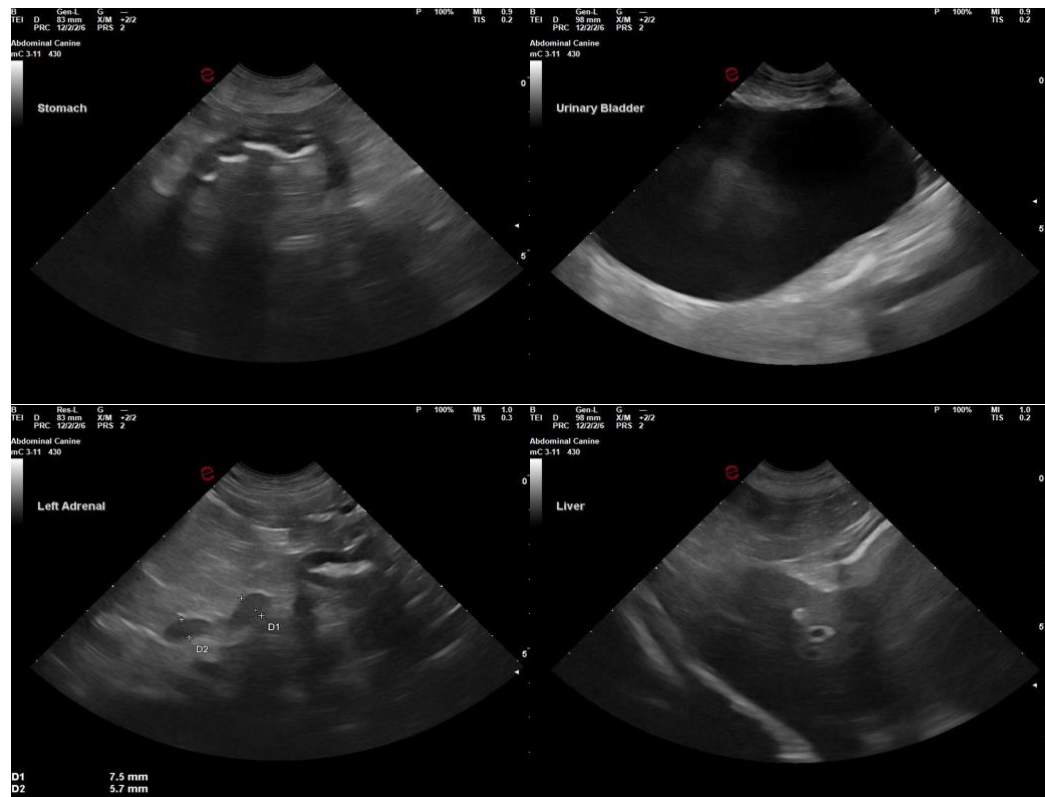
No overt lymphadenopathy or peritoneal effusion was present.

ULTRASONOGRAPHIC FINDINGS

- Sonographically normal abdomen.

INTERPRETATION OF THE FINDINGS & FURTHER RECOMMENDATIONS

No evidence of abdominal visceral pathology.





PATIENT

Jameson Weaver

SPECIES

Canine

BREED

Pitbull

SEX

Neutered Male

AGE

2018

WEIGHT

82

INTERPRETED BY

R. McKenzie Daniel,
 DVM, DABVP (Canine
 / Feline Practice)

IMAGING PERFORMED BY

Rebekah Jakum, CVT,
 ARDMS/RVT

HOSPITAL NAME

Hellertown Veterinary
 Center

REFERRING VET

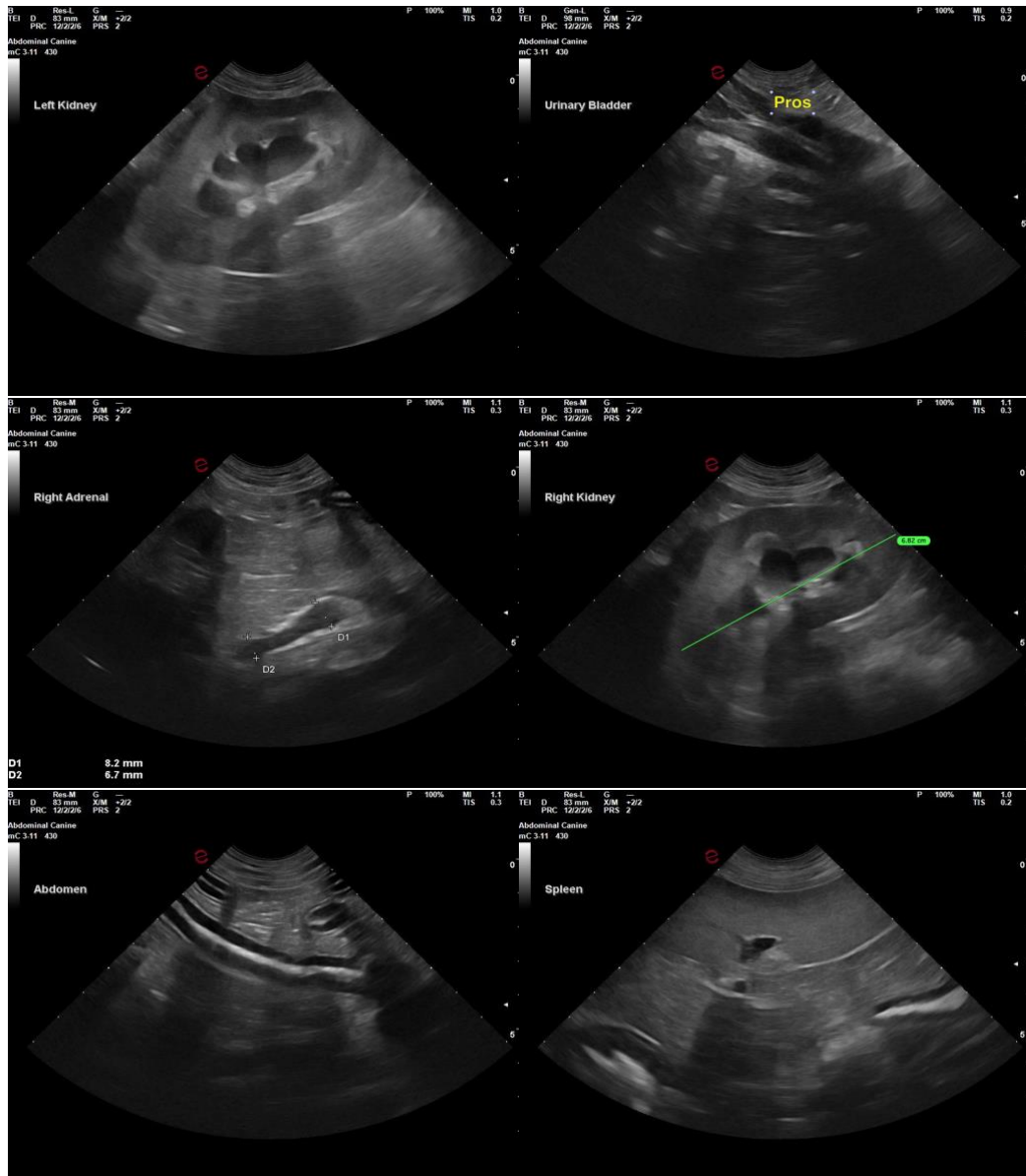
Dr. Amber Bauer

INVOICE

15628

DATE

04/30/26



The information and recommendations provided are based on the images presented by the referring veterinarian/sonographer. No evaluation can be communicated regarding pathology that was not visible in the image/video clips provided.

Thank you for this referral. If the clinical or image interpretation does not parallel your findings or if I can be of any further assistance, please contact me.

R. McKenzie Daniel, DVM, DABVP (Canine / Feline Practice)

info@SonoPath.com