



**PATIENT**

Curtis Rowan

**SPECIES**

Canine

**BREED**

Mixed

**SEX**

NM

**AGE**

4 years

**WEIGHT**

17.2 lbs.

**INTERPRETED BY**

R. McKenzie Daniel,  
 DVM, DABVP  
 (Canine and Feline)

**IMAGING PERFORMED BY**

Rebecca Hamilton

**HOSPITAL NAME**

American Animal  
 Hospital

**REFERRING VET**

Dr. Pascucci

**INVOICE**

10854

**DATE**

4/30/26

**PRESENTING CLINICAL SIGNS**

Grade 4/6 murmur, was grade 2, 3 months ago. Treated for HW + in Sept 2025 when rescued.

Meds: Gabapentin premed.

Abnormal PE/Chem/CBC/UA Results: HW antigen +, microfilaria (-)

**ULTRASONOGRAPHIC EXAMINATION OF THE HEART**

CANINE CARDIAC PARAMETERS	MR VMAX (m/s)	TR VMAX (m/s)	LA/AO (M-Mode)	LA/AO (Heart Base; Swe)	FS (%)	EF (%)	EPSS (cm)
NORMAL PARAMETER	4.5-5.5	<2.7	1.3	Up to 1.6	28-40	40-100	<0.6
PATIENT	5.4	-	-	1.4	47	80	0.2
CANINE CARDIAC PARAMETERS	HR (BPM)	AV VMAX (m/s)	PV MAX (m/s)	BODY WEIGHT	LAD LA MAX4 Chamber	LVIDd Avg; 2D and m-mode short axis (cm)	LVIDs Avg; 2D and m-mode short axis (cm)
NORMAL PARAMETER	50-100	0.7-1.7	0.7-1.6				
PATIENT	136	1.2	1.1	17.2 lbs.	2.6	2.6	-

**Cardiac Presentation**

The echocardiogram in this patient demonstrated normal **left atrial** size based on 2 different LA measurement methods. The cranial and caudal **mitral** valve leaflets presented mild thickening consistent with early to mild degenerative valvular changes. Doppler indicated moderate eccentric insufficiency (5.4 m/s). The **left ventricle** presented thicknesses with linear contour and was not dilated nor restricted. The **myocardium** presented normal echogenicity without subjective evidence of significant fibrotic or ischemic disease. **Contractility** of the ventricular walls was adequate and in normal range for this patient evidenced by the fractional shortening measurement and subjective evaluation of the different regions of the myocardium. The **left ventricular outflow** tract demonstrated normal laminar flow and subjective structural integrity. The **right atrium** and auricle revealed normal size, structure and content. No evidence of masses was noted or chamber overload. **Tricuspid** valvular assessment demonstrated adequate linear morphology. The **right ventricle** was of normal size (1/3 diameter of LV), chordae structure, myocardial echogenicity and thickness. **Pulmonic** tract assessment revealed normal valve structure, laminar flow, and diameter (approx.1:1 pa/ao ratio). No visible **pericardial** or free pleura fluid was noted. No echographically detectable evidence of cardiac / pericardial tumors was visible.



**PATIENT**

Curtis Rowan

**SPECIES**

Canine

**BREED**

Mixed

**SEX**

NM

**AGE**

4 years

**WEIGHT**

17.2 lbs.

**INTERPRETED BY**

R. McKenzie Daniel,  
 DVM, DABVP  
 (Canine and Feline)

**IMAGING PERFORMED BY**

Rebecca Hamilton

**HOSPITAL NAME**

American Animal  
 Hospital

**REFERRING VET**

Dr. Pascucci

**INVOICE**

10854

**DATE**

4/30/26

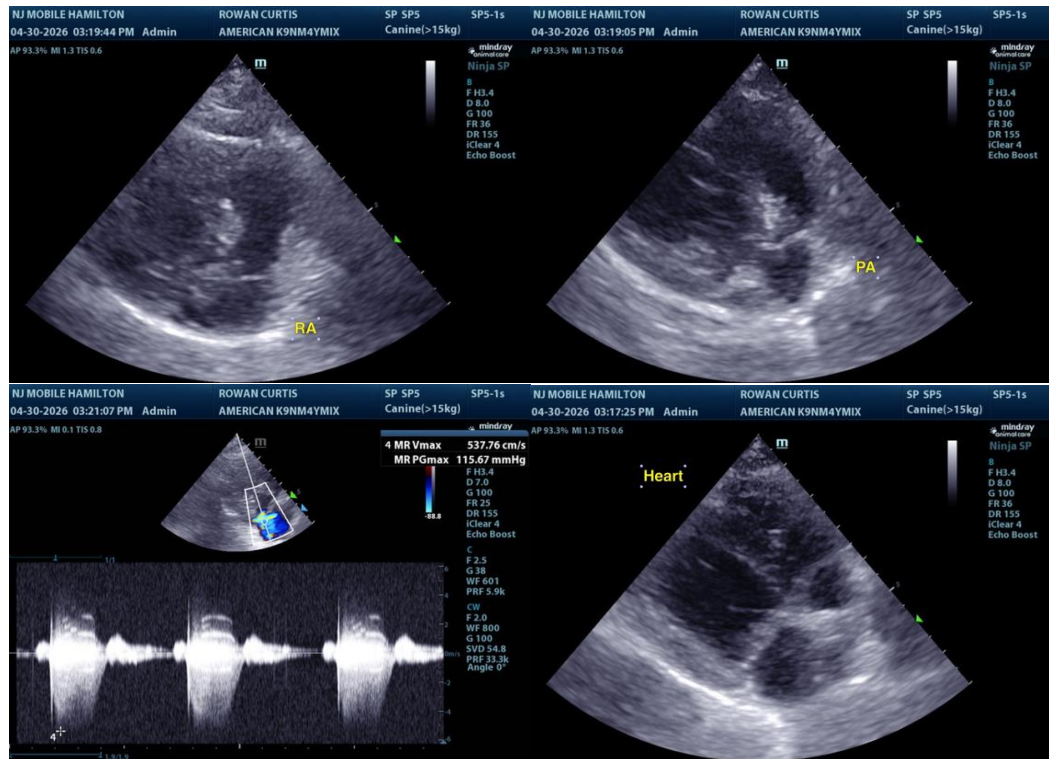
**ULTRASONOGRAPHIC FINDINGS**

- Chronic mitral valve disease (B1)

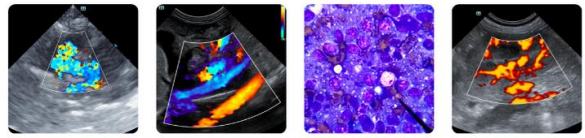
**INTERPRETATION OF THE FINDINGS & FURTHER RECOMMENDATIONS**

The cause of the murmur is chronic degenerative valvular changes with secondary eccentric mitral valve insufficiency. The lack of left atrial enlargement implies that the risk of complications secondary to mitral valve insufficiency is low at this time and, without current clinical signs, indicates that medical therapy is not required. There were no obvious visualized heartworms in the main pulmonary artery.

Prognosis is considered variable and sonographic monitoring is recommended. Recheck echocardiogram is suggested in 6-12 months, sooner if clinical signs arise. Anesthetic risk is considered mild. If required, the following protocol is suggested. Suggested anesthetic protocol may include opioid or Benzodiazepine pre-med, induction with Propofol or Alfaxalone, and appropriate gas anesthesia with avoidance of alpha 2 agonists.



The information and recommendations provided are based on the images presented by the referring veterinarian/sonographer. No evaluation can be communicated regarding pathology that was not visible in the image/video clips provided.



**PATIENT**

Curtis Rowan

**SPECIES**

Canine

**BREED**

Mixed

**SEX**

NM

**AGE**

4 years

**WEIGHT**

17.2 lbs.

**INTERPRETED BY**

R. McKenzie Daniel,  
DVM, DABVP  
(Canine and Feline)

**IMAGING  
PERFORMED BY**

Rebecca Hamilton

**HOSPITAL NAME**

American Animal  
Hospital

**REFERRING VET**

Dr. Pascucci

**INVOICE**

10854

**DATE**

4/30/26

Thank you for this referral. If the clinical or image interpretation does not parallel your findings or if I can be of any further assistance, please contact me.

**R. McKenzie Daniel, DVM, DABVP (Canine / Feline Practice)**  
[info@sonopath.com](mailto:info@sonopath.com)