



**PATIENT**

Bambi James

**SPECIES**

Canine

**BREED**

Mix

**SEX**

FS

**AGE**

8y

**WEIGHT**

35 kgs

**INTERPRETED BY**

R. McKenzie Daniel,  
 DVM, DABVP  
 (Canine and Feline)

**IMAGING PERFORMED BY**

Vincent Ravancho, CVT

**HOSPITAL NAME**

Marsh Hospital for  
 Animals

**REFERRING VET**

Dr. Ilardi

**INVOICE**

10855

**DATE**

4/30/26

**PRESENTING CLINICAL SIGNS**

Elevated Liver values. Current medications - Deramaxx (short course)  
 Abnormal PE/Chem/CBC/UA Results: ALT 300, Alk P 668, TP 7.7, USG 1.038

**ULTRASONOGRAPHIC EXAMINATION OF THE HEART & ABDOMEN**

CANINE CARDIAC PARAMETERS	MR VMAX (m/s)	TR VMAX (m/s)	LA/AO (M-Mode)	LA/AO (Heart Base; Swe)	FS (%)	EF (%)	EPSS (cm)
NORMAL PARAMETER	4.5-5.5	<2.7	1.3	Up to 1.6	28-40	40-100	<0.6
PATIENT	-	-	-	1.38	35	68	0.25
CANINE CARDIAC PARAMETERS	HR (BPM)	AV VMAX (m/s)	PV MAX (m/s)	BODY WEIGHT	LAD LA MAX4 Chamber	LVIDd Avg; 2D and m-mode short axis (cm)	LVIDs Avg; 2D and m-mode short axis (cm)
NORMAL PARAMETER	50-100	0.7-1.7	0.7-1.6				
PATIENT	149	1.1	1.1	35 kg	3.6	3.4	-

**Cardiac Presentation**

The echocardiogram in this patient demonstrated normal **left atrial** size based on 2 separate methods of LA evaluation. The cranial and caudal **mitral** valve leaflets presented normal linear structure, extension in systole, and union in diastole with normal kinesis. The **left ventricle** presented thicknesses with linear contour and was not dilated nor restricted. The **myocardium** presented normal echogenicity without subjective evidence of significant fibrotic or ischemic disease. **Contractility** of the ventricular walls was adequate and in normal range for this patient evidenced by the fractional shortening measurement and subjective evaluation of the different regions of the myocardium. The **left ventricular outflow** tract demonstrated normal laminar flow and subjective structural integrity. The **right atrium** and auricle revealed normal size, structure and content. No evidence of masses was noted. **Tricuspid** valvular assessment demonstrated adequate linear morphology and kinesis. The **right ventricle** was of normal size (1/3 diameter of LV), chordae structure, myocardial echogenicity and thickness. **Pulmonary outflow** tract assessment revealed normal valve structure, laminar flow, and diameter (approx. 1:1 pa/ao ratio). No visible **pericardial** or free pleura fluid was noted. The cranial **mediastinum and pericardial and extra-cardiac regions** were free of masses in the visible window.

**Urinary System**

The urinary bladder, trigone, cystourethral junction, and visible pelvic urethra to a depth of 3.0 cm exhibited normal thickness and tone. Anechoic urine was present in the lumen with no uroliths or sediment. No mineral or calculi. The ureteral papillae were normal. The ureters were not visible which is normal. No evidence of inflammatory or neoplastic changes were noted.

The area of the iliac trifurcation was free of pathology.



**PATIENT**

Bambi James

**SPECIES**

Canine

**BREED**

Mix

**SEX**

FS

**AGE**

8y

**WEIGHT**

35 kgs

**INTERPRETED BY**

R. McKenzie Daniel,  
 DVM, DABVP  
 (Canine and Feline)

**IMAGING PERFORMED BY**

Vincent Ravancho, CVT

**HOSPITAL NAME**

Marsh Hospital for  
 Animals

**REFERRING VET**

Dr. Ilardi

**INVOICE**

10855

**DATE**

4/30/26

Normal size and margination were present in the kidneys. A normal 1:3 cortex / medulla ratio and normal corticomedullary definition were maintained. The echogenicity of the cortex was similar to or slightly less than normal liver parenchyma while the medulla echogenicity was hypoechoic to the cortex with no evidence of pelvic dilation. The left kidney measured 6.7 cm in length. The right kidney measured 6.7 cm in length.

***Adrenal Glands***

The left adrenal gland was uniform in size and contour with a uniformly hypoechoic parenchyma. The left adrenal gland measured 0.58 cm width at the caudal pole. The right adrenal gland was uniform in size and contour with a uniformly hypoechoic parenchyma. The right adrenal gland measured 0.58 cm width at the caudal pole.

***Spleen***

The spleen was normal in size and contour with primarily homogeneous parenchyma and mild hyperechoic perihilar parenchyma, consistent with benign / age-related splenic changes.

***Liver/ Gallbladder***

The liver was subjectively normal in size, contour, and vascular volume. The liver parenchyma was nonuniform and hypoechoic to the spleen with a mild coarse echotexture and subjective mild parenchymal remodeling. The hepatic and portal vasculature were normal in appearance without signs of congestion. The gallbladder was non-distended in size with thin walls and primarily anechoic luminal content. The cystic and common bile ducts were normal.

***Gastrointestinal***

The stomach presented intact wall layering with a normal wall layer ratio. The lumen of the stomach contained mild, nonshadowing ingesta, consistent with food/chyme without signs of obstruction or foreign material.

The small intestine presented intact wall layering with 1:3 muscularis/mucosa ratio. The lumen of the small intestine was empty with no signs of ileus, obstruction, or foreign material.

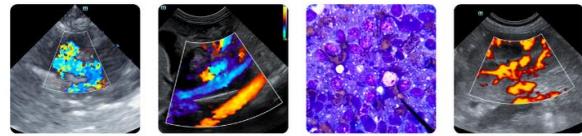
Normal visible colon wall layers were present with formed feces in lumen.

***Pancreas***

The parenchyma of the left limb, body, and right limb of the pancreas presented isoechoic to the adjacent omental fat. A normal curvilinear capsule contour of the pancreas was present. The visible pancreatic duct was normal. No signs of active inflammation or neoplastic disease were evident.

***Free Abdomen***

No overt lymphadenopathy or peritoneal effusion was present.



**PATIENT**

Bambi James

**SPECIES**

Canine

**BREED**

Mix

**SEX**

FS

**AGE**

8y

**WEIGHT**

35 kgs

**INTERPRETED BY**

R. McKenzie Daniel,  
DVM, DABVP  
(Canine and Feline)

**IMAGING PERFORMED BY**

Vincent Ravancho, CVT

**HOSPITAL NAME**

Marsh Hospital for  
Animals

**REFERRING VET**

Dr. Ilardi

**INVOICE**

10855

**DATE**

4/30/26

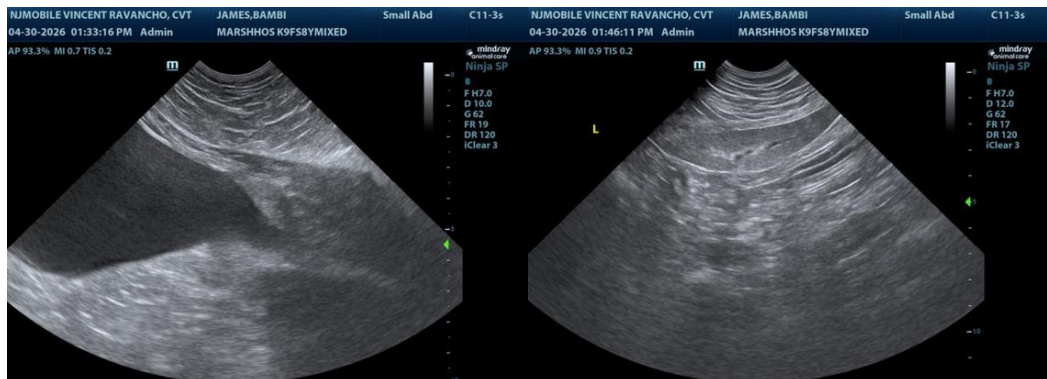
**ULTRASONOGRAPHIC FINDINGS**

- Normal cardiac structure / function
- Chronic benign hepatopathy
- Sonographically normal gallbladder
- Normal adrenal glands

**INTERPRETATION OF THE FINDINGS & FURTHER RECOMMENDATIONS**

The appearance of the liver was nonspecific but most consistent with benign hepatopathy. Considerations for the liver may include benign vacuolar / cholestatic hepatopathy, inflammatory/infectious/immune mediated disease, hyperplasia, hematopoiesis, toxic hepatopathy (i.e. copper), other with neoplasia thought less likely. No obvious evidence of intrahepatic or extrahepatic macroscopic shunt or adrenal disease as a contributing factor.

Ultrasound guided FNA of the liver using a 25-gauge needle and assuming normal coagulation parameters would be warranted for screening cytology. Hepatosupportive medications such as Denamarin or Vitamin E as well as Ursodiol due to its antioxidant and immunomodulatory effects within the liver would be warranted, although these medications may not result in decreased hepatic enzyme levels. Leptospirosis titers / PCR may be considered if clinically indicated. Core or surgical biopsy likely required for definitive diagnosis.





**PATIENT**

Bambi James

**SPECIES**

Canine

**BREED**

Mix

**SEX**

FS

**AGE**

8y

**WEIGHT**

35 kgs

**INTERPRETED BY**

R. McKenzie Daniel,  
 DVM, DABVP  
 (Canine and Feline)

**IMAGING PERFORMED BY**

Vincent Ravancho, CVT

**HOSPITAL NAME**

Marsh Hospital for  
 Animals

**REFERRING VET**

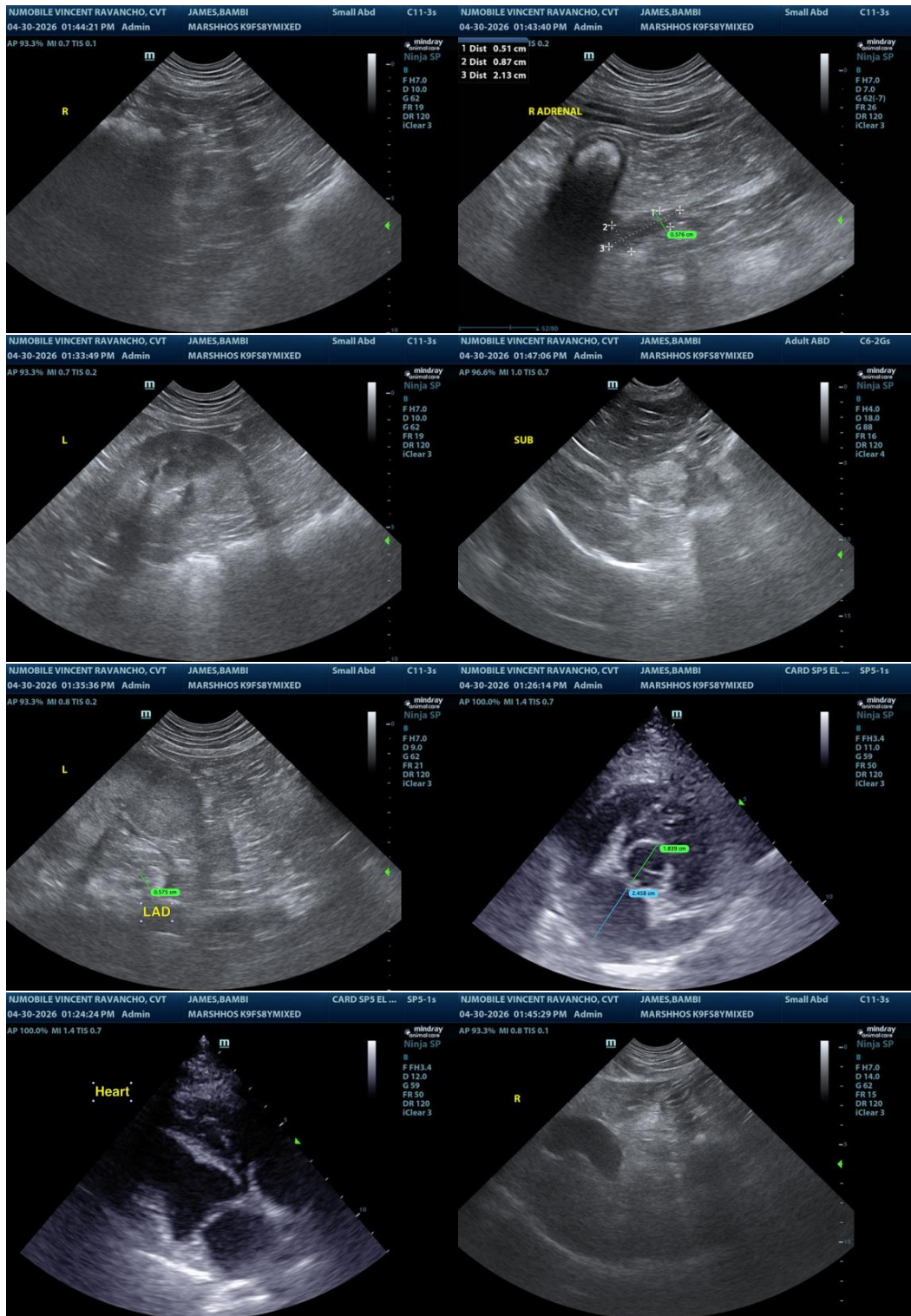
Dr. Ilardi

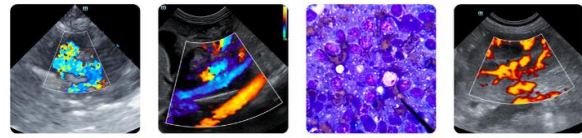
**INVOICE**

10855

**DATE**

4/30/26





**PATIENT**

Bambi James

The information and recommendations provided are based on the images presented by the referring veterinarian/sonographer. No evaluation can be communicated regarding pathology that was not visible in the image/video clips provided.

**SPECIES**

Canine

Thank you for this referral. If the clinical or image interpretation does not parallel your findings or if I can be of any further assistance, please contact me.

**BREED**

Mix

R. McKenzie Daniel, DVM, DABVP (Canine/Feline Practice)  
[info@sonopath.com](mailto:info@sonopath.com)

**SEX**

FS

**AGE**

8y

**WEIGHT**

35 kgs

**INTERPRETED BY**

R. McKenzie Daniel,  
DVM, DABVP  
(Canine and Feline)

**IMAGING PERFORMED BY**

Vincent Ravancho, CVT

**HOSPITAL NAME**

Marsh Hospital for  
Animals

**REFERRING VET**

Dr. Ilardi

**INVOICE**

10855

**DATE**

4/30/26