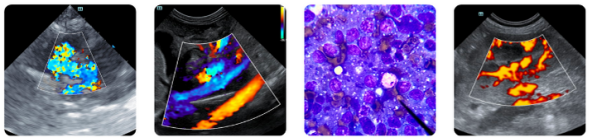

PATIENT
Amarillo Strickler

SPECIES
Canine

BREED
Great Pyrenees Mix

SEX
Male Neutered

AGE
9y

WEIGHT
89.7 lbs

INTERPRETED BY
R. McKenzie Daniel, DVM, DABVP (Canine and Feline)

IMAGING PERFORMED BY
Mary Pearce

HOSPITAL NAME
Chambersburg AH

REFERRING VET
Mary Pearce

INVOICE
13372

DATE
4/3/26

PRESENTING CLINICAL SIGNS

History: Presented for wellness exam 3/6/26, p had been doing well at home. Only concern was that he suffers from severe arthritis, which makes it difficult for him to get in and out of the car. Managed with carprofen, which is taken as needed for arthritis, though he has not been on it for an extended period. e/d/u/d normally, no c/s/v/d. Abdominal ultrasound vs. LDDST vs. denamarin trial recommended due to elevated ALP on routine bloodwork, with o electing for ultrasound.

Abnormal PE/Chem/CBC/UA Results: PE findings were normal other than a suspected sebaceous cyst on top of the head. 3/7/26 BW: CBC unremarkable, HCT 47%, WBC 8.6, lymph 0.929 (L), PLT 494 (H). Chloride 106 (L), TP 8.3 (H), Alb 4.3 (H), glob 4.0, Cholesterol 364 (H), ALP 854 (H), other liver/biliary values normal - ALT 54, AST 36, GGT <1, tbili 0.3. Tt4 1.4. 4Dx negative x4.

ULTRASONOGRAPHIC EXAMINATION OF THE ABDOMEN

Urinary System

The urinary bladder, trigone, cystourethral junction, and visible pelvic urethra exhibited normal thickness and tone. Anechoic urine was present in the lumen with no uroliths or sediment. The ureteral papillae were normal. The ureters were not visible which is normal. No evidence of inflammatory or neoplastic changes were noted.

The residual prostate presented sonographically normal measuring ~3.0 cm.

Normal size and margination was present in the kidneys. A normal 1:3 cortex / medulla ratio and normal corticomedullary definition were maintained. The echogenicity of the cortex was similar to or slightly less than normal liver parenchyma while the medulla echogenicity was hypoechoic to the cortex with no evidence of pelvic dilation. The left kidney measured 6.6 cm in length. The right kidney measured 6.4 cm in length.

Adrenal Glands

The left and right adrenal glands were overtly normal in size, position and shape with indistinct visualization. No obvious pathology present. The left adrenal gland subjectively measured 0.65 cm width at the caudal pole. The right adrenal gland subjectively measured 0.70 cm width at the caudal pole.

Spleen

The spleen exhibited a finely textured and homogenous parenchyma which was hyperechoic to the liver and renal cortical parenchyma. The capsule was smooth and regular without apparent expansion. The splenic vasculature at the hilus was normal in volume with no evidence of congestion or thrombosis. Acute to chronic inflammatory, neoplastic, or benign parenchyma changes were not noted.

Liver

The liver was subjectively normal in size with symmetrical contour and normal vascular volume. Primarily homogeneous parenchyma exhibiting mild coarse echotexture. The hepatic and portal vasculature were normal in appearance without signs of congestion. Intermittent, discrete, hypoechoic to non-homogeneous intraparenchymal nodules with an example measuring 2.2 cm in diameter. The

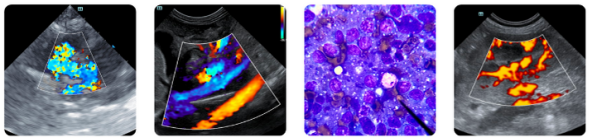

PATIENT
Amarillo Strickler

SPECIES
Canine

BREED
Great Pyrenees Mix

SEX
Male Neutered

AGE
9y

WEIGHT
89.7 lbs

INTERPRETED BY
R. McKenzie Daniel, DVM, DABVP (Canine and Feline)

IMAGING PERFORMED BY
Mary Pearce

HOSPITAL NAME
Chambersburg AH

REFERRING VET
Mary Pearce

INVOICE
13372

DATE
4/3/26

gallbladder was non distended in size with mild, non-organized, echogenic, nonmineralized biliary sludge. The cystic duct and common bile ducts were normal without evidence of dilation.

Gastrointestinal

The stomach presented intact wall layering with a normal wall layer ratio. The lumen of the stomach was empty with no signs of ileus, obstruction or foreign material.

The small intestine presented intact wall layering with 1:3 muscularis/mucosa ratio. The lumen of the small intestine was empty with no signs of ileus, obstruction or foreign material.

Normal visible colon wall layers were present with apparent formed feces in lumen.

Pancreas

The parenchyma of the left limb, body and right limb of the pancreas presented isoechoic to the adjacent omental fat. A normal curvilinear capsule contour of the pancreas was present. The visible pancreatic duct was normal. No signs of active inflammation or neoplastic disease was evident.

Free Abdomen

No overt lymphadenopathy or peritoneal effusion was present.

ULTRASONOGRAPHIC FINDINGS

- Discrete to nonspecific liver nodules
- Non-organized gallbladder debris (non-mucocele)
- Overtly normal bilateral adrenal glands

INTERPRETATION OF THE FINDINGS & FURTHER RECOMMENDATIONS

The liver nodules are nonspecific with considerations including nodular hyperplasia, small granulomas, hematopoiesis or other benign etiology. Emerging hepatic neoplastic nodules thought less likely yet not definitively excluded. Overall, vacuolar or non-obstructive cholestatic hepatopathy in conjunction with elevated ALP suspected. Inflammatory hepatic disease thought less likely. Screening hepatic parenchyma FNA cytology, assuming normal clotting status warranted for further clarification. Although, FNA access to hepatic nodules given depth in conjunction with patient size appears precluded. No evidence of adrenal pathology as a contributing factor. Serial monitoring of the hepatic nodules for evidence of progression would be reasonable. If evidence of nodular progression, hepatic biopsies would be indicated, Hepato-supportive medications including Denamarin and Ursodiol may prove beneficial.

SonoPath

FOSTERING THE ART OF VETERINARY MEDICINE™

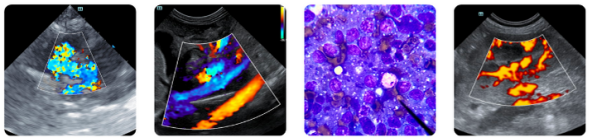

Clinical Sonography & Telecytology

Educational Teleconsultation Services™

SonoPath.com *info@sonopath.com* *1.800.838.4268*

PATIENT

Amarillo Strickler

SPECIES

Canine

BREED

Great Pyrenees Mix

SEX

Male Neutered

AGE

9y

WEIGHT

89.7 lbs

INTERPRETED BY

R. McKenzie Daniel, DVM, DABVP (Canine and Feline)

IMAGING PERFORMED BY

Mary Pearce

HOSPITAL NAME

Chambersburg AH

REFERRING VET

Mary Pearce

INVOICE

13372

DATE

4/3/26

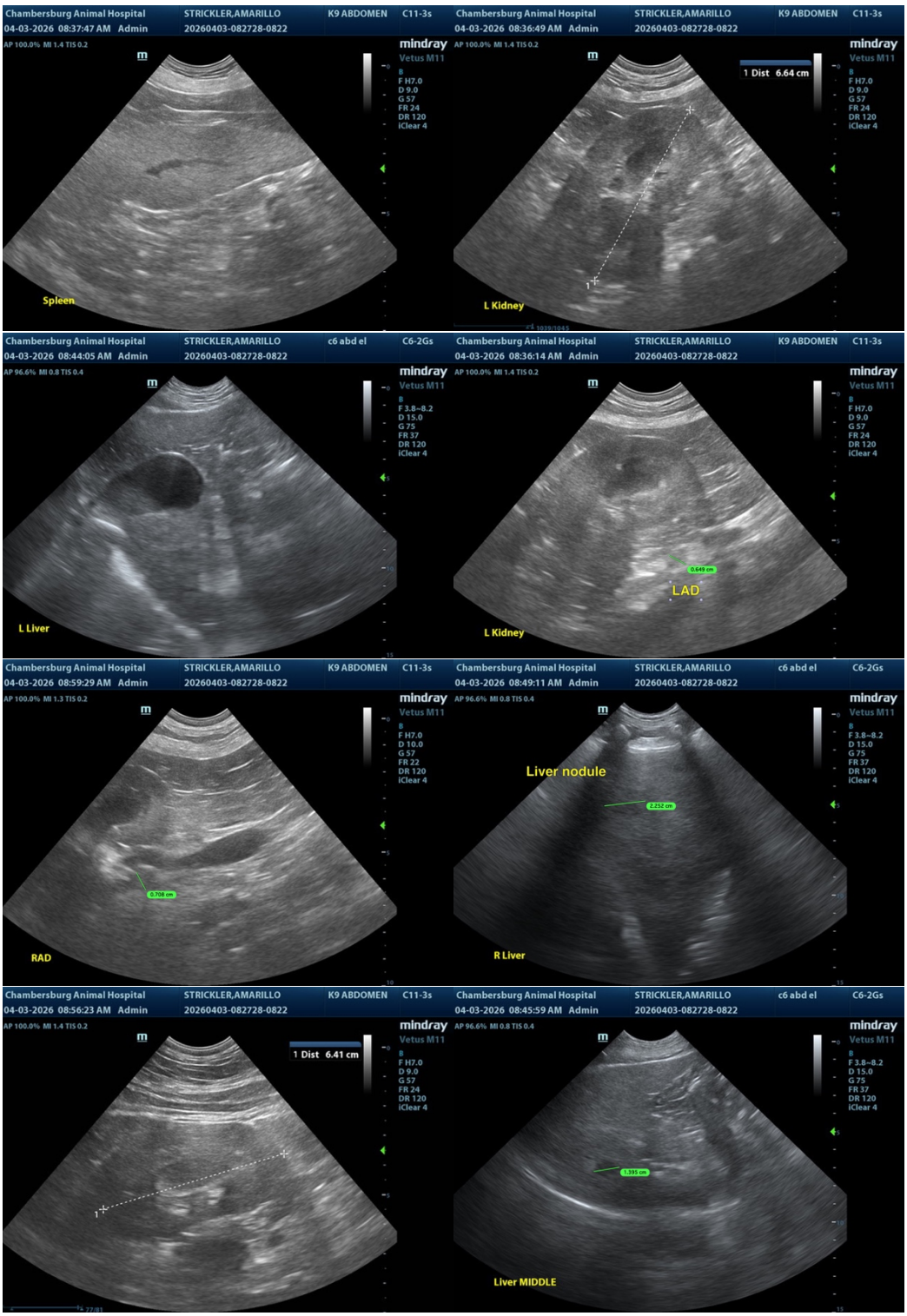

SonoPath
FOSTERING THE ART OF VETERINARY MEDICINE™

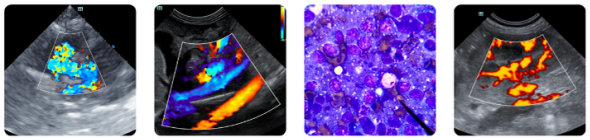

Clinical Sonography & Telecytology
Educational Teleconsultation Services™

SonoPath.com *info@sonopath.com* *1.800.838.4268*

PATIENT

Amarillo Strickler

SPECIES

Canine

BREED

Great Pyrenees Mix

SEX

Male Neutered

AGE

9y

WEIGHT

89.7 lbs

INTERPRETED BY

R. McKenzie Daniel, DVM, DABVP (Canine and Feline)

IMAGING PERFORMED BY

Mary Pearce

HOSPITAL NAME

Chambersburg AH

REFERRING VET

Mary Pearce

INVOICE

13372

DATE

4/3/26

The information and recommendations provided are based on the images presented by the referring veterinarian/sonographer. No evaluation can be communicated regarding pathology that was not visible in the image/video clips provided.

Thank you for this referral. If the clinical or image interpretation does not parallel your findings or if I can be of any further assistance, please contact me.

R. McKenzie Daniel, DVM, DABVP (Canine / Feline Practice)

info@sonopath.com