



PATIENT PRESENTING CLINICAL SIGNS

Hanna Cosgrove PU/PD and worsening urinary incontinence despite Incurin and Proin. Chronic mild elevation in ALP. Normal appetite and energy level. No vomiting or diarrhea.

SPECIES Abnormal PE/Chem/CBC/UA Results: ABNORMAL Laboratory Findings ALP 259. USG 1.016
Canine Current Medications Incurin, Proin Radiographic Findings None

BREED ULTRASONOGRAPHIC EXAMINATION OF THE ABDOMEN

Labrador Retriever **Urinary System**

SEX The urinary bladder, trigone, cystourethral junction, and visible pelvic urethra to a depth of 5 cm exhibited normal thickness and tone. Anechoic urine was present in the lumen with no uroliths or sediment. The ureteral papillae were normal. The ureters were not visible which is normal. No evidence of inflammatory or neoplastic changes were noted.
FS

AGE Normal size and margination were present in the kidneys. A normal 1:3 cortex / medulla ratio was maintained. The medulla and cortices were uniform in texture with some increased echogenicity and mild loss of corticomedullary symmetry and definition expected for the age of the patient. No evidence of pelvic dilation was present. The left kidney measured 6.2 cm in length. The right kidney measured 5.5 cm in length.

WEIGHT 63.7lb The area of the aortic trifurcation was free of pathology.

INTERPRETED BY Adrenal Glands

R. McKenzie Daniel, DVM, DABVP (Canine and Feline) The bilateral adrenal glands were mildly enlarged in size. Mild parenchyma heterogeneity and mild capsule asymmetry was present without suspicion for overt neoplasia. The left adrenal gland measured 0.86 cm width in the cranial pole and 1.25 cm width in the caudal pole. The right adrenal gland measured 1.1 cm width in the caudal pole.

IMAGING PERFORMED BY Spleen

Sara Hansen The spleen exhibited a finely textured and homogenous parenchyma which was hyperechoic to the liver and renal cortical parenchyma. The capsule was smooth and regular without apparent expansion. The splenic vasculature at the hilus was normal in volume with no evidence of congestion or thrombosis. Acute to chronic inflammatory, neoplastic, or benign parenchyma changes were not noted.

HOSPITAL NAME Liver/Gallbladder

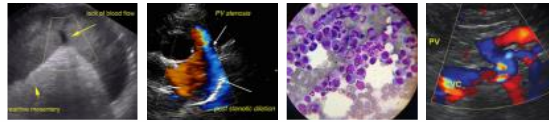
West Eugene AH The liver presented borderline enlarged in size. The parenchyma of the liver was subjectively normal in echogenicity compared to the spleen and renal cortices. The liver parenchyma was uniform with a mildly coarse echotexture. The capsule of the liver was symmetrically rounded to mildly swollen in margination. The hepatic and portal vasculature were normal in appearance without signs of congestion. The gallbladder was non-distended in size with primarily anechoic luminal content. The cystic and common bile ducts were normal.

REFERRING VET Dr. Powers

INVOICE 13393ag

DATE Gastrointestinal

04/03/2023



PATIENT	The stomach presented intact wall layering with a normal wall layer ratio. The lumen of the stomach contained mild non-shadowing ingesta suggestive of food with no signs of ileus, obstruction or foreign material.
Hanna Cosgrove	
SPECIES	The small intestine presented intact wall layering with 1:3 muscularis/mucosa ratio. The lumen of the small intestine was empty with no signs of ileus, obstruction or foreign material.
Canine	Normal visible colon wall layers were present with apparent formed feces in lumen.
BREED	Pancreas
Labrador Retriever	The parenchyma of the left limb, body and right limb of the pancreas presented isoechoic to the adjacent omental fat. A normal curvilinear capsule contour of the pancreas was present. The visible pancreatic duct was normal. No signs of active inflammation or neoplastic disease was evident.
SEX	Free Abdomen
FS	No omental masses, overt lymphadenopathy or peritoneal effusion was present.
AGE	Mid abdominal primarily peri intestinal mild uniform hyperechoic omentum was present.
11yr	
WEIGHT	ULTRASONOGRAPHIC FINDINGS
63.7lb	<ul style="list-style-type: none">• Sonographically unremarkable urinary bladder and visible proximal urethra.• Mild chronic renal changes.• Mildly enlarged non-homogenous adrenal glands.• Benign hepatopathy, sonographically unremarkable gallbladder.• Structurally normal GI tract with gastric ingesta.• Non-specific regional mid abdominal hyperechoic omentum.
INTERPRETED BY	INTERPRETATION OF THE FINDINGS & FURTHER RECOMMENDATIONS
R. McKenzie Daniel, DVM, DABVP (Canine and Feline)	Although no evidence of reported polyphagia, screening UCCR or a full adrenal workup with LDDST is warranted given reported PU/PD and worsening incontinence. A screening BP is advised to assess for evidence of hypertension which may allude to unlikely emerging adrenal neoplastic criteria i.e., pheochromocytoma.
IMAGING PERFORMED BY	A full urinary workup to include urine C/S and protein: creatinine ratio on sterile urine sample is recommended.
Sara Hansen	
HOSPITAL NAME	The mid abdominal peri intestinal hyperechoic omentum is non-specific. Monitoring for evidence of GI signs which may allude to mild peri intestinal reactive omentum secondary to possible emerging enteropathy is suggested.
West Eugene AH	
REFERRING VET	
Dr. Powers	
INVOICE	
13393ag	
DATE	
04/03/2023	



PATIENT

Hanna Cosgrove

SPECIES

Canine

BREED

Labrador Retriever

SEX

FS

AGE

11yr

WEIGHT

63.7lb

INTERPRETED BY

R. McKenzie Daniel,
DVM, DABVP
(Canine and Feline)

IMAGING PERFORMED BY

Sara Hansen

HOSPITAL NAME

West Eugene AH

REFERRING VET

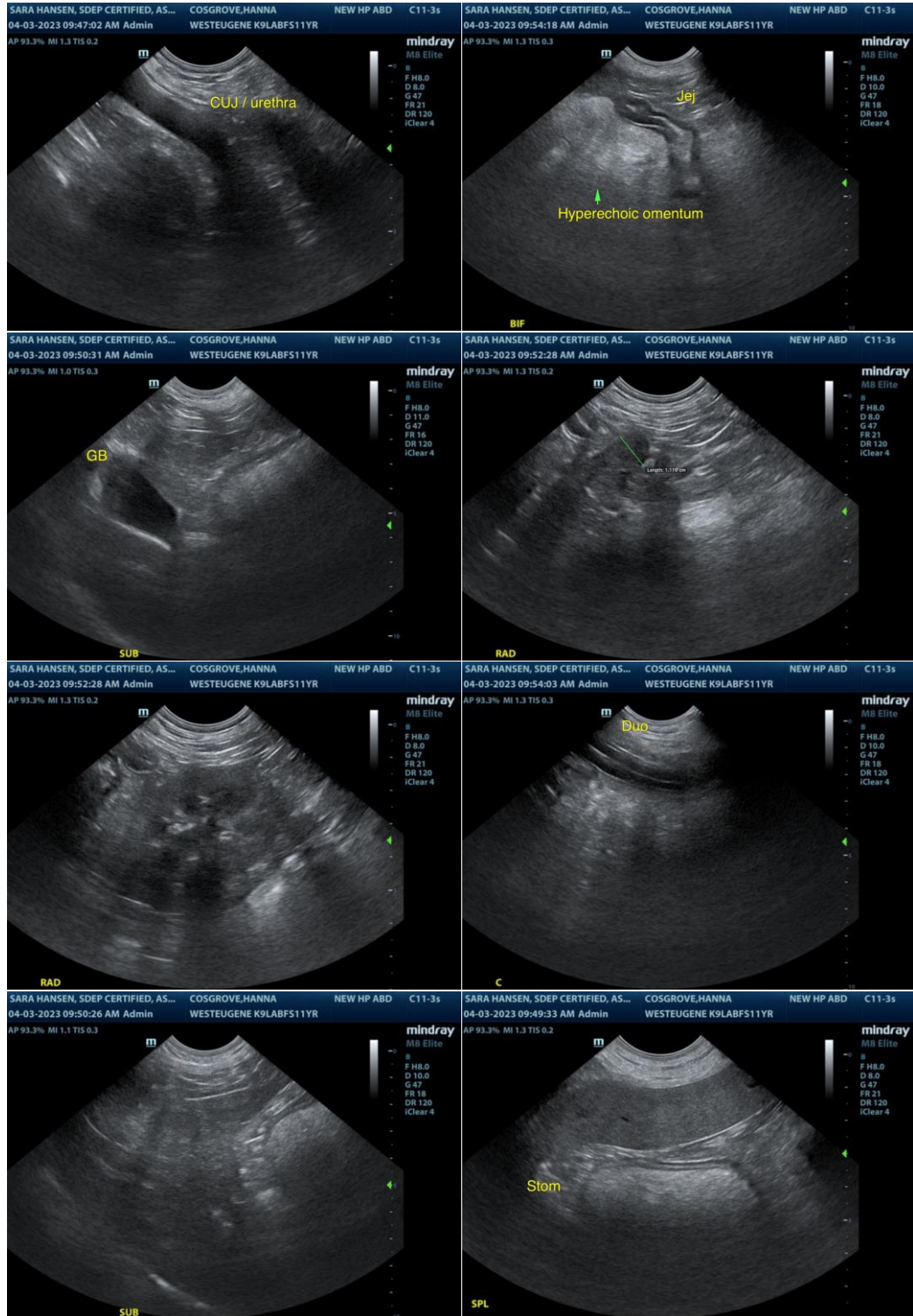
Dr. Powers

INVOICE

13393ag

DATE

04/03/2023





PATIENT

Hanna Cosgrove

SPECIES

Canine

BREED

Labrador Retriever

SEX

FS

AGE

11yr

WEIGHT

63.7lb

INTERPRETED BY

R. McKenzie Daniel,
DVM, DABVP
(Canine and Feline)

IMAGING PERFORMED BY

Sara Hansen

HOSPITAL NAME

West Eugene AH

REFERRING VET

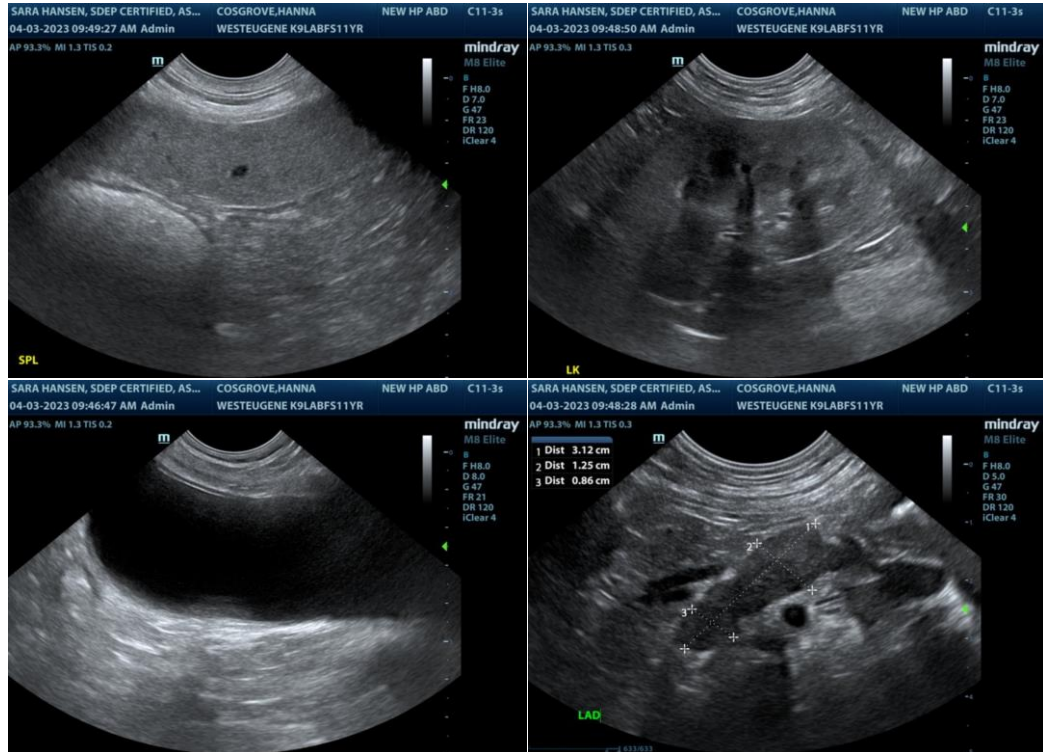
Dr. Powers

INVOICE

13393ag

DATE

04/03/2023



The information and recommendations provided are based on the images presented by the referring veterinarian/sonographer. No evaluation can be communicated regarding pathology that was not visible in the image/video clips provided.

Thank you for this referral. If the clinical or image interpretation does not parallel your findings or if I can be of any further assistance please contact me.

R. McKenzie Daniel, DVM, DABVP (Canine / Feline Practice)

info@SonoPath.com