



PATIENT	PRESENTING CLINICAL SIGNS
Cooper Stalick	- growth 2cm soft, deep SC mass on R flank - abundant mast cells, RBCs, adipocytes; presumptive dx = MCT
SPECIES	Current Medications diphenhydramine 100mg PO q12h
Canine	ULTRASONOGRAPHIC EXAMINATION OF THE ABDOMEN
BREED	<i>Urinary System</i>
Lab Mix	The urinary bladder, trigone, cystourethral junction, and visible pelvic urethra to a depth of 4 cm exhibited normal thickness and tone. Anechoic urine was present in the lumen with no uroliths or sediment. The ureteral papillae were normal. The ureters were not visible which is normal. No evidence of inflammatory or neoplastic changes were noted.
SEX	
MI	Normal size and margination were present in the kidneys. A normal 1:3 cortex / medulla ratio was maintained. The medulla and cortices were uniform in texture with some increased echogenicity and minor loss of corticomedullary symmetry and definition expected for the age of the patient. No evidence of pelvic dilation was present. The left kidney measured 7.4 cm in length. The right kidney measured 7.7 cm in length.
AGE	
9yr	
WEIGHT	The area of the aortic trifurcation was free of pathology.
92lb	The area of the iliac trifurcation was free of pathology including no evidence of medial, iliac or sublumbar lymphadenopathy.
INTERPRETED BY	The prostate was enlarged in size with intact, symmetrical capsule contour. The margins of the gland were intact and able to be differentiated from the surrounding tissue. The prostatic parenchyma was mildly echogenic to heteroechoic without parenchymal mineralization. The prostate measured 5.8 cm x 3.6 cm.
R. McKenzie Daniel, DVM, DABVP (Canine and Feline)	The bilateral testicles were free of pathology.
IMAGING PERFORMED BY	<i>Adrenal Glands</i>
Jenna Walsh CVT	A subtle non-disruptive, hyperechoic nodule was present in the cranial pole of the left adrenal gland with mild associated symmetrical capsule expansion. The nodule did not exhibit signs of mineralization or vascular invasion. The nodule measured 1.2 cm x 0.7 cm. Overall the left adrenal gland measured 3.2 cm in length x 0.75 cm caudal pole width.
HOSPITAL NAME	The right adrenal gland was uniform in size and contour with a uniformly hypoechoic parenchyma measured 0.79 cm width at the caudal pole and 3.0 cm length.
Reid Veterinary Hospital	
REFERRING VET	<i>Spleen</i>
Dr. Popowich	The spleen exhibited a finely textured and homogenous parenchyma which was hyperechoic to the liver and renal cortical parenchyma. The capsule was smooth and regular without apparent expansion. The splenic vasculature at the hilus was normal in volume with no evidence of congestion or thrombosis. Acute to chronic inflammatory, neoplastic, or benign parenchyma changes were not noted.
INVOICE	<i>Liver/Gallbladder</i>
13385ag	
DATE	
04/03/2023	



PATIENT

Cooper Stalick

The liver was subjectively normal in size, structure, and contour. The liver parenchyma was uniform and hypoechoic to the spleen with a mild coarse echotexture. The hepatic and portal vasculature were normal in appearance without signs of congestion. The gallbladder was non-distended in size with thin walls and primarily anechoic luminal content. The cystic and common bile ducts were normal.

SPECIES

Canine

Gastrointestinal

The stomach presented intact wall layering with a normal wall layer ratio. The lumen of the stomach was empty with no signs of ileus, obstruction or foreign material.

BREED

Lab Mix

The small intestine presented intact wall layering with 1:3 muscularis/mucosa ratio. The lumen of the small intestine was empty with no signs of ileus, obstruction or foreign material.

SEX

MI

Normal visible colon wall layers were present with apparent formed feces in lumen.

AGE

9yr

Pancreas

The parenchyma of the left limb, body and right limb of the pancreas presented isoechoic to the adjacent omental fat. A normal curvilinear capsule contour of the pancreas was present. The visible pancreatic duct was normal. No signs of active inflammation or neoplastic disease was evident.

WEIGHT

92lb

Free Abdomen

No omental masses, overt lymphadenopathy or peritoneal effusion was present.

INTERPRETED BY

R. McKenzie Daniel,
DVM, DABVP
(Canine and Feline)

ULTRASONOGRAPHIC FINDINGS

- Benign prostatic hyperplasia.
- Mild age related renal changes.
- Subtle non-disruptive left adrenal nodule-suspect adenoma.
- Normal liver/spleen.

IMAGING PERFORMED BY

Jenna Walsh CVT

INTERPRETATION OF THE FINDINGS & FURTHER RECOMMENDATIONS

Overall, there is no overt evidence of significant abdominal visceral pathology including no evidence of abdominal metastatic criteria. The possibility of emerging neoplastic left adrenal nodule i.e., pheochromocytoma cannot be definitively excluded yet is thought less likely.

HOSPITAL NAME

Reid Veterinary
Hospital

Sonographic monitoring of the left adrenal nodule and generalized abdominal cavity given presumptive diagnosis of cutaneous MCT is suggested. A screening BP is advised to assess for evidence of hypertension which may allude to emerging adrenal neoplastic criteria i.e., pheochromocytoma.

REFERRING VET

Dr. Popowich

INVOICE

13385ag

DATE

04/03/2023



PATIENT

Cooper Stalik

SPECIES

Canine

BREED

Lab Mix

SEX

MI

AGE

9yr

WEIGHT

92lb

INTERPRETED BY

R. McKenzie Daniel,
DVM, DABVP
(Canine and Feline)

IMAGING PERFORMED BY

Jenna Walsh CVT

HOSPITAL NAME

Reid Veterinary
Hospital

REFERRING VET

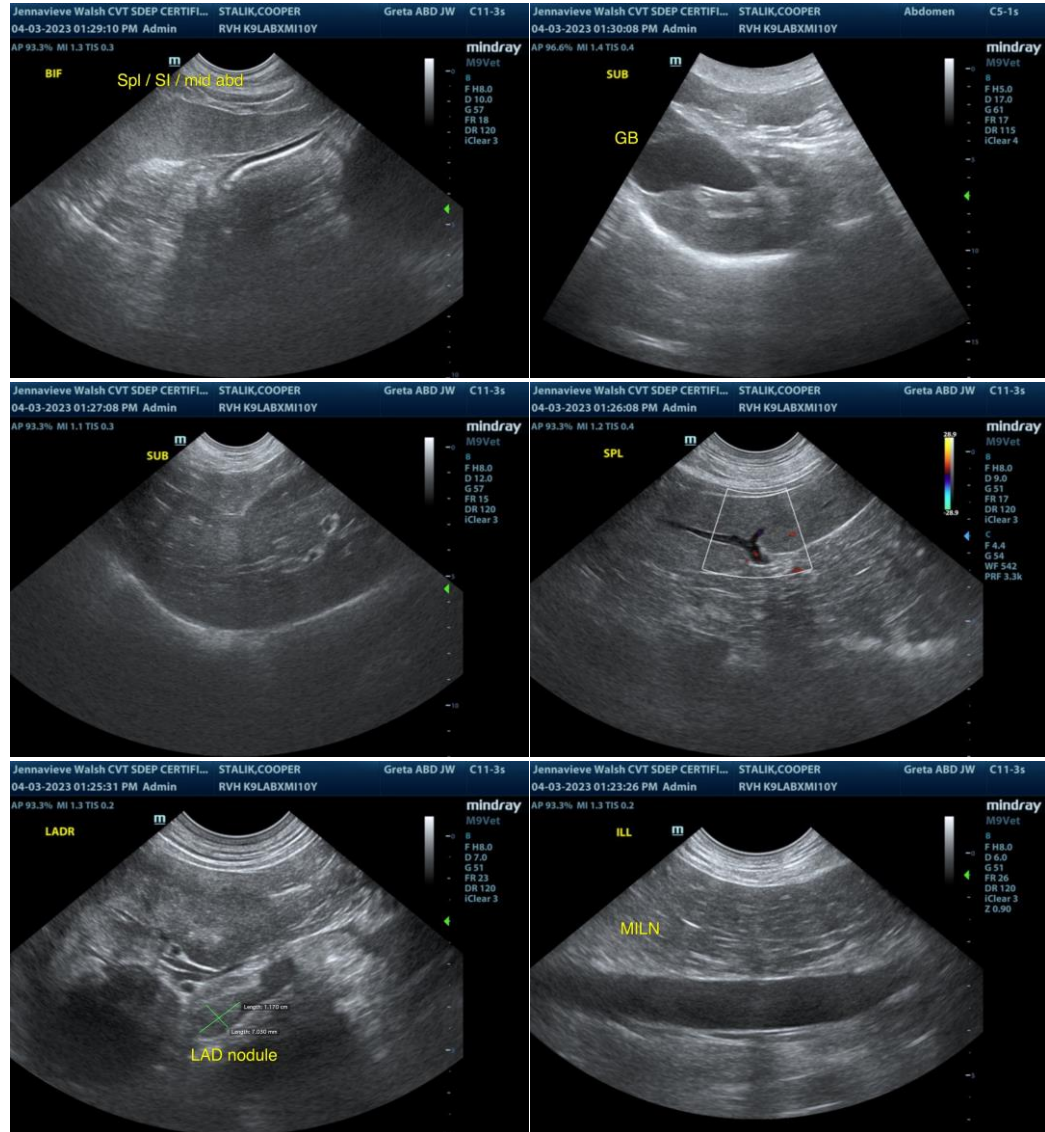
Dr. Popowich

INVOICE

13385ag

DATE

04/03/2023





PATIENT

Cooper Stalik

SPECIES

Canine

BREED

Lab Mix

SEX

MI

AGE

9yr

WEIGHT

92lb

INTERPRETED BY

R. McKenzie Daniel,
DVM, DABVP
(Canine and Feline)

IMAGING PERFORMED BY

Jenna Walsh CVT

HOSPITAL NAME

Reid Veterinary
Hospital

REFERRING VET

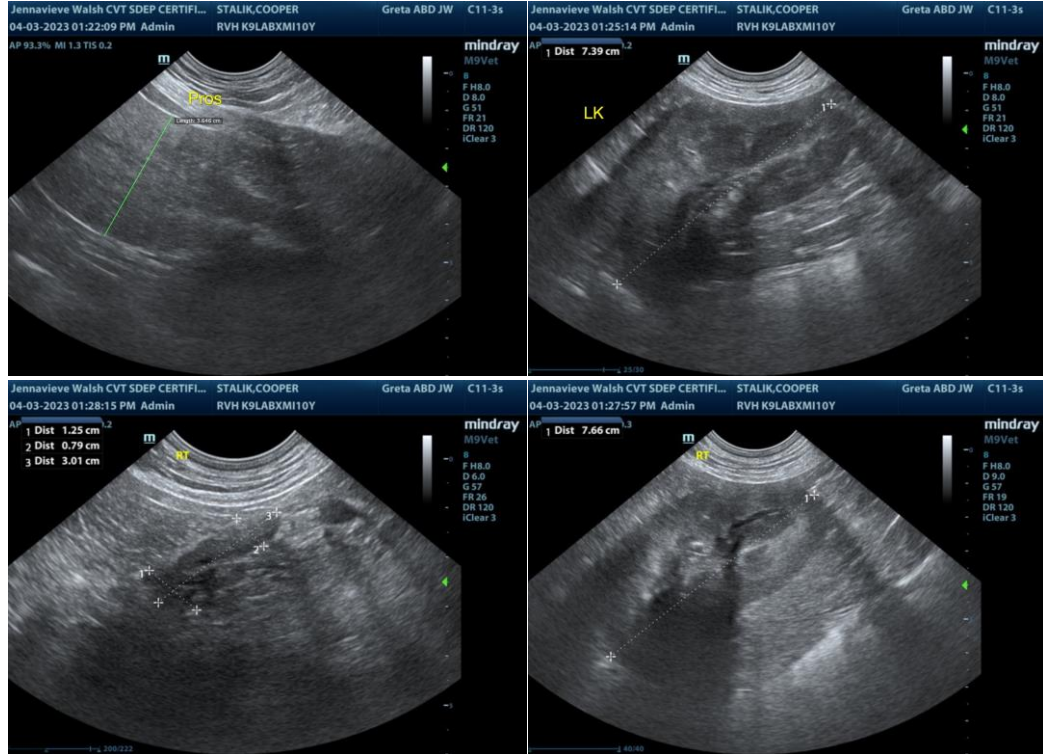
Dr. Popowich

INVOICE

13385ag

DATE

04/03/2023



The information and recommendations provided are based on the images presented by the referring veterinarian/sonographer. No evaluation can be communicated regarding pathology that was not visible in the image/video clips provided.

Thank you for this referral. If the clinical or image interpretation does not parallel your findings or if I can be of any further assistance please contact me.

R. McKenzie Daniel, DVM, DABVP (Canine / Feline Practice)

info@SonoPath.com