



## PATIENT

Walter Knight

## SPECIES

Canine

## BREED

Chow Chow

## SEX

Neutered Male

## AGE

12

## WEIGHT

58 pounds

## INTERPRETED BY

R. McKenzie Daniel,  
DVM, DABVP (Canine  
/ Feline Practice)

## IMAGING PERFORMED BY

Dr. Paul Kim

## HOSPITAL NAME

Ridgefield Park Animal  
Hospital

## REFERRING VET

Dr. Paul Kim

## INVOICE

15583

## DATE

04/29/26

## PRESENTING CLINICAL SIGNS

Diarrhea problem, underweight.

## ULTRASONOGRAPHIC EXAMINATION OF THE ABDOMEN

*Submitted study contained 16 still images and 7 videos for review.*

### **Urinary System**

The urinary bladder, trigone and cystourethral junction exhibited normal thickness and tone. Anechoic urine was present in the lumen with no uroliths or sediment. The ureteral papillae were normal. The ureters were not visible which is normal. No evidence of inflammatory or neoplastic change were noted.

The residual prostate and proximal urethra were not definitively visualized.

Normal size and margination was present in the kidneys. A normal 1:3 cortex / medulla ratio was maintained. The medulla and cortices were uniform in texture with some increased echogenicity and mild loss of corticomedullary symmetry and definition expected for the age of the patient. Subtle areas of medullary mineral were present. The left kidney measured 5.8 cm in length. The right kidney measured 6.0 cm in length.

### **Adrenal Glands**

The left adrenal gland was overtly normal in size, position and shape. The left adrenal gland measured 0.60 cm width in the caudal pole.

The right adrenal gland was not definitively visualized.

### **Spleen**

The spleen exhibited a finely textured and homogenous parenchyma which was hyperechoic to the liver and renal cortical parenchyma. The capsule was smooth and regular without apparent expansion. The splenic vasculature at the hilus was normal in volume with no evidence of congestion or thrombosis. Acute to chronic inflammatory, neoplastic, or benign parenchyma changes were not noted.

### **Liver & Gallbladder**

The liver revealed generalized hepatomegaly exhibiting asymmetrical contour and diffuse to marked nonhomogenous to indistinctly nodular parenchyma.

The gallbladder was non distended in size with mild nonorganized biliary sludge. The cystic duct and common bile ducts were normal without evidence of dilation.

### **Gastrointestinal**

The stomach and small intestine were not definitively visualized.

The visualized descending colon adjacent to the spleen exhibited subjective mildly thickened wall, non-distended size, and contained soft fecal matter consistent with patient history.

### **Pancreas**



## PATIENT

The pancreas was not definitively visualized.

Walter Knight

## Free Abdomen

## SPECIES

Canine

A large nonhomogenous indistinctly nodular mass was present in the subjective primarily mid to cranial abdomen, similar in echogenicity and appearance to the liver, measuring at least 8.0 cm in diameter but possibly larger as the entire mass would not fit into a single viewing window. No obvious peritoneal effusion.

## BREED

Chow Chow

## ULTRASONOGRAPHIC FINDINGS

## SEX

Neutered Male

- Indistinctly visualized colon exhibiting subjective colitis pattern.
- Large nonhomogenous nodular liver.
- Mid to cranial abdomen mass exhibiting similar sonographic appearance to the discernable liver.
- Mild chronic renal changes.
- Mild gallbladder debris (non-mucocele).

## AGE

12

## INTERPRETATION OF THE FINDINGS & FURTHER RECOMMENDATIONS

The abdominal mass is likely extending from un-visualized liver given similar sonographic appearance. A non-liver unspecified mass cannot be definitively excluded.

## WEIGHT

58 pounds

Further assessment may include (assuming normal clotting status) mass FNA cytology. Correlation with pending lab work is recommended. Gastrointestinal support which may include dietary trial, high colony count probiotic such as Provable and as needed gastroprotectants and empirical deworming may prove beneficial.

## INTERPRETED BY

R. McKenzie Daniel,  
DVM, DABVP (Canine  
/ Feline Practice)

## IMAGING PERFORMED BY

Dr. Paul Kim

## HOSPITAL NAME

Ridgefield Park Animal  
Hospital

## REFERRING VET

Dr. Paul Kim

## INVOICE

15583

## DATE

04/29/26



**PATIENT**

Walter Knight

**SPECIES**

Canine

**BREED**

Chow Chow

**SEX**

Neutered Male

**AGE**

12

**WEIGHT**

58 pounds

**INTERPRETED BY**

R. McKenzie Daniel,  
DVM, DABVP (Canine  
/ Feline Practice)

**IMAGING  
PERFORMED BY**

Dr. Paul Kim

**HOSPITAL NAME**

Ridgefield Park Animal  
Hospital

**REFERRING VET**

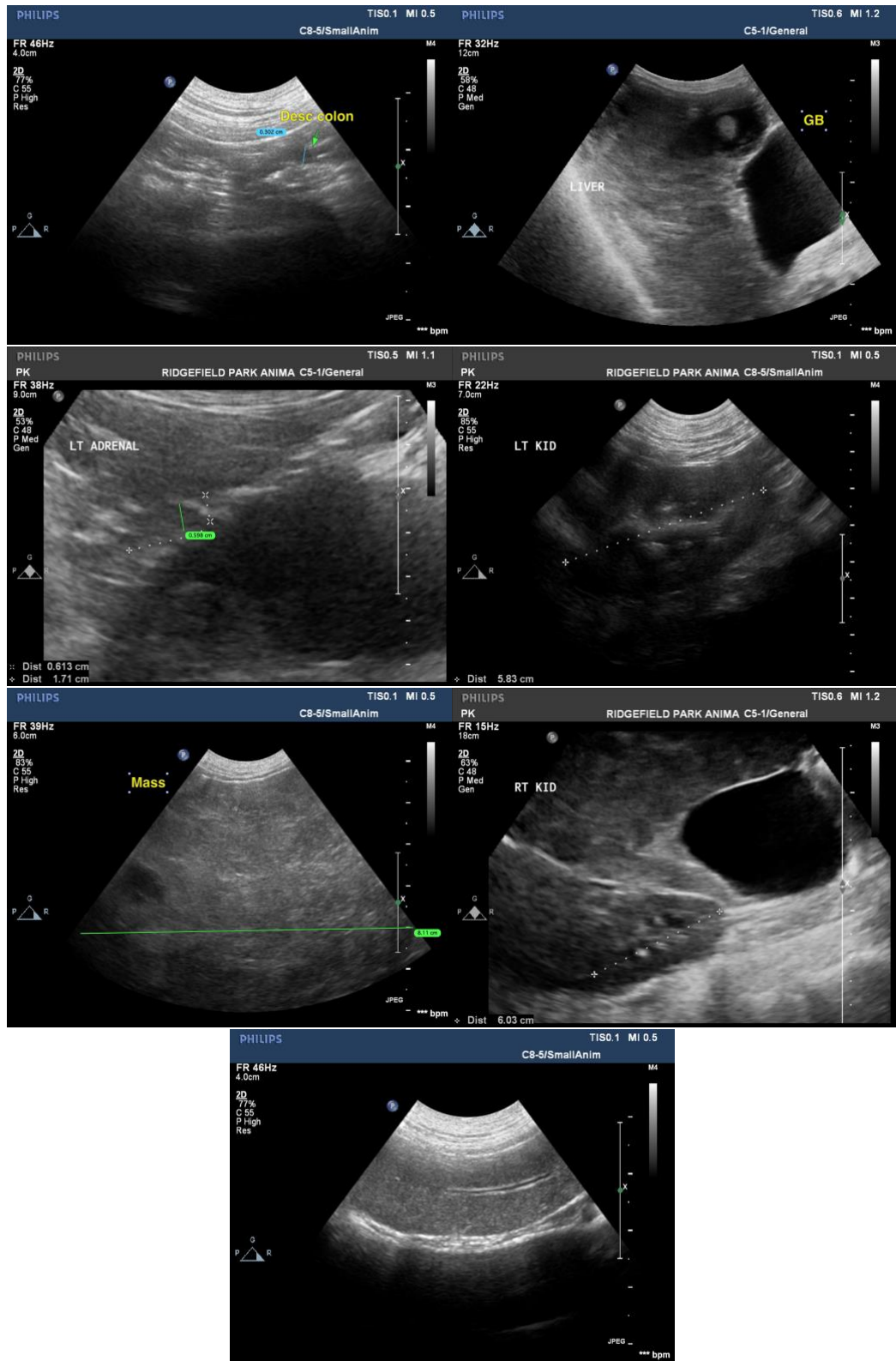
Dr. Paul Kim

**INVOICE**

15583

**DATE**

04/29/26





## PATIENT

Walter Knight

## SPECIES

Canine

## BREED

Chow Chow

## SEX

Neutered Male

## AGE

12

## WEIGHT

58 pounds

## INTERPRETED BY

R. McKenzie Daniel,  
DVM, DABVP (Canine  
/ Feline Practice)

## IMAGING PERFORMED BY

Dr. Paul Kim

## HOSPITAL NAME

Ridgefield Park Animal  
Hospital

## REFERRING VET

Dr. Paul Kim

## INVOICE

15583

## DATE

04/29/26

The information and recommendations provided are based on the images presented by the referring veterinarian/sonographer. No evaluation can be communicated regarding pathology that was not visible in the image/video clips provided.

Thank you for this referral. If the clinical or image interpretation does not parallel your findings or if I can be of any further assistance, please contact me.

R. McKenzie Daniel, DVM, DABVP (Canine / Feline Practice)

[info@SonoPath.com](mailto:info@SonoPath.com)