

**PATIENT**

Meggie Wilcox

**SPECIES**

Canine

**BREED**

Miniature Schnauzer

**SEX**

SF

**AGE**

6 years

**WEIGHT**

31 pounds

**INTERPRETED BY**

R. McKenzie Daniel,  
DVM, DABVP  
(Canine and Feline)

**IMAGING PERFORMED BY**

Sarah Pender CVT

**HOSPITAL NAME**

SVS Imaging QC

**REFERRING VET**

Dr Elliot

**INVOICE**

10487ag

**DATE**

04/29/2022

**PRESENTING CLINICAL SIGNS**

History: Asymptomatic

Abnormal PE/Chem/CBC/UA Results: Increase in grade of heart murmur from 3 to 4, subjectively. Murmur is systolic, bilateral

**ULTRASONOGRAPHIC EXAMINATION OF THE HEART**

CANINE CARDIAC PARAMETERS	MR VMAX (m/s)	TR VMAX (m/s)	LA/AO (Boon method)	LA/AO (Heart Base; Swe)	FS (%)	EF (%)	EPSS (cm)
NORMAL PARAMETER	4.5-5.5	<2.7	1.3	<1.3	28-40	40-100	<0.6
PATIENT		~5	NM	1.5	43.7	76.9	0.27
CANINE CARDIAC PARAMETERS	HR (BPM)	AV VMAX (m/s)	PV MAX (m/s)	BODY WEIGHT (kg)	LA 2D short axis Base view (cm)	LVIDd Avg; 2D and m-mode short axis (cm)	LVIDs Avg; 2D and m-mode short axis (cm)
NORMAL PARAMETER	50-100	0.7-1.7	0.7-1.6				
PATIENT	112	1.5	5.5		2.6	2.6	

**Cardiac Presentation**

The echocardiogram in this patient demonstrated normal left atrial size based on 3 separate methods of LA evaluation. The cranial and caudal mitral valve leaflets presented normal linear structure, extension in systole, and union in diastole with normal kinesis. The left ventricle presented thicknesses with linear contour and was not dilated nor restricted. The myocardium presented normal echogenicity without subjective evidence of significant fibrotic or ischemic disease. Contractility of the ventricular walls was adequate and in normal range for this patient evidenced by the fractional shortening measurement and subjective evaluation of the different regions of the myocardium. The left ventricular outflow tract demonstrated normal laminar flow and subjective structural integrity. The right atrium and auricle revealed potential for subtle increased size with normal overall structure and content. No evidence of masses was noted. Tricuspid valvular assessment demonstrated mild thickening with subjective moderate TR on color Doppler. The right ventricle was of normal size (1/3 diameter of LV) yet exhibited mild hypertrophy of the RV free wall with normal myocardial echogenicity. Turbulent blood flow noted within the RV lumen on color Doppler. Pulmonary outflow tract assessment revealed abnormal to thickened valve structure, turbulent to dynamic systolic flow with subjective overall normal diameter (approx.1:1 pa/ao ratio). Mild PI present on color Doppler measuring approximately 1.2 m/s in diastolic velocity. No visible pericardial or free pleura fluid was noted. The cranial mediastinum and pericardial and extra-cardiac regions were free of masses in the visible window.



**PATIENT**

Meggie Wilcox

**SPECIES**

Canine

**BREED**

Miniature Schnauzer

**SEX**

SF

**AGE**

6 years

**WEIGHT**

31 pounds

**INTERPRETED BY**

R. McKenzie Daniel,  
DVM, DABVP  
(Canine and Feline)

**IMAGING PERFORMED BY**

Sarah Pender CVT

**HOSPITAL NAME**

SVS Imaging QC

**REFERRING VET**

Dr Elliot

**INVOICE**

10487ag

**DATE**

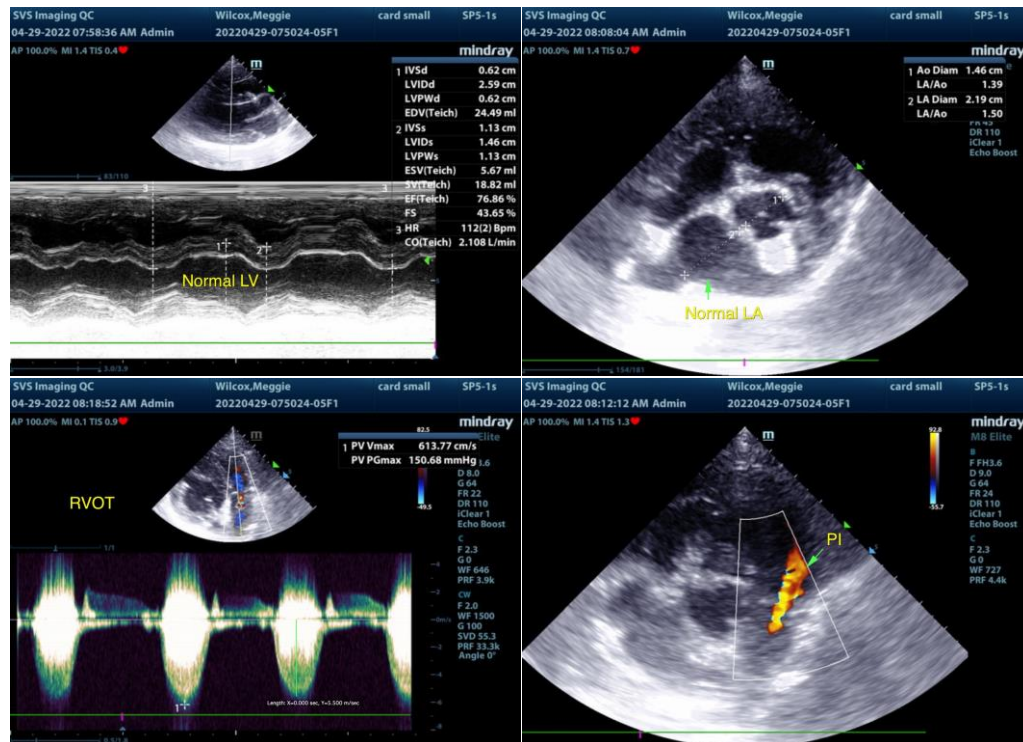
04/29/2022

**ULTRASONOGRAPHIC FINDINGS**

- Pulmonic stenosis
- Thickened TV with TV insufficiency-measured TV velocity suggestive of concurrent pulmonary hypertension yet no evidence of RA enlargement or RHF
- Possible small VSD

**INTERPRETATION OF THE FINDINGS & FURTHER RECOMMENDATIONS**

The primary cause of the murmur is most likely secondary to pulmonic stenosis. The estimated pressure gradient across the pulmonic valve was over 100 mmHg indicating severe pulmonic stenosis. Subjective mild secondary RV hypertrophy was present yet no overt right heart cardiac changes which would indicate right heart failure. Without reported clinical signs, the clinical significance of pulmonic stenosis is unclear. Given the degree of stenosis with potential concurrent complicating factors, referral to a cardiologist is strongly recommended for this patient. If referral is not possible, Atenolol 1 mg/kg PO BID could be considered as this medication may help decrease myocardial oxygen demand and maintain coronary perfusion with mild RV hypertrophy. Close monitoring for evidence of RHF i.e. ascites, exercise intolerance, coughing/syncope is suggested. Exercise restriction is advised in this patient. Serial sonographic monitoring is recommended for further prognosis if referral is not possible.





**PATIENT**

Meggie Wilcox

**SPECIES**

Canine

**BREED**

Miniature Schnauzer

**SEX**

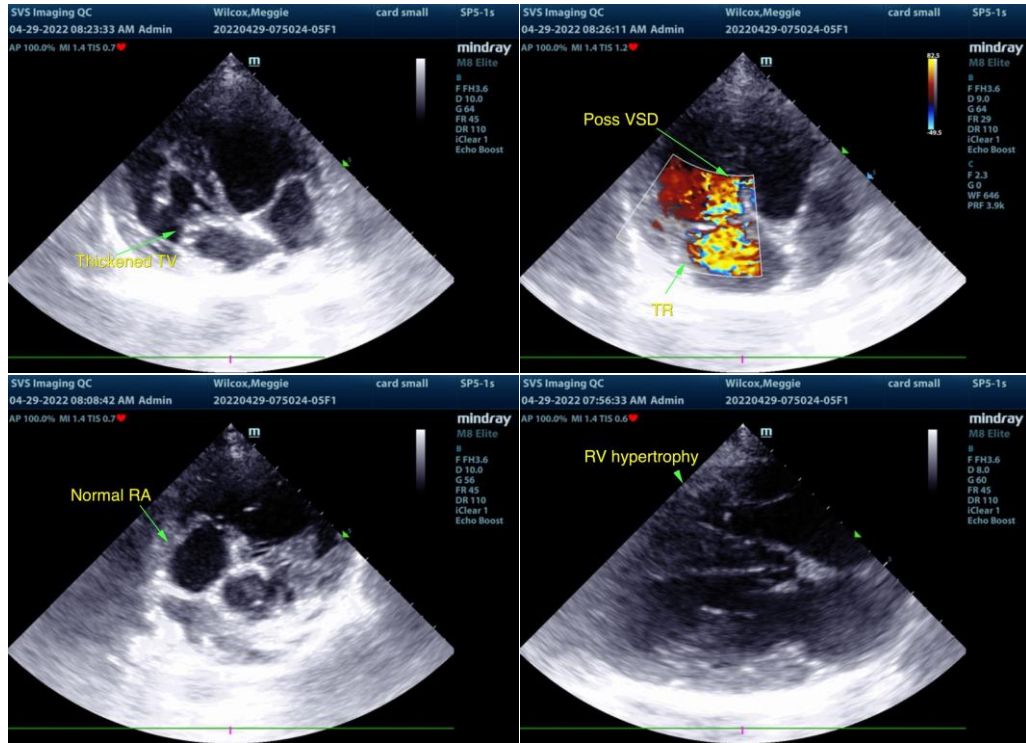
SF

**AGE**

6 years

**WEIGHT**

31 pounds



**INTERPRETED BY**

R. McKenzie Daniel,  
DVM, DABVP  
(Canine and Feline)

**IMAGING PERFORMED BY**

Sarah Pender CVT

**HOSPITAL NAME**

SVS Imaging QC

**REFERRING VET**

Dr Elliot

**INVOICE**

10487ag

**DATE**

04/29/2022

The information and recommendations provided are based on the images presented by the referring veterinarian/sonographer. No evaluation can be communicated regarding pathology that was not visible in the image/video clips provided.

Thank you for this referral. If the clinical or image interpretation does not parallel your findings or if I can be of any further assistance please contact me.

R. McKenzie Daniel, DVM, DABVP (Canine / Feline Practice)

info@SonoPath.com